

## **FEMORAL HEAD FRACTURE ; ANALYSIS OF THIRTEEN CASES AND REVIEW OF LITERATURES**

**Gamal El-Adl MD**

*Department of Orthopaedics and Traumatology,  
Mansoura University Hospital, Egypt*

### **Abstract**

*Background and purpose: Femoral head fracture seems to have become more common especially in younger adults which represent a challenge to preserve normal functioning hip. A retrospective study to review my personal experience in the management of thirteen femoral head fractures with or without hip dislocation over a period of more than six years was carried out.*

*Patients and methods: Twelve patients had attempted one trial of closed reduction of their associated hip dislocation on arrival. According to Yoon et al modification of Pipkin's fracture classification; type I fracture was found in 4 patients (30.8%), type II in 4 patients (30.8%), type III in 3 patients (23.1%) and type IV in 2 patients (15.3%). Thompson and Epstein criteria were used for evaluation of the final radiological and clinical results. The mean time for reduction of associated hip dislocation was 10.4 hours. The mean time for surgical treatment of femoral head fracture was 16.8 hours. The mean time for full weight-bearing was 15.2 weeks.*

*Results: Four patients (30.08%) were reported to have post-operative complications. According to Thompson and Epstein radiological criteria, 5 patients (38.5%) were excellent, 5 patients (38.5%) were good, 2 patients (15.3%) were fair; one patient (7.7%) was poor. The clinical criteria were better than radiological one as it was excellent in 8 patients (61.5%), good in 3 patients (23.1%), fair in one patient (7.7%), and poor in one patient (7.7%). The only statistically significant correlation was found between the Pipkin fracture type and the clinical outcome.*

*Conclusion: Stable fixation of all technically fixable femoral head fragment(s), and excision of smaller non- fixable fragment(s) in Pipkin type I,*

*II, and III through the optimal surgical approach can ensure excellent to good results in most of cases. Early primary joint replacement is an ideal option for Pipkin type IV fracture to avoid relatively poor functional outcome.*

*Key words : Femoral head fractures, open reduction and internal fixation, biodegradable screw and rods, excision.*

### **Introduction**

Femoral head fractures are uncommon injuries and infrequently accompany fracture or fracture-dislocation of the hip (Brumback 1987).

Pipkin (1957) proposed the first and the most commonly used classification system for femoral head fractures. Other authors like; (Brumback et al. 1987, Moehring 1993, Yoon et al. 2001, and Matejka and Pavelka 2002) had modified the original Pipkin classification in order to include all types of femoral head fractures and to guide the treatment and the prognosis.

Fractures of the femoral head by itself represented a complex therapeutic dilemmas for orthopedic surgeon, as no clear guidelines regarding the classification system, line of treatment (operative or conservative), surgical approach

(anterior, posterior, or lateral), surgical technique (excision, fixation, or replacement) and implant material used for fixation (metallic or biodegradable) ( Brumback et al. 1978, Jukkala et al. 1998, Juutilainen et al. 1997, Krempsky and Knybel 2001, Sciontkowski et al. 1992).

The optimal treatment of femoral head fractures remains poorly defined and had been associated with a relatively poor functional outcome either from the injury itself or from its surgical treatment. Closed treatment had been associated with poor clinical results mainly symptomatic post-traumatic arthritis of the hip. Surgical treatment may be beneficial, especially for fractures that involve the weight-bearing area of the femoral head but some complications like; aseptic necrosis, heterotopic ossification, malreduction and malunion, fixation fail-

ure, and post traumatic arthritis might occur (Brumback et al. 1987, Dreinhofer et al. 1996, Henle et al. 2007, Matejka and Pavelka 2002, Moehring 1993, Nast-Kolb et al. 1997, Pipkin 1957, Schonweiss et al. 1999, Yoon et al. 2001).

### **Aim Of The Work**

The aim of this retrospective study was to review my personal short and intermediate-term experience in the management of femoral head fractures regarding the preoperative patient evaluation, indications for treatment, protocol of surgical treatment, post operative care, and finally the radiological and clinical results.

### **Materials and Methods**

Thirteen patients with femoral head fractures were treated and followed up in King Saud Hospital, Unaizah, Al qassim, kingdom of Saudi Arabia over a period of more than six years (from July 2002 to October 2008).

Twelve males and one female with a mean age of 37.5 years (range 23 to 61 years). The mechanism of injury was RTA in eleven

patients and fall and motorcycle accident in two patients respectively. Femoral head fractures were associated with other major injuries in 8 patients (61.5%). The right hip was injured in 7 patients (53.8%) and the left hip in 6 patients (46.2 %).

### **Pre-operative Patient Evaluation :**

All patients were evaluated and resuscitated according to ATLS protocols on their arrival to emergency department together with clinical evaluation of the ipsilateral sciatic nerve function if the patient was conscious. Pelvic anteroposterior radiograph showing both hips together with oblique views of the involved hip were done after resuscitation.

Attempted trial of closed reduction under sedation in emergency department for associated hip dislocation or fracture-dislocation had managed to reduce it in 9 patients (69.2%) which were followed by clinical evaluation of sciatic nerve function if possible. Pelvic computed tomography (CT) scanning starting from lumbo-sacral junction down to pubic symphysis

was done for 9 patients after the successively attempted trial of closed reduction. Three patients with failed closed reduction were taken to CT scanning then shifted to operating theater for another one trial of closed reduction under general anesthesia with all preparations to proceed to open reduction which was the case due to associated femoral neck fracture in one patient, impacted femoral head over the fractured posterior lip of the acetabulum with button-hole of the capsule in the second patient, and comminuted femoral head fracture around a dynamic hip screw applied 18 months back for subtrochanteric femoral fracture in the third patient.

Femoral head fractures were classified according to Yoon et al. (2001) modification of Pipkin's classification (1957). Type I fracture was found in 4 patients (30.8%), type II in 4 patients (30.8%), type III in 3 patients (23.1%) and type IV in 2 patients (15.3%).

Pre-operatively femoral head fragment(s) was found inside the acetabulum in eleven patients and

was extruded outside the socket in two patients. Intra-articular debris were documented pre-operatively by CT scanning in 5 patients (38.5%) and intra-operatively in 7 patients (53.8%). The involved hip was dislocated posteriorly in 11 patients (84.6%), anteriorly in one patient (7.7%), and no dislocation was found in one patient (7.7%) in addition to femoral head fracture.

**Indications For Treatment :**

- Displaced femoral head fracture with failed trial of closed reduction of associated hip dislocation or fracture-dislocation in 3 patients.
- Displaced femoral head fracture with clinically unstable hip after attempted trial of closed reduction due to associated acetabular fracture in 3 patients, and comminuted femoral head fracture in another patient.
- Displaced femoral head fracture with non concentric hip reduction with obstructed passive range of motion due to single large or multiple small intra-articular debris in 3 patients.

- Displaced femoral head fracture associated with incomplete sciatic nerve injury in one patient.
- Displaced femoral head fracture with posterior hip dislocation in one patient.
- Minimally displaced femoral head fracture without hip dislocation in one patient.

**Protocol Of Surgical Treatment :**

There was a policy to treat cases with fracture or fracture-dislocation of the hip in addition to femoral head fracture as early as possible to avoid avascular necrosis unless the patient's general condition did not allow it or in case of late referral.

Pre-operative intravenous prophylactic antibiotic using Cefuroxime 750mg/IV/TID was given and was continued until surgical drains were removed according to their daily output (less than 10ml / 24 hours).

Deep vein thrombosis prophylaxis was used for all patients using Enoxaparin sodium 4000 Units /SC /OD till the time of gait

training non weight-bearing then oral Aspirin 150mg was given from the time of partial weight-bearing till the time of full weight-bearing.

Ordinary operating room table with extension table was used to allow full image access for the pelvis as we do not have radiolucent table.

According to the type of femoral head fracture and the availability of implant; the method of surgical treatment was chosen keeping in mind that all efforts were directed towards reconstruction and fixation of the femoral head fracture if it is technically feasible.

Posterior approach was used in eleven patients (84.6%) and lateral approach was used in one patient (7.7%) due to associated femoral neck fracture. Two femoral head fractures (Pipkin type I) were treated only by skeletal traction as the femoral head fragment was reduced in place following successful attempted trial of closed reduction of associated hip dislocation in one patient and pre-operative acceptable position as

documented with CT scanning in another patient who did not have hip dislocation.

Three femoral head fractures (21.1%) were treated with excision (2 patients with Pipkin type I and one patient with Pipkin type II) of the fragment as it was difficult to fix and it did not affect the stability of the hip. One comminuted (type IV) femoral head fracture (7.7%) was treated with primary bipolar hemiarthroplasty.

Two femoral head fracture Pipkin type II (14.4%) were treated with absorbable rods (Smart Pin R, self-reinforced polylactic acid, ConMed Linvatec Biomaterials Ltd, Finland - Figure 1). One comminuted (Pipkin type IV) femoral head fracture (7.7%) was treated with absorbable screw (Smart screw II<sup>R</sup>, self-reinforced polylactic acid, ConMed Linvatec Biomaterials Ltd, Finland) in addition to biphasic ceramic graft sticks made of calcium hydroxyapatite 65% (HA), and tricalcium phosphate 35% (TCP) (Ceraform<sup>R</sup>, Teknimed, Vic-en-Bigorre, France) to support the 4 parts femoral head fragments around the threaded tip of

the associated DHS fixation for ipsilateral non-united subtrochanteric femoral fracture (Figure 2). Four femoral head fractures (30.8%) were treated with open reduction and internal fixation with metallic screws (three Pipkin type III and one Pipkin type II fractures); one of them had femoral head and neck fracture which were fixed with metallic screws for both fractures through lateral approach (Figure 3). Open reduction and internal fixation of associated acetabular fractures (2 posterior lip and one both column plus posterior lip) were done for three patients with femoral head fractures (21.1%). Incomplete ipsilateral sciatic nerve injury with foot drop was associated with one (Pipkin type II) femoral head fracture together with posterior lip acetabular fracture which was treated by primary nerve repair by neurosurgeon at the time of surgical excision of fractured femoral head fragment in addition to open reduction and internal fixation of associated acetabular fracture (Figure 4).

#### **Post - Operative Care :**

According to the nature of sur-

gical treatment given for femoral head fracture and the associated injuries either of the same hip joint or away from it; the post-operative care was bed rest without traction in 8 patients, skeletal traction in 4 patients for a period between 4-6 weeks. Immediate full-weight bearing was advised for the last patient treated with primary hemiarthroplasty.

Post-operative AP and oblique radiographic views of the involved hip was done for all patients. CT scanning was also done for all cases to access the quality of reduction and fixation except in one patient who had primary bipolar hemiarthroplasty.

No ectopic bone prophyllaxis was used in this study. Continuous passive motion of the hip followed by early active hip and knee range of motion exercises using skate board were started immediately as tolerable when patient general condition had allowed it for all cases without post-operative traction and after traction removal for other cases. Hip flexion was restricted to less than 60 degrees flexion during the first

6 weeks. After 4-6 weeks either with or without prior traction; Protected touch or partial weight-bearing was progressed to full weight -bearing over another 6 weeks or more till full clinical and radiological union achieved except in one patient who had primary bipolar hip replacement where immediate weight -bearing was encouraged. Post-operative clinical and radiological evaluation was done at 6 and 12 weeks intervals for the first year, then every 6 months for the second year then annually thereafter.

**Assessment :**

Thompson and Epstein (1951) criteria were used for evaluation of the radiological and clinical results which were rated independently. If the rating was different the case was assigned to the lower of the two grades.

**Statistical Analysis :**

Although the number of the patients in this retrospective study was limited; both parametric and nonparametric statistical tests were used. Data of all patients summarised in the master sheet (table I) were analysed using

SPPSS software program for windows version eight. Pearson chi-square, one way ANOVA test, and linear-by-linear association were used to define and compare the relation between all in dependable variables and the radiological and clinical results. Statistical significance was set at  $P < 0.05$ .

### **Results**

The mean time for reduction of associated hip dislocation was 10.4 hours. The mean time for surgical treatment of femoral head fracture was 16.8 hours. The mean time for full weight-bearing was 15.2 weeks.

Intra-operatively all cases with femoral head fractures treated either by excision, fixation, replacement, or traction showed stable hip throughout the possible passive range of motion. Post-operatively both plain radiographs and CT scanning for cases treated with fixation revealed concentric hip reduction and acceptable fixation.

There was no implant related errors or complications and all metallic and absorbable screws or

rods were subchondral and intra-osseous in location. There was no residual intra-articular loose debris. All cases with femoral head fracture treated with fixation had showed uneventful fracture union without fixation failure. Four patients (30.08%) were found to have post-operative complications. One patient with type IV femoral head fracture around DHS which was used for treatment of comminuted subtrochanteric femoral fracture 18 months back, his femoral head fracture was treated with multiple absorbable screws plus Ceraform<sup>R</sup> sticks as bone graft substitute as there was no facility for THR and the patient was not eligible for higher centre referral as he cannot pay the charges for this service being non insured, and at the same time bipolar hemiarthroplasty was not possible due to his pre-existing non united subtrochanteric femoral fracture. This patient developed posterior hip subluxation, osteoarthritic changes in spite of bone healing with pain, limping, and decreased hip range of motion that had been treated with THR after 3 years when he had returned back to the Republic of Sudan.



Heterotopic ossification was reported in two patients (one Brooker grade I and the other was grade II). One of them had persistent weak right foot dorsiflexion following incompletely recovered sciatic nerve palsy presented with the femoral head fracture on admission.

One patient had segmental a vascular necrosis of the involved femoral head, and incomplete lateral popliteal nerve palsy following open reduction and internal fixation of his femoral head and acetabular fractures that was recovered completely during the follow up period.

According to Thompson and Epstien (1951) radiological criteria, 5 patients (38.5%) were excellent, 5 patients (38.5%) were good, 2 patients (15.3%) were fair; one patient (7.7%) was poor. The clinical criteria were better than radiological one as it was excellent in 8 patients (61.5%), good in 3 patients (23.1%), fair in one patient (7.7%), and poor in one patient (7.7%).

There was no statistically significant relationship between the

age of the patient, time of reduction of associated hip dislocation, time of femoral head fixation or excision or replacement, time of full weight-bearing, and all the radiological or the clinical results using one-way ANOVA Test.

There was no statistically significant correlation between the radiological results and the sex of the patients (chi-square 0,360), side affected (chi-square 0,722), mechanism of injury (chi-square 0,706), nature of the lesion (chi-square 0,414), type of dislocation (chi-square 0,769), type of reduction (chi-square 0,449), surgical approach used (chi-square 0,748), type of implant used (chi-square 0,054). Although there was no statistically significant correlation between Pipkin fracture type and the radiological results (chi-square=0,311); but it was clear that patients with type I fracture were excellent (50%) and good (50%) in contrast to type IV fracture which were good (50%) and poor (50%).

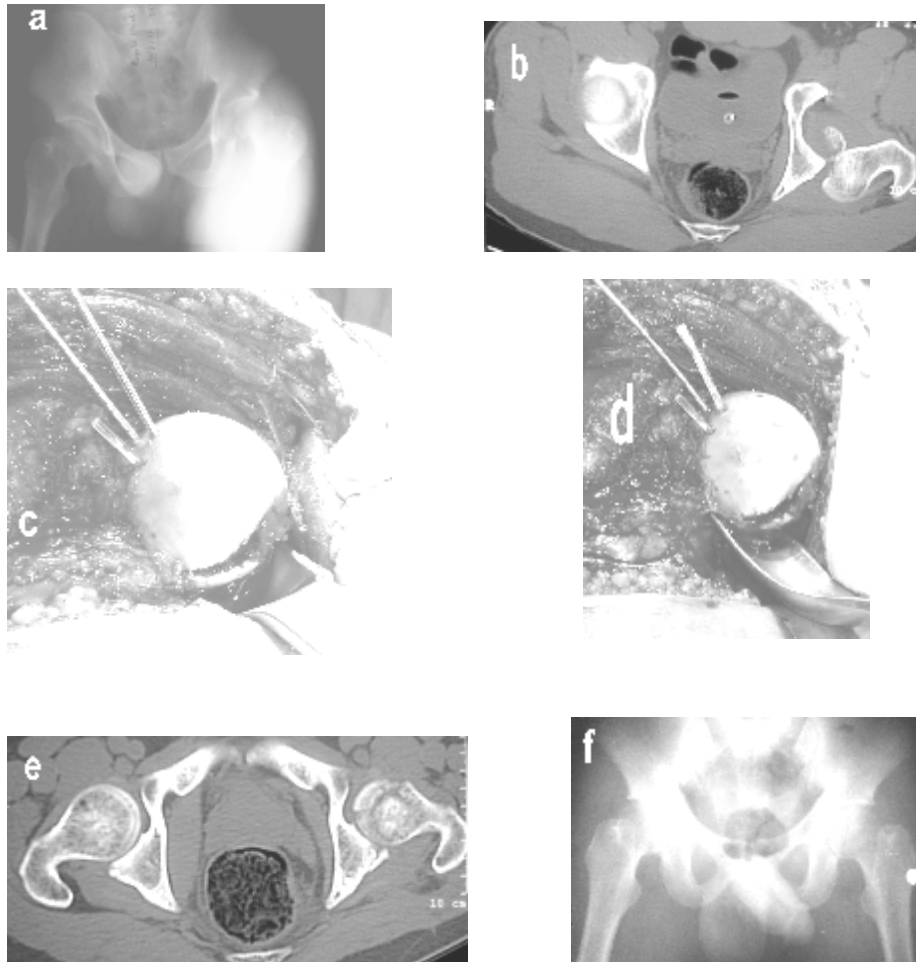
There was no statistically significant correlation between the clinical results and the age of the patients (chi-square 0,879), side

affected (chi-square 0,518). Mechanism injury (chi-square 0,961), nature of the lesion (chi-square 0,208), Type of dislocation (chi-square 0,961), type of reduction (chi-square 0,492), treatment given (chi-square 0, 715), surgical approach used (chi-square 0,955), and implant used (chi-square 0,075). The only statistically significant correlation was found between the Pipkin fracture type and the clinical outcome using linear-by-linear association ( $P = 0,012$ ). The same relation was not significant using chi-square test.

**Table (I) : the master sheet data for all patients included in this study.**

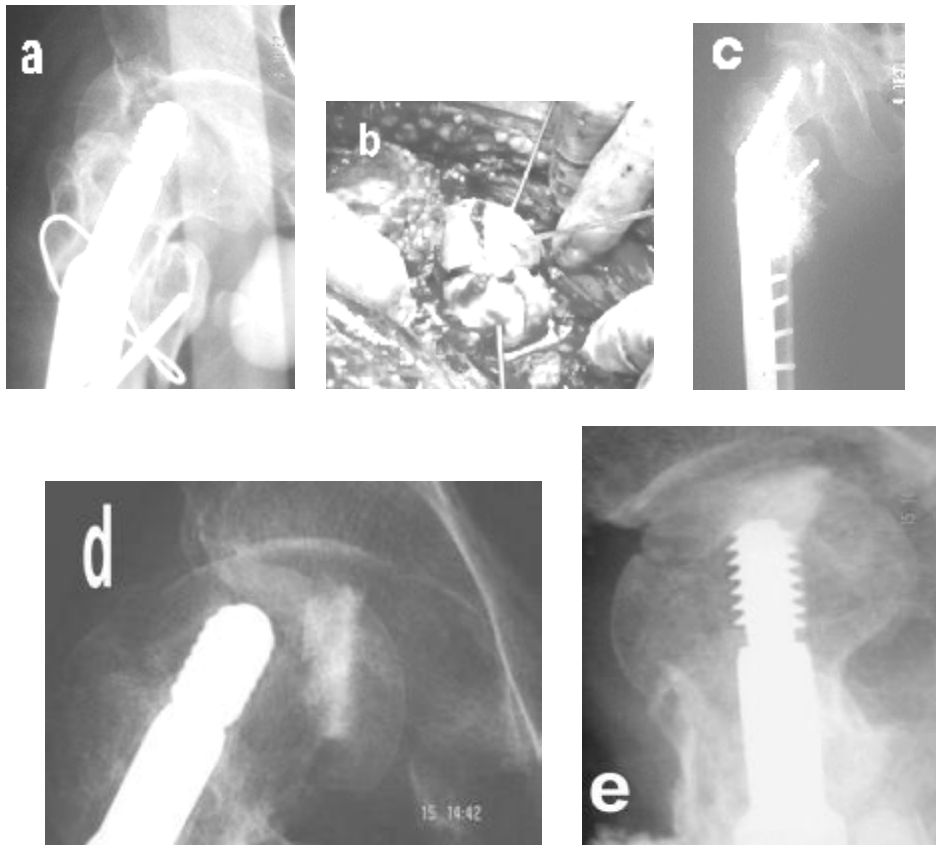
NO.	Age	Sex	Mechanism of Injury	Nature of Injury	Pipkin # type	Side	Type of dislocation	Type of Reduction	Time of Reduction (hour)	TREATMENT
1.	38	Male	RTA	Isolated	IV	Right	Posterior	Open	34	- Head → ORIF + Ceraform - Non United subtorch # → Ceraform
2.	41	Male	RTA	Associated # neck of femur Lt	III	Left	Posterior	Open	6	- Head → ORIF - Neck → ORIF Can Screws
3.	23	Male	RTA	Isolated	II	Left	Posterior	Open	4	Head → ORIF
4.	40	Male	RTA	Isolated	I	Right	-	-	-	Traction
5.	33	Female	RTA	Isolated	I	Right	Posterior	Closed	2	Traction
6.	61	Male	Motorcycle	Associated gll torne MCL Rt Knee	II	Right	Posterior	Closed	12	- Head → ORIF - Knee → POP cast
7.	34	Male	Fall	Associated #L5 stable wedge	I	Left	Posterior	Closed	24	- Head → excision - LS → brace
8.	50	Male	RTA	Associated # Left Humerus	IV	Right	Posterior	Closed	8	- Head → bipolar prosthesis - Humerus → ORIF
9.	29	Male	RTA	Associated #acetabulum	III	Left	Posterior	Closed	3	- Head → ORIF - Acetabulum → ORIF
10	45	Male	RTA	Associated LPN injury Rt foot & # acetabulum	II	Right	Posterior	Closed	2	- Head → excision - Acetabulum → ORIF
11	30	Male	RTA	Isolated	II	Right	Posterior	Closed	3	Head → ORIF
12	26	Male	RTA	Associated Subdural Hematoma, #6 <sup>th</sup> rib #Right tibia	I	Left	Posterior	Closed	36	- Head → Excision, Subdu > Evacuation - Rib → cons - Tibia → nail
13	38	Male	RTA	Associated # acetabulum	III	Left	Posterior	Closed	1	- Head → ORIF Acetabulum → ORIF-

NO.	Time of treatment (hour)	Surgical approach	Implant Used	Time of full W.B (weeks)	Follow up Period (months)	Complication	Radiological Results	Clinical Results
1.	34	Posterior	Absorbable screws +Ceraform graft	22	27	- Posterior hip subluxation , O.A Rt hip, disabling pain	Poor	Poor
2.	6	Lateral	Metallic screws	21	53	-	Good	Excellent
3.	4	Posterior	Absorbable rods	14	25	-	Excellent	Excellent
4.	2	-	-	12	36	-	Excellent	Excellent
5.	3	-	-	16	40	-	Good	Excellent
6.	36	Posterior	Absorbable rods	13	31	-	Excellent	Excellent
7.	48	Posterior	-	18	19	-	Excellent	Excellent
8.	-	Posterior	Bipolar Prosthesis	1	4	-	Excellent	Good
9.	24	Posterior	Metallic screws	19	35	-	Good	Good
10.	3	Posterior	-	15	18	- Weak dorsiflexion Rt foot, - limping, heterotopic ossification (Brooker II)	Fair	Good
11.	6	Posterior	Metallic screws	14	33	-	Good	Excellent
12.	36	Posterior	-	12	30	Heterotopic ossification (Brooker I)	Good	Excellent
13.	16	Posterior	Metallic screws	20	23	- Segmental a vascular neurosis → pain → limping - Recovered Partial sciatic nerve injury	Fair	Fair

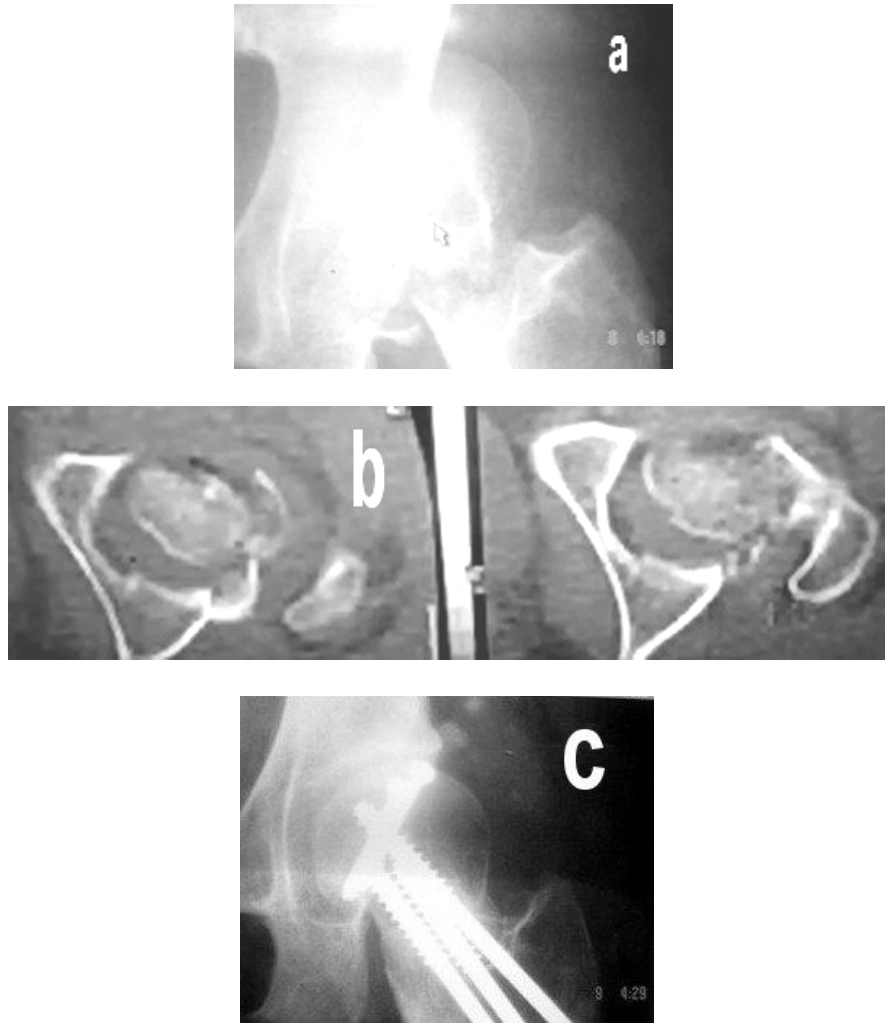


**Figure ( 1 ) :** ( a ) -Pre-operative AP radiograph showing fracture-dislocation Lt hip with femoral head fracture.  
( b ) -Pre-operative CT scanogram showing femoral head fracture associating fracture-dislocation of the hip.  
( c , d ) -Intra-operative photograph showing temporary K.wire fixation of femoral head fracture then replacement with absorbable Smart II pin.  
( e ) -Post-operative CT scanogram showing the reduced and fixed femoral head fracture.  
( f ) -follow up AP radiograph showing the healed femoral head fracture.

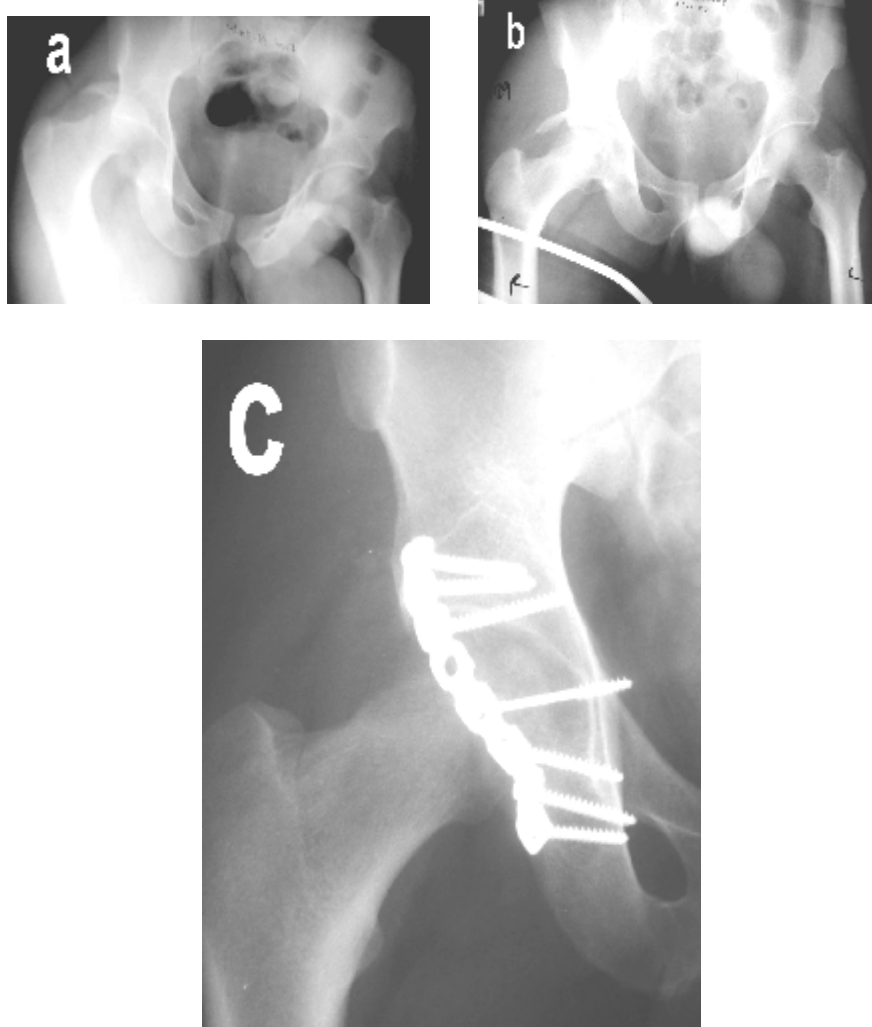
---



**Figure ( 2 )** ( a ) -pre-operative AP radiograph of the Rt hip showing comminuted femoral head fracture around the tip of DHS screw used for old subtrochantric femoral fracture which was non united after 18 months.  
( b ) -intra-operative photograph showing temporary K. wire fixation of the 4 parts femoral head fracture which was replaced with absorbable Smart II screws.  
( c ) -post-operative follow up AP radiograph showing the the reduced and internally fixed femoral head fracture together with few sticks of synthetic bone graft (Ceraform<sup>R</sup>) for structural support.  
( d , e ) -post-operative follow up AP and lateral radiographs of the healed femoral head fracture with early osteoarthritis and posterior subluxation of the Rt hip.



**Figure ( 3 ) :** ( a ) -pre-operative AP radiograph of the LT hip showing posterior fracture-dislocation with comminuted acetabular and femoral head fracture.  
( b ) -pre-operative CT scanogram showing comminuted fracture of the femoral head and neck after one trial of closed reduction.  
( c ) - post-operative follow up AP radiograph showing healed femoral head and neck fractures fixed with metallic screws.



**Figure ( 4 ) :** ( a ) -pre-operative AP radiograph of the pelvis showing posterior fracture-dislocation of the Rt hip with acetabular and femoral head fracture.  
( b ) -post-reduction AP radiograph of the pelvis showing reduction of dislocated Rt hip.  
( c ) -follow up post-operative radiograph showing healed acetabular fracture after ORIF with plate and screws and excision of associated femoral head fracture.

### **Discussion**

Femoral head fracture was previously described as uncommon injury associating dislocation or fracture-dislocation of the hip in a rate of 10 % in Epstein et al. (1985) report.

Recently with the increase of high energy trauma; femoral head fracture seems to have become more common especially in younger adults which represent a challenge to preserve normal functioning hip as arthroplasty may not be the best option for this young and active age group especially in underdeveloped countries. In this study the mean age was 37.5 years which is coincident with many other reports (Epstein et al. 1985, Lutonsky et al. 1993, Marchetti et al. 1996, Matejka and Pavelka 2002, Schonweiss et al. 1999).

The indications for open reduction and internal fixation of femoral head fractures remains controversial. Accurate reduction of suprafoveal femoral head fractures is necessary to help restoring the normal peripheral loading characteristics and to decrease

the peak articular cartilage stress in the hip. The implemented concept in the management of patients with femoral head fractures included in this study was directed towards fixation of all technically fixable fractures whether it is suprafoveal or infrafoveal especially when the absorbable implants (Rods or screws) became available.

Pre-operative CT scanning before and/or after reduction of associated hip dislocation was essential to define the treatment plan. In this study traction was decided in one patient with femoral head fracture without dislocation as his CT scanning showed near anatomical reduction. Mostafa (2001), Werken and Blankensteijn (1987), Mody and Wainwright (1996), and El Mrini et al. (2006) had reported similar cases with femoral head fracture without dislocation of the hip.

Posterior approach was used in this study in 11 patients including this patient treated with primary hemiarthroplasty without too much difficulty in 9 patients. Two patients showed intra-operative



difficulty to visualize the fracture surface, to reduce and to fix the displaced suprafoveal anterolateral femoral head fracture. This observation was similar to Butler (1981) as flexion, adduction, internal rotation of the hip needed to dislocate the hip hide the fracture site from the view.

Many authors like El Mrini et al. (2006), Epstein et al. (1985), Hougaard and Thomsen (1988), Schonweiss et al. (1999), Werken and Blankensteijn (1987); had recommended posterior approach for fixation of femoral head fractures whereas others had advocated anterior approach for reduction and fixation or excision of femoral head fragment as it identifies the antero-medial femoral head fracture, allows easy access to the acetabulum for removal of loose osteochondral debris, and allows accurate reduction and fixation of the fracture. The main disadvantages of the anterior approach were high incidence of heterotopic ossification and a vascular necrosis of the femoral head (Bauer and Sarkar 1997, Thompson and Epstein 1981, Treacy and Grigoris 1992).

Some other authors had advocated lateral approach with or without trochantric osteotomy for treatment of femoral head fracture (Ganz et al. 2001, Henle et al. 2007, Kloen et al. 2002, Krempasky and Knybel 2001). Mostafa (2001) had treated six patients with femoral head fracture and reported that lateral Watson - Jones approach was satisfactory to reduce and fix these difficult fractures. Lateral approach was used to treat one patient included in this study with Pipkin type III femoral head fracture associated with femoral neck fracture without intra-operative difficulty or post-operative complication.

Mowery and Gershuni (1986) had recommended posterior approach for posterior hip dislocation and anterior approach for anterior hip dislocation; so as not to further damage the joint capsule and the remaining blood supply. Schonweiss et al. (1999) had recommended anterolateral (Smith-Peterson), and lateral (Watson-Jones) approaches for Pipkin type I, II, and III fractures, and posterior (Kocher-langenbeck) approach for Pipkin type IV fractures.

Epstein (1961) had reported many unsatisfactory results in cases treated with excision of the femoral head fragment especially if it was more than one third of the femoral head. In this study three patients were treated with excision of the femoral head fragment without causing intra-operative hip instability or post-operative, post-traumatic osteoarthritic changes during the follow up period. All these patients were treated early in this study where the absorbable rods and screws were not available.

Few fixation options were available for femoral head fracture because of the fragment size and location. The implant should be located beneath the articular surface yet it should provide sufficient fixation to prevent early failure. The implant used for femoral head fragment fixation in the study were either; metallic screws (2mm, 4mm, 6.5mm) or absorbable rods (1.5mm, 2mm, 3.2mm) and screws (2mm, 3.5mm, 4.5mm) according to the fragment size, location and the availability of implant.

Biodegradable implants (rods or screws) offered marked advantages in fixation of femoral head fracture as a very small fragment can be fixed even through articular cartilage surface, and there is no need for implant removal later on. Also its mechanical properties are comparable to metallic screws with high rate of union and increased bone mass density around it (Hermus et al. 2005, Prokop et al. 2005).

Juutilainen et al. (1997) had reported an average increase of bone density about 18.3% after Self-reinforced polyglycolic acid (rods-screws), and an average decrease of 6.4% after self-reinforced polylactic acid (rods-screws) in contrast to an average decrease of 18.6% after metallic implants.

Jukkala et al. (1998) had reported about their experience in treatment of six patients with femoral head fracture with self-reinforced polyglycolic and polylactic rods and screws and concluded that it is safe to be used without the need to remove it.

The role of internal fixation ver-

sus hemiarthroplasty or total hip replacement as a primary treatment for Pipkin Type III femoral head fractures had not been settled. Most of authors recommended primary open reduction, and internal fixation to restore the normal anatomy as most of the patients were young active adults (Burman and Feldman 1959, Epstein 1961, Fina and Kelly 1970, Mostafa 2001). On the contrary other authors like Kelly and Lipscomb (1958), Mehara et al. (1995), and Fernandez (1980) had recommended primary hip replacement to reduce hospitalization period and to provide better hip function with less subsequent disability.

Fracture-dislocation of the hip was reported to have frequent complications like; a vascular necrosis of the femoral head (0-24%), degenerative post-traumatic arthritis (0-72%), nerve injuries (7-27%), and heterotopic ossification (2-54%) (Kloen et al. 2002).

It was believed that posterior approach might increase the above risks especially a vascular necrosis which was not the case

in this study as it was reported only in one patient and it was localized and segmental and it did not affect the functional clinical outcome. This observation was also reported by Hougaard and Thomsen (1988), Treacy and Grigoris (1992), and El Mrini et al. (2006), and their conclusion was that posterior approach leads to exposition for internal fixation without the high risk of a vascular necrosis.

Although heterotopic ossification prophylaxis was not used in this study; it was clear from this study that the risk was 15.4% but it did not affect the range of motion and the final clinical outcome. Schonweiss et al. (1999) had recommended routine use of indomethacin as an ossification prophylaxis due to high tissue damage.

The final clinical outcome (85.0% excellent and good) was better than the final radiological outcome (77.0% excellent and good) as the two patients with heterotopic ossification and the third patient with segmental a vascular necrosis were able to go back to

their pre-injury occupation without too much disability, pain, or limping. Krempasky and Knybel (2001) reported 80% good results, Marchetti et al. (1996) reported 67% good results, and Henle et al. (2007) reported 83.3% excellent and good results.

Marchetti et al. (1996) found a significant relationship between Pipkin fracture type and the final outcome as type I and II had better results than type III and IV, and they had found a non significant relationship between the time of reduction of hip dislocation, time of femoral head fracture fixation, the type of surgical exposure and the final outcome. This study reached to a similar relationship and the only significant relationship was between Pipkin fracture type and the final clinical outcome.

This study supports the concept of restoring the anatomy of the femoral head as early as possible to achieve satisfactory initial results and to facilitate later reconstructive procedures if needed especially for Pipkin type I, II, and III. For Pipkin type IV fracture; hip

replacement seems to be a sound option to avoid serious clinical disability.

According to the results of this study; the controversy regarding the following three items; what to do (fixation, excision, or replacement), how to approach the fracture (anterior, posterior, or lateral), which implant material to be used (metallic, or biodegradable rods and screws) still not finally cleared to give hard rules as the number of patients is very limited. It seems that any femoral head fracture that is technically fixable it should be fixed with metallic or better biodegradable implant if available through the posterior approach unless it is associated with femoral neck fracture for which lateral approach is preferred.

### **Conclusion**

All Pipkin femoral head fractures should be treated operatively unless anatomically reduced. Early-timed reduction of associated hip dislocation, early-timed accurate reduction and stable fixation of all technically fixable femoral head fragments, and excision of smaller non- fixa-

ble fragments in Pipkin type I, II, and III through the optimal surgical approach can ensure excellent to good results in most of cases. Early primary joint replacement is an ideal option for Pipkin type IV fracture to avoid relatively poor functional outcome.

### References

**Bauer G. J. and Sarkar M. R. (1997)** : Injury classification and surgical approach in hip dislocations and fractures. *Orthopade*,26 (4): 304-16.

**Brumback R. J., Kenzora J. E., Levitt L. E., Burgess A. R. and Poka A. (1987)** : Fractures of the femoral head. *Proceeding of hip society editor 1986*. CV Mosby. St Louis,27 (6), 181-206.

**Burman M. and Feldman T. (1959)** : Fractures of the head of the femur with dislocation of hip. *Hosp Joint Dis*, 20:69-71.

**Butler J. E. (1981)** : Pipkin type-II fractures of the femoral head. *J Bone Joint Surg*,63-A: 8,1292-1296.

**Dreinhofer K. E., Schwarz-**

**kopf S. R., Hass N. P. and Tscherne H. (1996)** : Femoral head fracture dislocation, long-term outcome of conservative and surgical therapy. *Unfallchirurg*,99 (6): 400-9.

**El Mrini A., Daoudi A., Agoumi O., Boutayeb F., Mahfoud M. and Elbardouni A. (2006)** : Isolated fracture of the femoral head. *J Orthop.Org*,3: 3 e 17.

**Epstein H. (1961)** : Posterior fracture dislocation of the hip: Comparison of open and closed methods of treatment in certain types. *J Bone Joint Surg*,43 (A): 1079-1098.

**Epstein H., Wiss D. and Cozen L. (1985)** : Posterior Fracture dislocation of the hip with fractures of the femoral head. *Clin Orthop*, 201; 9-17.

**Fernandez A. (1980)** : Traumatic posterior dislocation of hip joint with a fracture of the head and neck of the femur on the same side. A case report. *Injury*,12:487-490.

**Fina C. and Kelly P. (1970)** :

Dislocation of the hip with fractures of the proximal femur. *J Trauma*, 10: 77-80.

**Ganz R., Gill T. J., Gautier E., Ganz K., Krugel N. and Berie-mann U. (2001)** : Surgical dislocation of the adult hip a technique with full access to the femoral head and acetabulum without the risk of a vascular necrosis. *J Bone Joint Surg*, 83(B), 8: 1119-24.

**Henle P., Kloen P. and Sienbenrock K. A. (2007)** : Femoral head injuries: which treatment strategy can be recommended? *Injury*, 38(4): 478-88.

**Hermus J. P., Laan C. A., Horgervorvorst M. and Rhemrev J. S. (2005)** : Fixation of Pipkin Fracture with bioabsorbable screws; case report and review of literature. *Injury*, 36: 458-461.

**Hougaard K. and Thomsen P. (1988)** : Traumatic posterior fracture dislocation of the hip with fracture of the femoral head or neck or both. *J Bone Joint Surg*, 70 (A): 233-239.

**Jukkala-Partio K., Partio E.**

**K., Hirvensalo E. and Rokkanen P. (1998)** : Absorbable fixation of femoral head fractures. A prospective study of six cases. *Ann Chir gynaecol*, 87 (1): 44-8.

**Juutilainen T., Hirvensalo E., Majola A., Partio E. K., Patiala H., Rokkanen P. and Kinnunen J. (1997)** : Bone mineral density in fractures treated with absorbable or metallic implants. *Ann chir gynaecol*, 86(1): 51-5.

**Kelly P. J., lipscomb R. R. (1958)** : Primary vitallium-mold arthroplasty for posterior dislocation of the hip with Fracture of the femoral head. *J Bone Joint Surg*, 40 (A): 675-680.

**Kloen P., Sienbenrock K. A., Raymarkers E., Marti R. and Ganz R. (2002)** : Femoral head fractures revisited. *Eur J Trauma*, 28: 221-33.

**Krempasky O. and Knybel T. (2001)** : The Pipkin Fracture. *Acta chair orthop traumatol cech*, 68 (5): 304-10.

**Lutonsky M., Dlask J. and Brtkova J. (1993)** : Personal ex-

perience with treatment of Pipkin Fractures of the femoral head. Acta Chir Orthop Traumatol Cech,60 (2); 107-10.

**Marchetti M. E., Steinberg G. G. and Coumas J. M. (1996) :** Intermediate - term experience of Pipkin Fracture dislocations of the Hip. J Orthop Trauma,10(7): 455-461.

**Matejka J. and Pavelka T. (2002) :** Fractures of the femoral head. Acta chir Orthop Traumatol cech, 69 (4): 219-28.

**Mehara A., Ramchandani G., Shorma C. and Gupta R. (1995) :** Unusual posterior hip dislocation with ipsilateral fractures of the femoral head and neck. J Trauma, 38: 658-659.

**Mody B. and Wainwright A. (1996) :** Fracture of the femoral head without associated hip dislocation following low energy trauma. A report of two cases. Arch Orthop Trauma Surg, 115 : 300-302.

**Moehring H. D. (1993) :** Hip dislocation and femoral head frac-

tures in: operative orthopaedics, second edition (Ed. Michael w Chapman). JB Lippincott Company. Philadelphia, 571-82.

**Mostafa M. M. (2001) :** Femoral head fractures. International orthopaedics (SICOT), 25: 51-54.

**Mowery C. and Gershuni D. (1986) :** Fracture dislocation of the femoral head treated by open reduction and internal fixation. J Trauma,26: 1041-1044.

**Nast-Kolb D., Ruchholtz S. and Schweiberer L. (1997) :** Treatment of pipkin fractures. Orthopade, 26(4): 360-7.

**Pipkin G. (1957) :** Treatment of grade IV fracture dislocation of the hip. A review. J Bone Joint Surg, 39(A): 1027-1024.

**Prokop A., Helling H. J., Hahn U., Udomkaewknjana C. and Rehm K. E. (2005) :** Biodegradable implants for Pipkin fractures. Clin Orthop Relat Res, 432: 226-33.

**Roeder L. and De lee J. (1980) :** Femoral head Fractures

associated with posterior hip dislocations, Clin orthop, 147: 121-130.

**Schonweiss T., Wagner S., Mayr E. and Ruter A. (1999) :** Late results after fracture of the femoral head. Unfallchirurg, 102 (10): 776-83.

**Sciontkowski M. F., Thorpe M., Seiler J. C. and Hansen S. T. (1992) :** Operative management of displaced femoral head fractures: Case matched comparison of anterior versus posterior approach for Pipkin I and Pipkin II fractures. J Orthop Trauma, 6 (4): 437-42.

**Thompson V. and Epstein H. (1951) :** Traumatic dislocation of the hip. J Bone Joint Surg, 33 (A):746-778.

**Timothy B. R., Sean E. N. and**

**Milton L. C. R. (2001) :** Surgical treatment of femoral head fractures. Orthopaedic Trauma Association proceeding; Orthopaedic Trauma, Session X (pelvis, Geriatrics) paper # 58.

**Treacy R. and Grigoris P. (1992) :** Bilateral Pipkin type I fractures. Injury, 23 : 415 - 416.

**Werken C. and Blankensteijn J. (1987) :** Fracture of the femoral head without dislocation; A case report. Acta Orthop Scand, 58: 173-174.

**Yoon T. R., Sung M. R., Jae Y. C., Eun K. S., Sung T. J. and Iwan B. A. (2001) :** Clinical and radiographic outcome of femoral head fractures. 30 patients followed for 3-10 years. Acta Orthop Scand ,72 (4): 348-353.



REPRINT

# **BENHA MEDICAL JOURNAL**

**FEMORAL HEAD FRACTURE ;  
ANALYSIS OF THIRTEEN CASES  
AND REVIEW OF LITERATURES**

**Gamal El-Adl MD**

**Published by  
Benha Faculty of Medicine**

*Volume 26 Number 3  
Sept. 2009*

## **PRONATOR QUADRATUS MUSCLE PEDICLE BONE GRAFT IN NON-UNITED SCAPHOID FRACTURES**

**Gamal El-Adl MD**

*Department of Orthopedics and Traumatology,  
Mansoura University Hospital, Egypt*

### **Abstract**

**Background and purpose:** *symptomatic non-union of the scaphoid should be treated surgically to improve the wrist and hand function and the current practice is to treat non union by increasing the vascularity of bone. A prospective study to evaluate the results of surgical treatment of nonunited scaphoid fractures with the technique of pronator quadratus muscle pedicle bone graft in eleven patients was carried out.*

**Patients and methods:** *Eleven patients with non united scaphoid fractures more than 6 months treated by pronator quadratus muscle pedicle bone graft and Kirshner wire fixation were evaluated clinically ( range of motion, grip strength), radiologically (scaphoid length and A.P scaphoid angle in antero- posterior views, and scapho-lunate angle, and lateral intra-scaphoid angle in lateral view, and functionally (modified scaphoid outcome score).*

**Results:** *The average follow up period was 29.3 months, with nonunion over an average period of 27 months. Scaphoid non union through the waist and type D3 fracture were the commonest types. The difference in the range of motion, and grip strength of the normal and affected wrist pre-operatively and the affected wrist preoperatively and postoperatively was found to be statistically significant. The average period for radiological union of non united scaphoid fracture was 12.7 weeks with a range between 8 weeks to 17 weeks. The difference in the radiological measurements of the normal and the affected wrist preoperatively, and the affected wrist preoperatively and postoperatively was found to be statistically significant. According to scaphoid outcome scoring satisfactory results were reported in 90.9% of cases with 54.5% excellent and 36.4 %*

good results. Unsatisfactory fair results were reported in one patient (9.1%).

**Conclusion:** *Pronator quadratus pedicle bone graft is a simple and effective procedure without the need of special equipment and special surgical skills, and was associated with some complications which was genuine and did not affect the final outcome. The principal benefits of this technique were relief of pain together with an increase in wrist range of motion and the hand grip strength.*

**Keywords;** *Pronator quadratus, muscle pedicle bone graft, non-united scaphoid fractures.*

### **Introduction**

Displaced and unstable scaphoid fractures pose a particular surgical problem with 55% incidence of non-union and a 50% rate of a vascular necrosis (Dabenzies et al 1992, Amadio 1982). There is a general agreement that a symptomatic non-union of the scaphoid should be treated surgically to improve the wrist and hand function (Cooney et al 1980).

Open reduction and internal fixation together with non vascularized or vascularized bone grafting techniques are the most popular surgical procedures for scaphoid non union persistent more than 6 months after conservative treatment (Cooney et al 1980, Cooney et al 1996, Herbert and Fisher 1984, Smith et al

1991, Green 1985). Viability and stability of the scaphoid fragments are essential for obtaining union and the current practice is to treat a vascular necrosis by increasing the vascularity of bone. Obtaining union is not sufficient criterion of success in treatment of scaphoid non union especially if the flexion or humpback deformity was not corrected (Markus et al 1999).

Kawai and Yamamoto (1988) had reported a rate of 100% bony union after using a modification of the pronator quadratus pedicle bone graft technique without any complication and without the need of special equipment (Kawai and Yamamoto 1988).

### **Aim of the Work**

The aim of this prospective

study is to evaluate the results of surgical treatment of nonunited scaphoid fractures with the technique of pronator quadratus muscle pedicle bone graft in eleven patients.

### **Patients and Methods**

Eleven patients with non united scaphoid fractures treated by pronator quadratus muscle pedicle bone graft and Kirshner wire fixation between the period from November 2002 to November 2007 at King Saud Hospital, Un-aizah, Al-qseem, Saudi Arabia represented the material of this study. The criteria for patient selection were established symptomatic non union for more than 6 months, age above eighteen years. The main clinical inclusion criteria for surgical interference were wrist pain, and / or weak hand grip, and /or wrist stiffness.

The radiographic inclusion criteria for surgical interference were, stable and undisplaced non united fracture, displaced non united fracture, unstable non united fracture with collapse and flexion (hump-back) deformity, non united scaphoid fracture with

mild to moderate radiocarpal arthritis, and non united scaphoid fracture with a vascular necrosis of the proximal fragment. The exclusion criteria for surgical interference were, a symptomatic non union, non united scaphoid fracture with advanced radiocarpal arthritis and if the proximal fragment was too small, fragmented or badly deformed and a vascular.

A detailed medical history for every patient regarding the age, sex, laterality and dominance, occupation, mechanism of injury, time from injury, adequacy of previous treatment according to the criteria of Radford et al (1990), type of the fracture using Filan and Herbert classification (1996), site of non union, complaint, date of surgical interference, time to union, length of follow up period and any complications. The clinical and demographic data for the eleven patients included in this study are summarized in (Table I).

Clinical assessment of wrist function included the wrist range of motion and the hand grip strength. The range of motion of the affected and unaffected wrist

was measured preoperatively including; palmer flexion, dorsal flexion, radial deviation, and ulnar deviation using the method advised by Kauer (1980). The average standard palmer flexion was 80 degrees, dorsal flexion was 70 degrees, radial deviation was 20 degrees, and ulnar deviation was 35 degrees. The hand grip strength was measured using the method of Mc Rae (1987) for both the affected and unaffected wrist preoperatively. The standard normal reading should reach 200 millimeter mercury or more.

Radiological assessment was done for all cases using four radiographic views for the affected and unaffected wrist preoperatively. These radiographic views included; AP view of both wrist showing the third metacarpal bone in full ulnar and radial deviation, lateral view in neutral flexion, and oblique view 45 degrees showing the distal and proximal poles of the scaphoid . The following radiographic measurements were undertaken, scaphoid length and AP scaphoid angle (normally  $30 \pm 5$  degrees) in antero- posterior views, and scapho-lunate angle

(normally 30 - 60 degrees with an average of 46 degrees) and lateral intra-scaphoid angle in lateral view (normally  $25 \pm 5$  degrees) . Magnetic resonance imaging was done in some cases especially in proximal-third scaphoid non union with a vascular necrosis to determine the vascular status, the size and the state of the articular cartilage of the proximal fragment.

#### **Surgical Technique:**

After induction of general, regional or local intravenous anesthesia while the patient lying supine on ordinary table with the forearm supinated over a side arm support after application of a pneumatic tourniquet to the arm. A volar curvilinear skin incision was made over the scaphoid tuberosity and distal radius just over the flexor carpi radialis tendon. The volar surface of the scaphoid was approached by making an incision through the wrist capsule and the radio-scapho-capitate ligament complex which was carefully divided and retained for later repair with the muscle pedicle.

The site of nonunion was explored and the fibrous or cartilagi-

nous tissue was curetted. The edges of the sclerotic bone were removed using a microsagittal saw or a powered burr till a viable bleeding bony surface was reached. The resulting bony defect in both proximal and distal fragment was shaped to form an oval cavity parallel to the longitudinal axis of the scaphoid, then the resultant bony defect was measured in millimeters to determine the size of the pedicle bone graft from volar surface of the distal radius.

On the distal radius the pronator quadratus muscle was identified and a block of bone graft equal to the resultant defect was outlined at its distal insertion close to the abductor pollicis longus tendon (Figure 1). Multiple drill holes along the margin of the bone block graft was done using 2 millimeter Kirshner wire to facilitate separation with a sharp small curved osteotome or bone gauge. Care should be taken to avoid detachment of the muscle pedicle from the harvested bone block and also to ensure a pedicle of 15-20 millimeters thickness which is based on the anterior interosseous vessel. If the muscle

pedicle bone graft was too tight and short to reach the already formed bony trough at the site of nonunion; then another distal ulnar incision was added to release the ulnar origin of the pronator quadratus muscle. The proximal and distal scaphoid segments were aligned carefully as a traction force was applied to the thumb to correct any intercalated segmental instability and the humpback deformity. The muscle pedicle bone graft was then inserted snugly into the performed cavity in the volar scaphoid surface.

Restoration of scaphoid length and realignment of both scaphoid fragments and the pedicle bone graft should be assessed intraoperatively by both visual and radiographic methods which was also useful to ensure correct placement of the Kirshner wires. The normal length of the scaphoid was judged by keeping the carpus in dorsiflexion and ulnar deviation bearing in mind that the distal pole of the scaphoid is attached to the scaphoid - trapezium - trapezoid joint and the proximal pole is attached to the lunate by scapholunate ligaments.

The proximal, distal scaphoid segments and the pedicle bone graft were firmly fixed with two 0.8 or 1mm Kirshner wires introduced at the region of the scaphoid tuberosity. In three cases a third Kirshner wire was added and introduced through the pedicle bony block to either the proximal or the distal scaphoid fragment when the graft was unstable in addition to free cancellous bone graft packed around the pedicle graft and the depth of the defect. This simple wire added a good job to the stability of the graft and subsequently supported the volar aspect of the scaphoid which was usually deficient after correction of the humpback deformity. Also in another patient one K. wire was used to fix the scaphoid to the capitate to achieve more stability. The radio-scapho-capitate ligament complex was sutured to the sides of the pronator quadratus pedicle graft using 1/0 absorbable Vicryl or Dixon suture material to ensure more stability of the graft. All the Kirshner wires were cut short beneath the skin without bending in most of cases and then absorbable subcutaneous and subcuticular skin sutures were done.

#### **Post-operative care :**

A long-arm thumb spica cast was applied with the thumb in palmer abduction and the elbow flexed to 90 degrees with the forearm in neutral rotation to block pronation and supination thus avoiding shearing stress to the graft. After one month a short-arm thumb spica cast was applied for another one month then a functional wrist brace for another one or two months according to the radiological union . When stable bony union was achieved all Kirshner wires were removed under local intravenous anesthesia. Radiographic assessment was done monthly till complete solid radiological union then every 6 months till the time of the final follow up.

#### **Clinical assessment of the final results:**

All patients were examined clinically regarding the following points. Presence or absence of pain and tenderness, strength of the hand grip, the final range of motion of the affected wrist in all directions, and finally these post-operative clinical measurements were compared to preoperative

one. The overall clinical outcome was also assessed using the modified scaphoid outcome score proposed by Robins and Carter (1995).

**Radiological assessment of the final results:**

The following points were assessed radiologically; occurrence of union or not, time to union, post-operative scaphoid length, AP scaphoid angle, scapho-lunate angle, and lateral intra -scaphoid angle. All these measurements were compared to preoperative measurements. Any post-operative radiological complications were also reported.

**Statistical assessment :**

In this study both descriptive parametric and nonparametric statistical methods were used to evaluate the different statistical relationships. . Data of all patients were analyzed using the SPSS software program for window, version 8, 0. The following statistical tests were used; Chi- square test, Fisher exact test, student T- test. A probability of <0.05 was considered statistically significant (P. value).

**Results**

**Clinical results:**

The average follow up period was 29.3 months with a range between 6 months to 60 months. Non united scaphoid fractures were common in the age group between (26 to 33 years) with an average age of 28.2 years, also it was common in heavy workers (63.6%) in their dominant side (72.7%) and only in male gender. Forced dorsiflexion injury to the wrist was the commonest cause of initial fracture in 81.8% of cases. Initial treatment was adequate in 45.5% of patients and inadequate in 54.5%. The shortest period of non-union was 6 months and the longest was 64 months with an average of 27 months. Scaphoid non union through the waist and type D3 fracture were the commonest types. All patients had a complaint of wrist pain and weak hand grip and 36.4% of these patients had some degree of wrist stiffness in the morning. The mean preoperative range of motion in dorsiflexion was 54.6 degrees, palmer flexion was 62.2 degrees, radial deviation was 14.5 degrees, and ulnar deviation was 19 degrees. Comparing these



measurements to the range of motion of the normal wrist was found to be statistically significant. The mean grip strength of the affected wrist was 188 millimeter mercury in comparison to 265 of the normal wrist (Table II). The relationship between the range of motion and grip strength of the affected wrist preoperatively and postoperatively was found to be statistically significant (Table III).

The percentage of improvement of the affected wrist range of motion and grip strength to the normal wrist in relation to the duration of non union of scaphoid fractures were found to be higher in cases with short - timed scaphoid non union but this relationship was found to be statistically significant for grip strength and wrist dorsiflexion only (Table IV).

**Radiological results:**

The mean preoperative scaphoid length in the affected wrist was 19.1 millimeters, anteroposterior scaphoid angle was 27.3 degrees, scapholunate angle was 62.9 degrees, and the lateral intrascaphoid angle was 32.1 degrees. Comparing these measure-

ments to normal wrist was found to be statistically significant (Table V).

Also after postoperative surgical correction of the flexion deformity of the scaphoid and realignment of the proximal and distal fragment with the pedicle bone graft; the changes in the same preoperative and postoperative radiological measurements of the affected wrist were found to be statistically significant (Table VI). The relationship between the changes in the radiological measurements and the duration of scaphoid non union was found to be higher in short - timed scaphoid non union and lower in long-timed scaphoid non union. These changes in the radiological measurements were found to be statistically significant only for scaphoid length (Table VII). The average period for radiological union of non united scaphoid fracture was 12.7 weeks with a range between 8 weeks to 17 weeks.

All distal third scaphoid fractures were united in a period less than 12 weeks, 66.6% of cases with proximal third non united

scaphoid fractures had united in a period between 16 to 17 weeks, and 28.6% of cases with non united scaphoid fracture through the waist had united in a period less than 12 weeks and 57.2% of these fractures had united in a period less than 16 weeks (Table VIII). All types of scaphoid nonunion were united but in different timing. D1 and D2 were united in shorter time than D3 and D4 but the difference in timing were statistically insignificant.

**Post-Operative Complications:**

One patient had occasional wrist ache after working activity with weak hand grip together with mild degree of osteoarthritis of the scaphoradial joint. This patient was the first case operated up on and he had non united scaphoid fracture since 5 years and the pedicle bone block was packed out in the early post- operative period

at the time of changing the plaster after three weeks together with partial collapse and loss of length, and distal migration or packing out of one K. wire which was removed in the clinic. After complete union the patient had refused removal of the second K. wire (Figure 4). Sudeck's atrophy was also reported in another patient who was completely reversed by physiotherapy. Kelloid scar formation was also reported in one patient.

**Over all end results:**

According to scaphoid outcome scoring, satisfactory results were reported in 90.9% of cases with 54.5% excellent and 36.4% good results. Unsatisfactory fair results were reported in one patient (9.1%).

Case presentation (Figure 2, 3, and 4).

**Table (I):** Demographic data.

	Number	Percentage
*Age group in years ( average28.2)		
• 18 – 25	2	18.2
• 26 – 33	6	54.5
• 34 – 41	3	27.3
* Sex group		
• male	11	100
• female	0	0
*Side affected		
• right ( dominant )	8	72.7
• left ( non dominant )	3	27.3
*occupation		
• heavy workers	7	63.6
• light workers	2	18.2
• non workers of students	2	18.2
*Mechanism of Injury		
• forced wrist dorsa flexion	9	81.8
• hit by heavy object	2	18.2
*Adequacy of previous treatment		
• adequate	5	45.4
• inadequate	6	54.6
*Type of fracture		
• D1	3	27.3
• D2	2	18.2
• D3	5	45.4
• D4	1	9.1
*Complaint		
• wrist pain	11	100
• weak hand grip	11	100
• stiff wrist	4	36.4
*Site of non- union :		
• waist	7	63.6
• proximal third	3	27.3
• distal third	1	9.1

**Table (II):** Comparison between clinical measurements in normal and injured wrist pre-operatively.

	Unaffected wrist		Injured wrist		T test	P.Value
	Mean	Standard Deviation	Mean	Standard Deviation		
Dorsal Flexion (DF)	70	2.2	54.6	4.3	18.4	<0.05*
Palmar flexion (PF)	78.3	1.3	62.2	4.9	17.1	<0.05*
Radial deviation (RD)	21	0.7	14.5	4.8	6.7	<0.05*
Ulnar deviation (UD)	32.6	3.1	19	4.2	16.4	<0.05*
Grip strength	265	12.2	188	16.3	29	<0.05*

• = Statistically significant.

**Table (III):** Comparison between pre-operative and post-operative clinical measurements in injured wrist.

	Pre-operative		Post-operative		T.test	P.value
	Mean	Standard deviation	Mean	Standard deviation		
Dorsal Flexion	54.6	4.3	60.6	5	5.1	<0.05*
Palmar flexion	62.2	4.9	69.1	5.3	5.5	<0.05*
Radial deviation	14.5	4.8	18.2	6.4	4.9	<0.05*
Ulnar deviation	19	4.2	25	4.1	5.8	<0.05*
Grip strength	188	16.3	223	21.8	5.3	<0.05*

\* = Statistically significant.

**Table (IV):** The relationship between duration of nonunion and clinical results.

Duration of nonunion in months	Percentage of improvement of grip strength to the normal	Percentage of improvement of range of motion to the normal			
		DF	PF	RD	UD
6-18	18.3	16.3	12.7	25	22.3
19-31	13.8	15.2	11.6	20.1	18.4
32-44	10.4	11.5	8.9	16.8	15.8
45-57	9.6	8.2	7.5	14.1	13
58-70	8.1	7.1	6.8	12.7	11.6

DF (dorsal flexion), PF (palmar flexion), RD (radial deviation), UD (ulnar deviation)

**Table (V):** Comparison between radiological measurements in normal and injured wrist pre-operatively.

	Unaffected wrist		Injured wrist		T.test	P.value
	Mean	Standard deviation	Mean	Standard deviation		
Scaphoid length	21.3	3.3	19.1	3.1	10.5	<0.05*
A.P scaphoid angle	21.2	2.9	27.3	4.8	4.1	<0.05*
Scapholunate angle	47	10.3	62.9	12.1	6.3	<0.05*
Lateral intrascaphoid angle	24.7	5.2	32.1	7.4	5.3	<0.05*

\* = Statistically significant.

**Table (VI):** Comparison between pre-operative and post-operative radiological measurements in injured wrist.

	Pre-operative		Post-operative		T.test	P.value
	Mean	Standard deviation	Mean	Standard deviation		
Scaphoid length	19.1	3.1	21.2	3.3	6.1	<0.05*
A.P scaphoid angle	27.3	4.8	22.4	5.2	6.4	<0.05*
Scapholunate angle	62.9	12.1	52.2	10.3	4.1	<0.05*
Lateral intrascaphoid angle	32.1	7.4	27	6.3	3.3	<0.05*

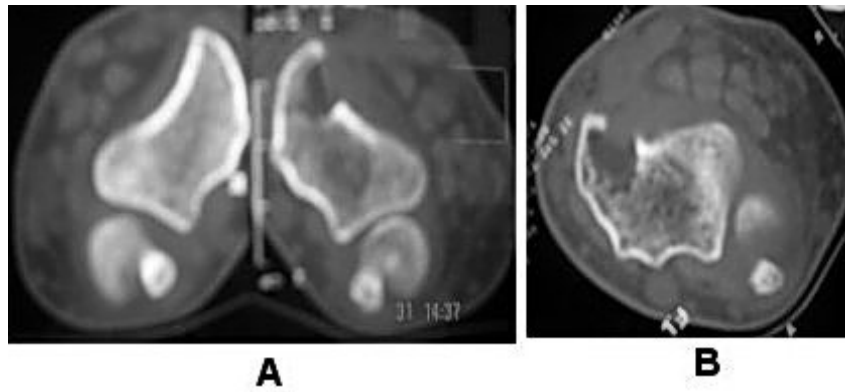
\* = Statistically significant.

**Table (VII):** The relationship between duration of nonunion and the percentage of improvement of the radiological measurements to the normal side.

Duration of nonunion in months	Scaphoid length	A.P scaphoid angle	Scapholunate angle	Lateral intrascaphoid angle
6-18	18.3	35.9	25.2	28.4
19-31	14.8	33.3	24.3	26.3
32-44	13.1	32.5	20.1	23.7
45-57	9.5	30.1	16.3	20.1
58-70	8.9	28.3	13.8	18.6

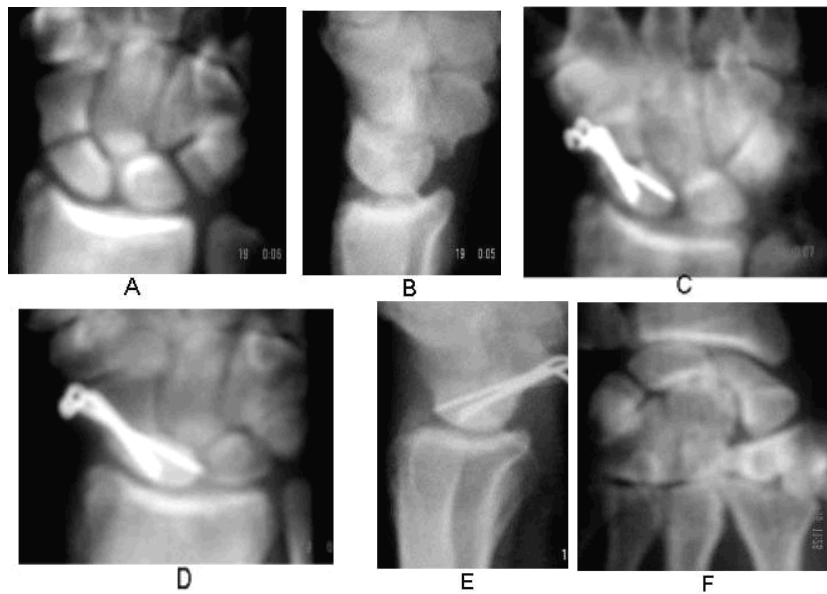
**Table (VIII):** The relationship between fracture site and the time of radiological union.

Radiological union(weeks)	No	%	Fracture site					
			Waist		Proximal third		Distal third	
			No	%	No	%	No	%
< 9 weeks	3	27.3	2	28.6	-	-	1	100
9-12 weeks	5	45.4	4	57.2	1	33.3	-	-
> 12 weeks	3	27.3	1	14.2	2	66.7	-	-
Total	11	100	7	100	3	100	1	100



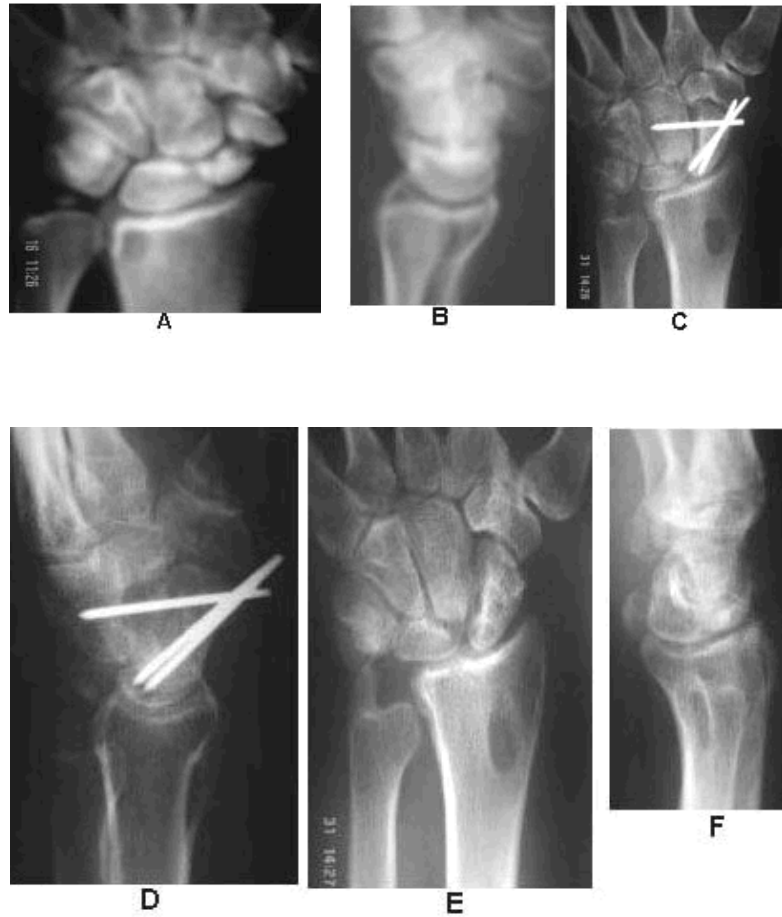**Figure 1:**

- Post-operative CT scan showing the donor site for the pronator quadrates muscle pedicle bone graft from distal volar surface, and the resultant bony defect.



**Figure 2:**

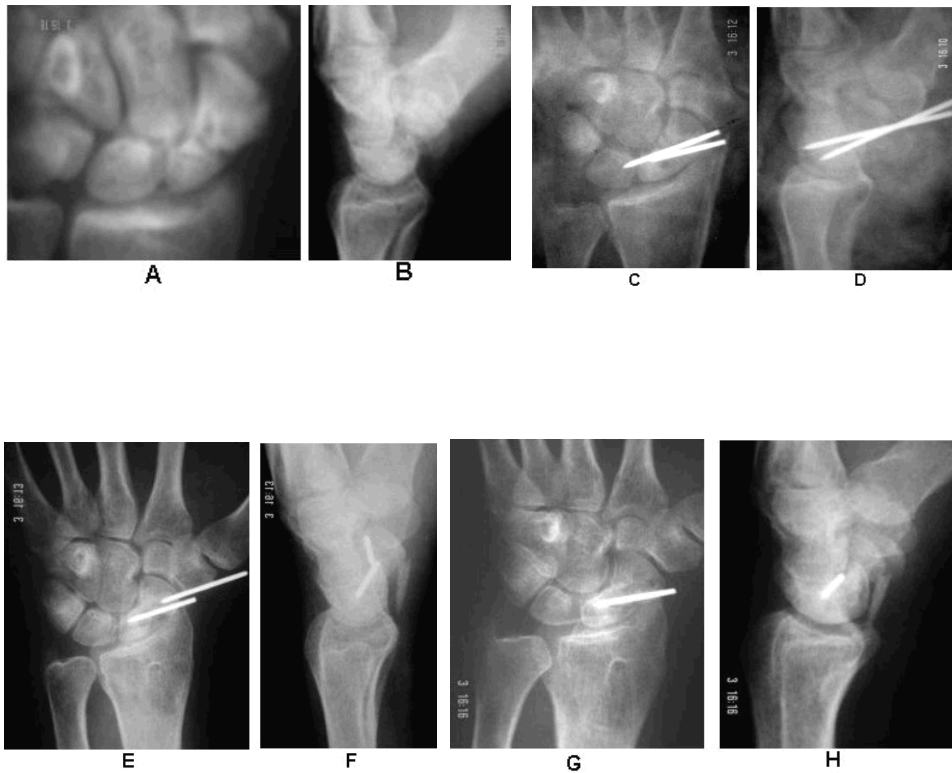
- AP and lateral radiographs of 15 weeks ununited scaphoid fracture through the waist (A , B).
- Post-operative (C) and 8 weeks follow-up radiographs (D) showing bone healing.
- 15 weeks follow-up radiograph (E) showing complete bone healing.
- 22 weeks follow-up radiograph (F) after k.wires removal.



**Figure 3:**

- AP and lateral radiographs of 20 weeks ununited scaphoid fracture with bone resorption (A , B).
- 16 weeks post-operative follow-up radiograph showing two trans-scaphoid K.wires and one trans-scapho-capitate K.wire (C , D) showing complete bone healing.
- 26 weeks follow-up radiographs (E , F) after K.wires removal





**Figure 4 :**

- AP and lateral radiographs ( **A , B** ) of 60 weeks ununited scaphoid fracture.
- 4 weeks follow-up radiographs showing fixation with 2 K.wires ( **C , D** ).
- 14 weeks follow-up radiographs ( **E , F** ) showing complete bone healing with packing-out of one K.wire (which was removed under local anesthesia), and the pronator muscle pedicle bone graft as well.
- 32 weeks follow-up radiographs ( **G , H** ).

### **Discussion**

The ideal treatment of non united scaphoid fractures remains unresolved and controversial. The vascularized bone grafting techniques described in the literatures. Includes, pronator quadratus pedicle bone graft (Kawai and Yamamoto (1988), distal radius bone graft (Zaidenberg et al 1991), distal ulnar bone graft (Guimberteau and Panconi 1990), distal second metacarpal bone graft (Brunelli et al 1992), and iliac crest bone graft (Markus et al 1999).

Vascularized bone grafting procedures facilitates healing in relation to the poor blood supply of the proximal scaphoid fragment in addition to the support given by this corticocancellous bone graft to the volar surface after restoration of the normal scaphoid alignment and length.

Kawai and Yamamoto (1988) had modified the pronator quadratus bone grafting technique described by Braun (1983), and Chacha (1984), and they had reported early bony union with consistently good results without the

need of any especial equipment.

Herbert screw fixation and grafting technique for non united scaphoid fracture provides rigid fixation that allows early mobilization and shorter period of cast immobilization, but it is costly, technically difficult, requiring surgical skills, and special equipments (Herbert and Fisher 1984, Kawai and Yamamoto 1988, Radford et al 1990).

The demographic and clinical data reported in this paper regarding age, sex, side affected, occupation, mechanism of injury, time of non-union, adequacy of initial treatment, patient complaint, site of non union, and the type of fracture were coincident with the reported data in the literatures (Cooney et al 1980, Herbert and Fisher 1984, Smith et al 1990, Radford et al 1990, Filan S. and Herbert 1996, Dooley 1968, Fernandez 1990, Kaulesar et al 1990).

The mean value of wrist joint range of motion and hand grip strength was changed significantly after radiological union in compar-

ison to preoperative value. These findings were similar to Stark et al (1988) and Leyshon et al (1984). The possible explanation of the increased range of motion and grip strength could be related to the fact that obtaining bony union in closely or nearly normal anatomy of the scaphoid and absence of wrist pain thus allowing the patient to use his wrist in a positive way without any limitation.

The post-operative improvement in wrist range of motion and grip strength in short-timed scaphoid non-union were better than long-timed scaphoid non union due to the following factors; difficulty in restoring normal anatomy, increased incidence of degenerative changes and wrist stiffness, increased time to get union due to more a vascularity of the proximal fragment and finally increased incidence of post-operative reflex sympathetic dystrophy with long-timed scaphoid non union.

This paper agrees with Sakuma and Invue (1996) that poor results were common with long-timed established scaphoid non-union,

whereas it disagrees with Daly et al (1996) as they had found that the final outcome was not related to the duration of non-union.

Restoration of the lost scaphoid anatomy to near normal by the pedicle bone graft and maintaining this by K.wire and cast till bony union leads to significant improvement of the radiological measurements which was better in short-timed scaphoid non-union. These findings were similar to the findings of Stark et al (1987) and Adams et al (1988).

All cases included in this study had achieved radiological union after pronator quadratus pedicle bone graft in an average period of 12.7 weeks with a range between 8 to 17 weeks. This rate of bony union was higher and this time of union was relatively shorter in comparison to other methods used in treatment of non-united scaphoid fractures as Russe (1960) had reported 80-90% union rate in an average period of 4.6 months and Cooney et al (1980) achieved 80% union rate in an average period of 4.2 months after Matti-Russe technique. Daly et al

(1996) had reported 96% union rate in an average period of 4 months and Filan and Herbert (1996) had reported 82% union rate after Herbert screw fixation and iliac bone graft for type D1 and type D2 non united scaphoid fractures .

Komureu et al (2001) had reported 100% union rate after pronator quadratus pedicle graft in 9.2 weeks, 100% union rate in 14.5 weeks after AO cannulated screw and graft, and 100% union rate in 14.3 weeks after Herbert screw and graft .

Bo Munk and claus Larsen (2004); had reported about their detailed retrospective study of 147 publications including 5246 cases of scaphoid non union and found average union rate of 80% in the group of patients treated with non vascularized bone grafting techniques without internal fixation in an average period of 15 weeks. They reported also 84% union rate in the group of patient treated with non vascularized bone grafting techniques with internal fixation in an average period of 7 weeks and 91% union rate in the

group of patients treated with vascularized bone grafting technique with or without internal fixation in an average period of 10 weeks. They did not found single prospective randomized study comparing different treatment options for scaphoid non union and they started that; still there is a need for improvement in the treatment of scaphoid non union.

Mathoulin et al (2002); had reported about their long term results of surgical treatment of scaphoid non union in 72 patients with vascularized anterior radial graft with a union rate of 91.6% in an average period of 9.8 weeks with excellent functional results in 63.9%, good results in 12.5 %, and poor results in 5.6 of patients.

Dailiana et al (2006); had treated a patients with non united scaphoid fracture at the waist with distal palmer predicted radial graft and had achieved excellent results in 5 patients, and good results in 4 patients. They concluded that this technique had required one approach, and allowed correction of humpback deformity, carpal

height, and grip strength without donor site morbidity.

The reported fair result in this study was the first operated patient and was related mainly to occurrence of post-operative degenerative radiocarpal arthritis although the fracture was united after long-timed scaphoid nonunion even after packing out of one K. wire, and the pedicle bone graft from its bed; but fortunately this patient had some free pure cancellous bone graft packed at the depth of the resected scaphoid nonunion site. This finding was similar to the findings of Warren-Smith and Barton (1988), Amadio et al (1992), and Daly et al (1996) that the radiological union does not necessarily correlate with symptoms relief and good function. In this study there was no reported complications related to distal radius pedicle bone graft donor site.

In conclusion; pronator quadratus pedicle bone graft is a simple procedure without the need of special equipment and special surgical skills, and was associated with some complications which

was genuine and did not affect the final outcome. Scaphoid outcome score was very valuable as it evaluates the clinical and radiological outcome together with the functional personal satisfaction after this period of disability.

The high union rate achieved in this study could be related to the aggressive resection of the fibrous tissue and sclerotic bone defect, correction of the humpback deformity and increased vascularity and stability by this vascularized muscle pedicle bone graft thus achieving vascularity and stability of the proximal and distal scaphoid fragments. The principal benefits of this technique was relief of pain together with an increase in wrist range of motion and the hand grip strength, thus it is considered as simple, inexpensive, and effective technique for treatment of symptomatic scaphoid non-union

### References

**Adams B., Blair W., Regan, D. and Grundberg A. (1988)** : Technical factors related to Herbert screw fixation .J. Hand Surg; 13- A: 893 - 899.

**Amadio P. C. (1992)** : Scaphoid fractures. Orthop. Clin. North. Am; 23:7-17.

**Bo munk and Claus falck Larsen (2004)** : Bone grafting the scaphoid non union; a systematic review of 147 publications including 5246 cases of scaphoid non union. Acta Orthop Scand; 75 (5): 618-629.

**Braun R. M. (1983)** : Pronator Pedicle bone grafting in the forearm and proximal carpal row. Orthop. Trans; 7: - 35.

**Brunelli F., Mathoulin C. and Saffar P. (1992)** : Description. D'un greffon osseux vascularise. Prelere au niveau de la tete du dexoieme Meta carpien. Ann. Chiv. Main; 11 : 40 - 45.

**Chacha P. B. (1984)** : Vascularized pedicular bone grafts. Int. Orthop; 8:117- 138.

**Cooney W., Dobyns J., and Linscheid R. (1980)** : Non - union of scaphoid, Analysis of results form bone grafting .J. Hand Surg; 5:343 - 354.

**Cooney W., William P. and Ronald L. (1996)** : Fractures and dislocation of the wrist in: Rockwood CA., Green DP. Eds; Fractures. 3rd Ed, Philadelphia, New York, London, Hgerstow: JB Lippincott company; (1): 563- 678.

**Dabenzies E., Mathews R. and Faust. D. (1982)**: Injuries to the carpus. Fractures of the scaphoid.J Orthopedics; 5:1510.

**Dailiana Z., Malizos K., Zachos V., Varitimidis S., Hantes M. and Karantanias A. (2006)** : vascularized bone graft from palmer radius for the treatment of waist non union of the scaphoid. J Hand Surg; 31 (3): 3a+ - 404.

**Daly K., Gill P., Magnussen P. and Simonis R. (1966)** : Established non-union of the scaphoid treated by volar wedge grafting and Herbert screw fixation. J. Bone Joint Surg; 78 - B : 530 - 534.

**Dooley B. J. (1968)** : Inlay bone grafting for non-union of the scaphoid by the anterior approach. J.Bone Joint Surg; 50 - B : 102 - 109.

Fernandez D. (1990): Anterior bone grafting and conventional lag screw fixation to treat scaphoid non- union. J. Hand Surg;15-A: 140 - 147.

**Filan S. and Herbert T. (1996)** : Herbert screw fixation of scaphoid fractures. J.Bone Joint Surg; 78-B: 519 - 529.

**Green D. (1985)** : The effects of a vascular necrosis on Russe bone grafting for scaphoid non-union. J. Hand Surg;10- A (5): 597 - 605.

**Guimberteau J. and Panconi B. (1990)** : Recalcitrant non-union of the scaphoid treated with a vascularized bone graft based on the ulnar artery. J. Bone Joint Surg; 72 - A: 88 - 97.

**Herbert T. and Fisher W. (1984)** : Management of the fractured scaphoid using a new bone screw. J.Bone Joint Surg; 66-B: 114-123.

**Kauer J. M. G. (1980)** : Functional anatomy of the wrist. Clin. Orthop. And Related Research; 149: 9 - 20.

**Kaulesar S. D., Johannes E. J. and Mart. P. K. (1990)** : Cortico - cancellous grafting and an AO / ASIF lag screw for non-union of the scaphoid .J. Bone Joint Surg; 72 - B : 835 - 838.

**Kawai H. and Yamamoto K. (1988)** : Pronator quadratus pedicle bone graft for old scaphoid fractures. J. Bone Joint Surg; 70-B: 829- 381.

**Komoreu A., Mustafa B. and Elhen G. (2001)** : Results of surgical treatment in scaphoid non-union. J. Southern Orthopedic Association; (10): 215-220.

**Leyshon A, Ireland J. and Trichy E. (1984)** : The treatment of delayed union and non-union of the carpal scaphoid by screw fixation. J.Bone Joint Surg; 66 - B: 124 - 127.

**Markus G., Claudia R., Martin. L., Inove G. and Sakuma M. N. (1990)** : Vascularized bone graft from Iliac crest for the treatment of non- union of the proximal part of the scaphoid with a vascular fragment. J.Bone Joint Surg; 81-A (10): 1414 - 1428.

**Mathoulin C., Vandeputte G., Haerle M., Valenti P. and Gilbert A. (2002)** : Scaphoid non union treated with vascularized radius graft: long - term results. J Bone Joint Surg; 84 (B): 49.

**Mc Rae R. (1987)** : The hand, Clinical orthopedic examination. 2nd.ed, Edinburgh, London, Melbourne, New York; 56 - 70.

**Radford P., Mathew M. and Meggitt B. (1990)** : The Herbert screw for delayed and non-union of scaphoid fractures: a review of fifty cases. J.Hand Surg; 15-B: 455 - 459.

**Robbins R. and Carter P. (1995)** : Iliac crest bone grafting and Herbert screw fixation of non-union of the scaphoid with a vascular proximal poles. J.Hand Surg; 20-A: 818 -831.

**Russe O. (1960)**: Fracture of the carpal navicular. Diagnosis, non operative and operative treatment. J. Bone Joint Surg; 42 - A : 754 - 768.

**Sakuma M. and Inove G. (1966)** : The natural history of

scaphoid non-union. Radiographical and clinical analysis in 102 cases. Arch. Orthop. And Trauma Surg;115: 1- 4.

**Smith K., Helm R. and Tonkin M. (1991)** : The Herbert Screw for scaphoid Fractures. An. Chirmain Memp.Super;16:556-63.

**Stark A., Brostromal A. and Svartengren G. (1987)**: Scaphoid non- union treated with Matti - Russ. Technique. Long - term results. Clin Orthop; 214: 175.

**Stark H., Richard T., Zemel N. and Ashworth C. (1988)** : Treatment of ununited fractures of the scaphoid by iliac bone grafts and Kirschers wire fixation .J.Bone Joint Surg; 70 -A:982 - 991.

**Warren - Smith C. and Batron N. (1988)** : Non - union of the scaphoid: Russe graft versus Herbert screw. J. Hand Surg; 13- B: 83.

**Zaidenberg C., Siebert J. and Angrigiani C. (1991)** : A new vascularized bone graft for scaphoid non-union. J. Hand Surg;16 - A : 474 - 478.



REPRINT

# **BENHA MEDICAL JOURNAL**

**PRONATOR QUADRATUS  
MUSCLE PEDICLE BONE GRAFT IN  
NON-UNITED SCAPHOID FRACTURES**

**Gamal El-Adl MD**

**Published by  
Benha Faculty of Medicine**

*Volume 26 Number 3  
Sept. 2009*

57

Benha M. J.

Vol. 26 No 3 Sept. 2009

### Introduction

Adenoidectomy and tonsillectomy, 2 of the most common childhood surgeries, are performed for a number of indications, the most common being airway obstruction caused by adeno-tonsillar hypertrophy (Benninger & Walner, 2007). Although adenotonsillar surgery is safe and effective in such indications, parents remain concerned about postoperative complications including late recurrence.

The main reason of postopera-

## ADENOIDECTOMY : SHOULD IT BE ENDED WITH AN ENDOSCOPIC LOOK?

Mohamed A. Eltoukhy MD

Department of ENT, Benha Teaching Hospital., Egypt

### Abstract

**Objective:** to evaluate the efficacy of conventional technique of adenoidectomy by means of trans operative endoscopic look of the nasopharynx and to evaluate the need for including telescope as part of usual instrument used in adenoidectomy. **Study design:** a prospective and comparative study. **Setting:** Benha Teaching Hospital. **Materials & Methods:** a group of 38 children indicated for adenoidectomy alone or in combination with tonsillectomy or with ventilation tube placement. All cases underwent curettage adenoidectomy by the same surgeon. Endoscopic look, to the nasopharynx was followed using Hopkins rigid telescope 4mm, 45 degree trans orally. **Results:** 32 out of 38 cases had residual adenoid tissues after conventional adenoidectomy representing 84.2%. Complete removal of such residual adenoid tissue was achieved endoscopically. No significant complications were encountered as regard hemorrhage or trauma.

**Conclusion:** Conventional adenoidectomy by curettage was effective in less than 16%. Endoscopic look following conventional adenoidectomy is imperative to verify the incidence of residual adenoid tissues, to assure complete, accurate removal of such tissue in the same sitting endoscopically, and to lower the incidence of recurrence.

58

Mohamed A. Eltoukhy

tive incomplete restoration of nasal respiration is suggested to be incomplete removal of adenoid tissue which may result from specific features of the adenoid size, location, anatomical structure of the nasopharynx, the surgeon's equipment and experience (Kovaleva, 1994).

Modrzynski and Zawisza (2003), suggested that allergic rhinitis is an important risk factor

for adenoid hypertrophy in children, and early prevention of exposure to allergens may help reduce occurrence of adenoid hypertrophy.

The incidence of incomplete removal of adenoid tissues after conventional adenoidectomy was 70.1 % (Bros-Soriano et al., 2004). Kubba & Bingham (2001), recommended endoscopic look at the time of adenoidectomy to assure complete adenoid tissue removal. Hung-Meng et al., (1998), advised the combined approach of conventional and endoscopic adenoidectomy. Our object was to present our experience in utilizing transoperative endoscopic look post conventional adenoidectomy to evaluate the efficacy of such traditional procedure by curettage and to proceed to complete removal of residual adenoid tissue, if there, in the nasopharynx.

### **Patients and Methods**

This study was conducted on 38 children (22 boys and 16 girls) aging from 4 to 9 years, with an average age of 5.8 ys, who had: nasal obstruction, postnasal discharge, nasal speech, decreased hearing, obstructive sleep disorder, slower development than peers and loss of appetite; suggestive of post nasal adenoid hypertrophy. All patients had ENT clinical examinations, hematological and lateral skull radiological investigations if needed. Adenoidectomy was performed for them, 18 cases had concurrent tonsillectomy and 4 had ventilation tube placement as well.

**Operative technique:** conventional adenoidectomy by curettage was done with proper soft tissue retraction and indirect visual inspection using laryngeal mirror.

### **59**

Benha M. J.

Vol. 26 No 3 Sept. 2009

Curettage was performed with a Barnhill adenoid curette, sizes 0

through3. The proper size of the adenoid curette was selected according to Danial & John (2001): the proper size of the adenoid curette window is the distance between the lateral borders of the upper central incisors which correlates with the distance between the tori tubarius in the nasopharynx. Hemostasis was achieved with suction and gauze packing. Irrigation of the nasopharynx with cold saline was routinely undertaken to remove the blood clots and allow the best possible visualization of the nasopharynx. Trans oral endoscopy with Hopkins 4mm rigid telescope 45 degree to inspect the nasopharynx for the residual adenoid tissue was carried out according to Lo & Rowe (2006). Any remnant of adenoid tissue found in the nasopharynx was removed trans nasally piece by piece using either a straight or 45 Blakesley forceps followed by packing for hemostasis. All the operations were done under general anesthesia via endotracheal intubation and by the same surgeon.

## **Results**

Thirty eight children underwent conventional adenoidectomy by curettage, 21 cases (57%) were males and 17 cases (43%) were females. Eighteen cases had concurrent tonsillectomy and 4 cases needed ventilation tube insertion and all patients tolerated their procedures well and had no intraoperative bleeding or post operative hemorrhage or injury to both tori tubarius or choanae. Endoscopic look to the nasopharynx post conventional adenoidectomy revealed 32 out of 38 cases with residual adenoid tissue representing 84.2% of the series. The location of the residual adenoid tissue was at the superior portion of the nasopharynx in 19 cases (60%), at the pharyngeal recess in 10 cases (30%) and at the orifice of Eustachian tube in 3 cases (10%). Endoscopic removal of the adenoid

residues were achieved completely in all cases. Trans nasal removal of the adenoid remnant, allowed co-incidental diagnosis of some factors of nasal obstruction such as septal deviation in 8 cases and hypertrophied inferior turbinate in 3 cases.

## 60

Mohamed A. Eltokhy

### Discussion

Complications associated with adenoidectomy are uncommon, yet do occur. Sequels such as persistent hypernasal speech (Parton & Jones 1998), velopharyngeal incompetence (Robinson, 1992), nasopharyngeal stenosis (Mc Laughlin et al., 1997), atlantoaxial subluxation (Randall & Hoffer, 1998) and recurrence (Skilbeck et al., 2007) are reported as post adenoidectomy complications. Wormald and Prescott (1992), found that up to 50% of the nasopharynx may be occupied by lymphoid tissues without nasal symptoms, so, we may miss removal of adenoid tissue despite symptoms improvement. Adenoidectomy performed without vision may be one of the reasons for recurrence of symptoms, and the need for revision adenoidectomy is not uncommon. Consequently, the surgical technique should be improved by visualization of the post nasal space either by mirror or an endoscope (Liapi et al., 2006). Stern et al., (2006) concluded that endoscopic partial adenoidectomy may be a safe and effective procedure for the treatment of nasal obstruction in children with submucosal cleft palate. The use of trans oral telescope provides a clear visualization that help complete removal of the adenoid, reduction of unnecessary trauma, and effective control of bleeding (Shehata et al., 2005). Skilbeck et al., (2007), concluded that the incidence of regrowth of adenoid in patients undergoing conventional adenoidectomy by

curettage is similar to that reported in those operated by suction diathermy. On the other hand, Janes et al., (2007), found that the method of performing adenoidectomy affects the incidence of residual adenoidal size with significant less recurrence rate 6 months follow up by suction diathermy than by curettage method. However, Buchinsky et al., (2000), concluded that adenoids rarely, if ever, regrow enough to cause symptoms of nasal obstruction after adenoidectomy that includes visualization and electrocautery of the adenoid bed.

Bross-Soriano et al., (2004), reported an incidence of 70.1% of residual adenoid tissue post con

61  
Benha M. J.

Vol. 26 No 3 Sept. 2009

ventional adenoidectomy, compared with 84.2% in our series.

Bross-Soriano et al., (2004) recommended the use of endoscopic revision with conventional adenoidectomy.

Pagella et al., (2008), used the combined approach of conventional curette and endoscopic adenoidectomy with microdebrider to assure a complete and accurate removal of the mass. Ren et al.,

(1995), stated that incomplete removal of the adenoid tissue

should be avoided at the time of adenoidectomy to prevent the risk of post-operative hypernasality.

Endoscopy at the time of adenoidectomy may be useful as it allows

control of how much adenoid tissue is removed, excludes other causes of nasal obstruction such as deviated septum or hypertrophied turbinate. These findings

may help predict residual symptoms after adenoidectomy and

help to guide further treatment (Kubba & Bingham, 2001).

Hung-Meng et al., (1998), recommended the combined approach

of conventional and endoscopic adenoidectomy as this allows to remove a huge adenoid completely and accurately without prolonging the operative time

and provides a direct and clear view that reduces unnecessary trauma.

Endoscopic removal of the adenoid requires more time than conventional surgery, with prolongation of anesthesia and increasing its risks. Conventional adenoidectomy can remove the main bulk of the adenoid mass, and the endoscopic look to the nasopharynx at the end of the operation, will assure complete, and accurate removal of the adenoid within short operative time.

### **Conclusion**

Conventional adenoidectomy was effective in less than 16 %. So, alone it is far from effective in complete removal of adenoid tissues. Despite importance to remove the main bulk, thus shorten the operative time, conventional adenoidectomy should be assisted by an endoscopic look to completely and accurately remove the possible residual adenoid tissues. Therefore, it is imperative to have

**62**

Mohamed A. Eltoukhy  
an endoscopic look at the end of conventional adenoidectomy.

### **References**

**Benninger M. and Walner D.**

**(2007):** Coblation, improving outcomes for children following adenoidectomy. Clin Cornerstone ; 9 suppl 1 : S 13-23.

**Bross- Soriano D., Schimelmitz- Idi J. and Arrieta-Gomez J.**

**R. (2004):** Endoscopic adenoidectomy ; use & abuse of the technology? Cir Cir Jan-Feb; 72 (1) : 15-9.

**Buchinsky F. J., Lowery M. A. and Isaacson G. (2000):** Do adenoids regrow after excision? Otolaryngol Head Neck Surg Nov ; 123 (5 ) 576-81.

**Daniel G. Deschler and John**

**A. Tucker (2001):** Central incisor width as a predictor of appropriate curette size in adenoidectomy. Ann Otol Rhinol Laryngol 110 : ;

841-43.

**Hung-Meng Huang, Min-Ching C., Yu-Lin C. and Hong-Rong H. A. (1998):** Combined Method of Conventional and Endoscopic Adenoidectomy. Laryngoscope; Jul ; 108 (7) : 1104-6.

**Janes N. E., Syed R. and Prescott C. (2007):** Prospective, randomized, single-blind, controlled study to compare two methods of performing adenoidectomy. Int J Pediatr otorhinolaryngol. Oct ; 71 (10) : 1555-62.

**Kovaleva L. M. (1994):** Repeated adenoidectomy and prevention of the recurrence of adenoid hypertrophy. Vesten Otorhinolaryngol. Jan-Feb ; (1): 18-21.

**Kubba H. and Bingham B. J. (2001):** Can nasal endoscopy be used to predict residual symptoms after adenoidectomy for nasal obstruction? Int J Pediatr Otorhinolaryngol. May 11 ; 58 (3): 223-8.

**Liapi A., Dhonaseker G. and Turner N. (2006):** Role of revision adenoidectomy in pediatric otorhinolaryngological practice. J Laryngol Otol. Mar; 120(3):219-21.

**Lo S. and Rowe-Janes J. (2006):** How we do it : Transoral suction diathermy adenoid abla63 Benha M. J.

Vol. 26 No 3 Sept. 2009  
tion under direct vision using a 45 degree endoscope. Clin Otolaryngol. Oct ; 31 (5): 440-2.

**Mc Laughlin K. E., Jacobs I. N., Todd N. W., Gussack G. S. and Carlson G. (1997):** Management of nasopharyngeal stenosis and oropharyngeal stenosis in children. Laryngoscope; 107 : 1322-31.

**Modrznski M. and Zawisza E. (2003):** Frequency of adenoid hypertrophy in children with allergic diseases. Przegl Lek; 60 (5) : 322-4.

**Pagella F., Matti E., Colombo A., Giourgos G. and Mira E. (2008):** How we do it; a combined method of traditional curette and power assisted endoscopic adenoidectomy.



Acta Otolaryngol.

Aug 8 ; 1-4.

**Parton M. J. and Jones A. S.**

**(1998):** Hypernasality following adenoidectomy : a significant and avoidable complications. Clin Otolaryngol Allied Sci 23:18-9.

**Randall D. A. and Hoffer M.**

**E. (1998):** Complications of tonsillectomy and adenoidectomy. Otolaryngol Head Neck Surg 118 : 61-8.

**Ren Y. F., Isberg A. and Henningsson**

**G. (1995):** Velopharyngeal incompetence and persistent hypernasality after adenoidectomy in children without palatal defect. Cleft Palate Craniofac J Nov; 32 (6): 476-82.

**Robinson J. H. (1992):** Association between adenoidectomy, velopharyngeal incompetence and submucous cleft. Cleft Palate Craniofac J 29:285.

**Shehata E. M., Rageb S.**

**M., Behiry A. B., Erfan F. H.**

**and Gamea A. M. (2005):**

Telescopic-assisted radiofrequency adenoidectomy : a prospective randomized controlled trail. Laryngoscope; Jan; 115 (1) 162-6.

**Skilbeck C. J., Tweedie D. J.,**

**Lloyd-Thomas R. A. and Albert**

**D. M. (2007):** Suction diathermy for adenoidectomy: complications and risk of recurrence. Int J Pediatr Otorhinolaryngol. Jun; 61 (6): 917-20.

**64**

Mohamed A. Eltoukhy

**Stern Y., Segal K. and Yaniv**

**E. (2006):** Endoscopic adenoidectomy in children with submucosal cleft palate. Int J Pediatr Otorhinolaryngol. Nov; 70 (11) : 1871-4.

**Wormald P. J. and Prescott**

**C. A. (1992):** Adenoids : comparison of radiological assessment methods with clinical and endoscopic findings. J Laryngol Otol 106:342-4.

**65**

Benha M. J.

Vol. 26 No 3 Sept. 2009

**ADENOIDECTOMY : SHOULD  
IT BE ENDED WITH AN  
ENDOSCOPIC LOOK?**

Mohamed A. Eltoukhy MD

**BENHA  
MEDICAL  
JOURNAL**

REPRINT

Published by

**Benha Faculty of Medicine** *Volume 26 Number 3*  
*Sept. 2009*

## **GALL BLADDER CARCINOMA : A SINGLE CENTER EXPERIENCE**

**Mohamed El-Hemaly MD**

*Gastroenterology Surgical center,  
Mansoura University, Egypt*

### **Abstract**

**Introduction :** Gallbladder carcinoma is the fifth most common cancer of the gastrointestinal tract. Despite advances in hepatobiliary imaging techniques, the preoperative diagnosis is a difficult task & discovered in (0.2 - 2%) of all surgeries for cholelithiases. Simple cholecystectomy is sufficient if the tumour dose not extend beyond the muscle layer, otherwise, extended cholecystectomy is the surgical option. Survival depends more on stage of the disease than type of treatment provided.

**Aim :** To evaluate patients with gall bladder carcinoma to define the demographics, clinical staging, pathological characters and survival.

**Patients & Methods :** A retrospective study on 55 patients with gall bladder carcinoma at Gastroenterology Surgical Center, Mansoura University between 1985 to 2007.

There were 30 males & 25 females with an average age of 53 years. Patients were classified according to the mode of presentation into four groups and the treatment modalities were according to presentation, state of the tumor & associated liver condition. All patients were followed up by ultrasound (or CT) every 6 months postoperatively. Survival was monitored with respect to the histological type of the tumor & stage of the disease.

**Results :** Gall bladder carcinoma represented 1.4% of a total of 4245 cases of abdominal malignancies in our center. HCV infection was present in 15% and associated gall stone in 45% of patients. We had 28 (51%) patients with obstructed gall bladder, 20 (35.4%) with symptomatic gall stones, 5 (9%) with obstructive Jaundice and 2 (3.6%) with gastrointestinal bleeding. Nothing done for 15 (27%) patients due to advanced tumor & in 14 (25%) patients, extended cholecystectomy done. On the other

hand laparoscopic cholecystectomy was done for 12 (23%) patients as tumour was discovered accidentally. Right hepatectomy was done for 12 (23%) patients due to infiltration of right liver lobe & right hepatic duct. Extended cholecystectomy plus right hemicolectomy was done for one patient & for the last patient extended cholecystectomy was done with pancreaticoduodenectomy. Survival was from 8-43 months according to line of treatment, but 5 years survival was zero percent.

**Conclusion :** Gall bladder carcinoma is not uncommon and the prognosis is not good. Prevention is important by treating symptomatic gall stones, gall bladder polyps more than 1-cm.

*Routine postoperative histopathology is mandatory.*

### **Introduction**

Carcinoma of the gall bladder is the most common malignancy of the biliary tract and 1-2 % of patients who have operation for cholelithiasis are diagnosed with gall bladder carcinoma at the time of surgical exploration or at the histological examination of the resected gall bladder (Misra et al., 2003). Gall bladder carcinoma was found on 0.1-1 % of autopsies; that is 0.2-2 % of all surgeries for the gall bladder (Kapoor & Benjamin, 1997). Gall bladder carcinoma is highly lethal, as anatomic factors promote early local spread. Clinical presentation with distant metastasis is extremely rare (Levy et al., 2001). The early clinical detection of gall bladder carcinoma is difficult because of

its non-specific symptoms. This, along with the rapidly progressive course of the tumor resulted in poor prognosis even after surgery (Piehler & Crichlow., 1978). In the era of laparoscopy many gall bladder carcinomas are diagnosed after laparoscopic cholecystectomy & most of these tumors are in early stage (Varshney et al., 2002). There is a direct link between gall stones and gall bladder carcinoma and incidence of cholelithiasis ranges from 54 % to 97% (Batra et al., 2005). Gall bladder carcinoma is more common in patients with Mirrizi,s syndrome, typhoid carriers, porcelain gall bladder, large sessile polyps (Toda et al., 1995). Adenocarcinoma is the most common histological type (80%) of gall bladder carcinoma

but undifferentiated carcinoma occurs in 6 % & squamous carcinoma in 3 %. A variety of other lesions including cases of adenocarcinoma & carcinoid tumors, sarcoma, melanoma and lymphoma have also been found (Fujita et al., 2005, Huguet et al., 2005). Gall bladder carcinoma remains asymptomatic for a long time or presents with non specific symptoms commonly related to gall stones eg. Pain, anorexia, weight loss, jaundice, pruritus, fever, vomiting, gall bladder mass, enlarged liver and ascites (Memon et al., 2005). An ultrasound scan may show irregular thickening of gall bladder lumen and a mass in gall bladder fossa (Pal & Sharma, 1990). Computed tomography is better than ultrasound with positive predictive value of more than 90 % (Sagoh et al., 1990). Laparoscopic ultrasound and fine needle aspiration cytology may prevent unnecessary laparotomy. Only 8.6 % of the diagnoses are correct preoperatively. Incidental diagnosis "occult" with gall stone is approximately 4% (Iqbal et al., 2003). A difficult gall bladder at surgery should raise the suspicion of carcinoma. Laparoscopic

procedure should be converted to open procedure to avoid trocar-site metastasis or widespread intraperitoneal disseminated disease (Principe et al., 1997).

The management outcome & prognosis depend on time of diagnosis and the stage of the disease. Laparoscopic or open cholecystectomy is curative if diagnosis is unknown and cancer is in-situ stage on histological examination of the specimen. Extended cholecystectomy involves excision of the gall bladder with regional lymphadenectomy combined with excision of the liver substance adjacent to the gall bladder. The recommended extent of liver resection varies from a non-anatomical wedge resection of the gall bladder bed to formal removal of segment IV & V including the gall bladder fossa & even right hepatic lobectomy (Bismuth & Malt, 1979). Majority of patients with gall bladder carcinoma have advanced or unresectable disease. The results of any kind of surgery are generally poor with survival rates of only a few months (Batra et al., 2005). Survival depends more on stage of the disease than type of treatment

provided. The overall five-year survival for gall bladder carcinoma patient is 4.1% and one-year survival 11.8% (Fernando et al., 2004).

**Aim :** Our study aimed to evaluate in a series of fifty five patients with gall bladder carcinoma to define the demographics, clinical staging, pathological characters and survival of such patients.

### **Patients & Methods**

A retrospective study was performed on 55 patients diagnosed with gall bladder carcinoma at Gastroenterology Surgical Center, Mansoura University between 1985 to 2007.

There were 30 males & 25 females with an average age of 53 years.

The incidence of gall bladder carcinoma in comparison to other gastrointestinal malignancies, incidence of HCV infection in addition to the liver condition and associated gall stones were assessed.

Also, we studied the mode of

presentation in our patients & classified into four groups:

**Group I:** (28 patients) presenting with obstructed gall bladder.

**Group II:** (20 patients) presenting with symptomatic cholelithiases.

**Group III:** (5 patients) presenting with obstructive jaundice.

**Group IV:** (2 patients) presenting with GIT bleeding (one patient with hematemesis & the second patient with bleeding per rectum).

Treatment modalities were according to presentation, state of the tumour (local & distant) and associated liver condition (normal or cirrhotic).

Routine histopathological examination of extirpated gall bladder and other excised tissues was done. No adjunctive therapy (chemo - or radiotherapy) was given to the patients.

All patients were followed up by ultrasound or CT (if needed) between 3 & 6 months after surgery

& then every 6 months if the patient alive.

Recurrence of the disease has been considered any recurrence of the tumour, distant metastases, local peritoneal seedling and port site or scar recurrence.

Survival was monitored postoperatively with respect to the histological type of the tumour and the stage of the disease.

Statistical analyses were performed using statistical analysis procedures.

The cumulative survival rate was calculated according to the Kaplan - Meier method and correlation between survival rate & type of treatment and pathological stage was examined. P values of < 0.05 were considered statistically significant.

### Results

In the period 1985 - 2007, fifty five patients with gall bladder carcinoma were studied at the Gastroenterology Surgical Center, Mansoura University.

There were 30 males & 25 fe-

males with a mean age of 52 years (range 40-70).

Gall bladder carcinoma represented 1.4% of a total of 4245 cases of abdominal malignancies with colorectal carcinoma on the top followed by hepatobiliary tumours then tumours of the stomach and esophagus (table 1).

In patients with gall bladder carcinoma, there was associated HCV infection in 15% of patients and gall stones in 45% but the liver was normal in 80% and cirrhotic in 20% of patients

Mode of presentation differed and we classified patients into 4 groups:

**Group I:** 28 (51%) presented with obstructed gall bladder.

**Group II:** 20 (35.4%) patients presented with symptomatic gall stones.

**Group III:** 5 (9%) patients presented with obstructive Jaundice due to infiltration of the biliary system and lymphadenopathy.

**Group IV:** 2 (3.6%) patients pre-

sented with GIT bleeding [one patient with hematemesis due to infiltration of the duodenum & the second patient with bleeding per rectum due to infiltration of the right colon. No one of our patients diagnosed preoperatively to have gall bladder carcinoma.

Treatment options varied according to the presentation, tumor status and condition of the liver (cirrhotic or not). 15 (27%) patients were advanced after exploration due to peritoneal dissemination, multiple liver metastases or encasement of major vessels. So, nothing done and patients treated conservatively. In 14 (25%) patients, extended cholecystectomy was done (en block removal of the gall bladder + wedge resection of the liver & dissection of lymph nodes in the hepatoduodenal ligament and along the hepatic artery).

Laparoscopic cholecystectomy was done for 12 (23%) patients as tumour was discovered incidentally by postoperative histopathology. The tumour in such patients did not penetrate the muscle layer, so nothing done more than simple

cholecystectomy & no need for further exploration.

In 12 (23%), right hepatectomy was done due to infiltration of the right liver lobe and right hepatic duct. In one patient right colon was infiltrated by gall bladder carcinoma so, extended cholecystectomy was combined with right hemicolectomy. The last patient showed infiltration of the duodenum so pancreatico-dudenectomy was done with extended cholecystectomy (table 2).

Postoperative pathology was adenocarcinoma in all patients with different grades of differentiation.

As regard complications, four patients developed bile leak postoperatively but treated conservatively. Another one patient developed internal haemorrhage after extended cholecystectomy with pancreatico- dudenectomy and patient explored again to control bleeding from retropancreatic tissues. Finally one patient died in the hospital due to pulmonary embolism. Recurrences occurred after a mean of 8 months in patients undergone extended cholecystec-



tomy and it was 30 months for patients undergone simple cholecystectomy. No scar or port - site recurrences occurred in our patients.

As regard survival, it was a mean of 8 months in patients with advanced gall bladder carcinoma

& 21 months for those undergone extended cholecystectomy but for patients with incidental gall bladder carcinoma after laparoscopic cholecystectomies, the mean survival was 43 months. Finally the 5 year survival for patients with gall bladder carcinoma in our center was zero percent.

**Table 1:** Gastrointestinal Malignancies in Gastroenterology Surgical Center (1985-2007) (4245 Cases ).

1. Colon & rectum	1125	26.7 %
2. HCC	1000	23.8 %
3. Pancreas	840	20 %
4. Stomach	550	13
5. Cholangiocarcinoma	380	9
6. Esophagus	215	5.1
7. Abdominal Lymphoma	70	1.7
8. Gall bladder	55	1.4

**Table 2:** Treatment options.

Conservative treatment	15(27%)
Extended cholecystectomy	14(25%)
Right hepatectomy	12(23%)
Laparoscopic cholecystectomy	12( 23%)
Extended cholecystectomy + right colectomy	1(0.01%)
Extended cholecystectomy + whipple op.	1(0.01%)

### **Discussion**

Carcinoma of the gall bladder is the most common malignancy of the biliary tract and fifth most common cancer of the gastrointestinal tract and its incidence increases with age (Misra et al., 2003). In our study gall bladder carcinoma represented the 6th most common cancer after colorectal, hepatic, pancreatic, gastric and esophageal tumours.

Advances made in the management of other gastro - intestinal tumours have not extended to gall bladder cancer. Early diagnosis and late palliation are difficult. Clinical diagnosis of gall bladder cancer is a difficult task. In some patients the only complaints that suggest malignant disease are weight loss and anorexia. Others may present with a complication such as gastrointestinal haemorrhage.

Our patients presented with obstructed gall bladder, symptomatic cholelithiasis, obstructive Jaundice & gastrointestinal haemorrhage.

Cholelthiasis was present in

45% of our patients in the present series which is lower when compared to other series. The examination of choice in patients with biliary tract symptoms is ultrasonography, however, this fails to identify gall bladder cancer in early stages and it is difficult to differentiate between gall bladder cancer and cholecystitis because thickening of gall bladder wall is a feature of both diseases (Kapoor & Benjamin, 1998). Gall bladder carcinoma was not diagnosed preoperatively in any of our cases and indications for surgery were symptomatic cholelithiasis, obstructed gall bladder, obstructive Jaundice and gastrointestinal bleeding.

Only in cases of advanced disease can ultrasonography show a loss of the interface between gall bladder and the liver (sign of tumour invasion), lymph nodes, dilated bile ducts and ascites, but it fails to stage the disease. CT & MRI can accurately detect gall bladder abnormalities and assess extent of the disease (Kumar & Aggarwal, 1994). Today, more than 90% of cholecystectomies are performed laparoscopically and

consequently the number of incidental gall bladder cancer discovered after laparoscopic cholecystectomy has increased. In our center we did 4.000 cases laparoscopically and discovered 12 patients had gall bladder carcinoma by postoperative histopathology (done routinely for all cases). Fortunately the tumours did not penetrate the muscle layer in all cases so, simple laparoscopic cholecystectomy was sufficient and there was no need for reexploration.

The incidence of port-site recurrence is reported to be as high as 17% and the use of a retrieval bag seems not to be useful in preventing this complication. The role prophylactic excision or irradiation of port-sites is uncertain (Pearlstone et al., 1998). We did not perform a routine excision of port-site or to use endobag (except in some cases) Just to prevent rupture of the gall bladder and bile spillage during extraction and consequently wound infection. In our series no port-site recurrences occurred.

Wide cholecystectomy is the method of therapeutic choice in

treating the tumour that penetrates the lamina propria of the musculature since metastases develop in the lymph nodes in 60 - 80% of cases (Bach et al., 1998). However some studies (Cunningham et al., 2002). demonstrated that even after a seemingly radical local excision, residues occur comparatively soon. The liver resection has not led to better results (Bach et al., 1998).

The three-year survival after wide cholecystectomy is 91% compared to 28% after simple cholecystectomy (Cunningham et al., 2002). but in our study survival was 8 months for patients with advanced gall bladder cancer and 21 months for those undergone extended cholecystectomy and 43 months after simple cholecystectomy for incidental gall bladder carcinoma. Five-year survival in our study is zero percent. In other series the 5-year survival is <5% (Klamer & Max, 1983).

### **Conclusion**

Gall bladder carcinoma is not uncommon and in spite of modern diagnostic procedures, early diag-

nosis is rare & the prognosis up till now is not good.

In view of the dismal outlook for this disease, prevention would be important goal, treating symptomatic cholelithiasis, gall bladder polyps more than 1cm and careful examination of the resected gall bladder in the operating room with frozen section for any suspicious lesion.

Simple cholecystectomy is sufficient for early carcinoma even laparoscopic & re-surgery is only needed if the tumour passed the muscle layer. The surgeon alone should open each extricated gall bladder and examine the wall and it's interior. Finally postoperative histopathology is mandatory.

### References

**Bach A. M., Loring L. A., Hann L. E., et al., (1998)** : Gall bladder cancer : can ultrasonography evaluate extent of disease? J. Ultrasound Med.; 17 : 303-9.

**Batra Y., Pal S., Dutta U., et al., (2005)** : "gall bladder cancer in India: a dismal picture", J. Gas-

troenterol. Hepatol.; 20(2): pp.309-314.

**Bismuth H. and Malt R. (1979)** : "carcinoma of the biliary tract", N. Engl. J. Med.; 301: pp. 704-706.

**Cunningham C. C., Zibari G. B. and Johnston L. W. (2002)** : Primary carcinoma of the gall bladder: a review of our experience. J La state Med soc; 154(4): 196-9.

**Fernando M. G., Juan G., Diaz et al., (2004)** : "Strategies for the surgical treatment of gall bladder cancer", Rev. Med. Chile.

**Fujita T., Fukuda K., Ohmura Y., et al., (2005)** : "Long term survival of a patient with advanced adenosquamous carcinoma of the gall bladder after radical resection", J. Hepatobiliary Pancreat. Surg.; 12(2): pp. 147-150.

**Huguet K. L., Hughes G. B. and Hewitt W. R. (2005)** : "gall bladder carcinoma: a case report and literature review", J. Gastrointest. Surg.; 9(6): pp. 818-821.

**Iqbal M., Rashid K., Islam Z. and Khan A. (2003)** : "Incidental diagnosis of early carcinoma Gall Bladder in chronic cholecystitis with cholelithiasis", J. Surg. Pakistan; 8(2): pp. 23-25.

**Kapoor V. K. and Benjamin I. S. (1997)** : Biliary malignancies. IN: Pitt HA, ed Bailliere\_s Gastroenterology: The biliary tract. London: Bailliere Tindall: 801-836.

**Kapoor V. K. and Benjamin I. S. (1998)** : Resectional surgery for gall bladder carcinoma. Br J Surg; 85: 145-146.

**Klamer T. W. and Max M. H. (1983)** : Cancer of the Gallbladder. Surg Gynecol obstet; 156: 641-645.

**Kumar A. and Aggarwal S. (1994)** : Carcinoma of the gall bladder: CT finding in 50 cases. Abdom. Imaging; 19: 304-8.

**Levy A. D., Murakata L. A. and Rohrmann C. A. (2001)** : Gallbladder carcinoma: radiologic-pathologic correlation. Radiographics; 21: 295-314.

**Memon M. A., Anwar S., Shiwani M. H. and Memon M. (2005)** : "gall bladder carcinoma: A retrospective analysis of twenty-two years experience of single teaching hospital", Int. Semin. Surg. Oncol.; 2: p. 6.

**Misra S., Chaturvedi A., Misra N. C. and Sharma I. D. (2003)** : Carcinoma of the gall bladder. Lancet Oncol.; 2: 167-76.

Pal A, Sharma S K, "Ultrasonographic evaluation of carcinoma of the gall bladder", Nat. Med. J. India (1990); 3: pp. 167-170.

**Pearlstone D. B., Curley S. A. and Feig B. W. (1998)** : The management of gall bladder cancer: before, during, and after laparoscopic cholecystectomy. Semin. Laparosc. Surg.; 5:121-8.

**Piehler J. M. and Crichlow R. W. (1978)** : Primary carcinoma of the gallbladder. Surg Gynecol Obstet; 147: 929-42.

**Principe A., Lugaresi M. L., Lords R. G., et al., (1997)** : "Unsuspected carcinoma of gall bladder: case report of trocar-site me-

tastasis following laparoscopic cholecystectomy" *Hepatogastroenterology*; 44(16): pp. 990-993.

**Sagoh T., Itoh K., Togashi K., et al., (1990)** : Gallbladder carcinoma: evaluation with MR imaging. *Radiology*; 174: 131-6.

**Toda K., Souda S., Yoshikawa**

**Y., et al., (1995)** : "Significance of laparoscopic excisional biopsy for polypoidal lesion of the gall bladder", *Surg. Laparosc. Endosc.*; 5:pp. 267-271.

**Varshney S., Buttirini G. and Gupta R. (2002)** : Incidental carcinoma of the gallbladder. *Eur. J. Surg. Oncol.*; 28: 4-10.

REPRINT

# **BENHA MEDICAL JOURNAL**

**GALL BLADDER CARCINOMA :  
A SINGLE CENTER EXPERIENCE**

**Mohamed El-Hemaly MD**

**Published by  
Benha Faculty of Medicine**

*Volume 26 Number 3  
Sept. 2009*

## **ALLODERM FUNCTIONALITY VERSUS TEMPORALIS FASCIA IN LARGE TYMPANIC MEMBRANE PERFORATION**

**Mohamed Abdul. M. Eltoukhy MD**

*Department of ENT, Benha Teaching Hospital, Egypt*

### **Abstract**

**Objective:** is to evaluate Alloderm functionality, as a graft material for large tympanic membrane perforation that healed with a trilaminar membrane, compared with temporalis fascia, as a graft material that healed without middle fibrous layer. **Study design:** prospective, open trial. **Methods:** 20 consecutive patients, complaining of chronic suppurative otitis media, large central/subtotal perforation, with hearing loss, aiming to perform type 1 tympanoplasty, were divided into 2 groups randomly and equally. In Group (A), Alloderm (Acellular Human Dermal Allograft) was used as a graft material, while in Group (T), Temporalis fascia was used. Pre-and post operative audiological evaluation for air-bone gaps (ABG), at four frequencies were done, and up to 4 months follow up as well as pneumatoscopy and immitancemetry. **Setting:** Benha Teaching Hospital. Analysis of the results was performed by Student's paired t test. The level of significance was set at 5%. **Results:** Complete tympanic membrane closure was obtained in 9 out of 10 cases (90%) in Group (A) within 2-3weeks post-operative, compared with 7 cases showed closure of the tympanic membrane within 3-5 weeks post-operative and one case, had an otorrhea that respond to local medical treatment within one month in Group (T) with a total success rate 80%. No variables demonstrated statistical significance between both groups as regard tympanic membrane closure. As regard functionality assessment, Temporalis fascia taking, showed a more transparent new tympanic membrane, and more responding to Siegle's maneuver. Air-bone gap closure was better in (T) group. Taking of Alloderm graft was faster than that with temporalis fascia ( $p < 0.005$ ). Both groups showed low normal compliance. **Conclusion:** Temporalis fascia showed better mechanical properties than Alloderm as



*regard pneumatoscopic examination, with more success in air-bone gap closure. No statistical significance in graft taking and hearing results between both materials, were reported. However, Alloderm appeared to be an ideal substitute for grafting of the tympanic membrane. It is easy of tissue graft handling, ready-to use storable packaging with no donor site morbidity.*

### **Introduction**

Tympanic membrane (TM) perforation arise from chronic middle ear infections, trauma, or replacement of ventilation tubes. Acute tympanic membrane perforations begin healing after 12 hours, when squamous cells at the edge of the perforation begin to proliferate (Dunlap & Schuknecht, 1958).

Many materials are used to repair TM perforation, include: split thickness skin graft, vein graft, sclera, perichondrium, temporalis fascia, cartilage inlay, cartilage-perichondrium composite, and fat (Glasscock & Konok, 1977). Temporalis fascia and perichondrium are 2 of the more commonly used grafting materials and successful grafting can be accomplished in over 90% of cases when the proper technique is used (Sheehy, 1984).

Alloderm (Life Cell Corp., the

Worldlands, TX), an a cellular human dermal matrix, that is processed from human cadaveric skin, is a new biomaterial that serves as a connective tissue matrix, providing soft tissue support and coverage that become integrated into the implanted bed (Wainwright et al. 1996). Alloderm is obtained from an approved tissue bank. Donors are screened for Human Immunodeficiency Virus (HIV) types 1 and 2, human T-lymphotrophic virus type 1, hepatitis B and C; and syphilis (Harper & Livesy, 1998). The tissue is processed to remove the epithelial layer and all cellular elements of the dermis. Using a special freeze-drying technique preserves the integrity of the matrix protein of the Alloderm graft which acts as a scaffold for fibroblast and endothelial cell ingrowth, with subsequent revascularization and re-epithelialization. This reduces inflammatory tissue reaction (Benecke, 2001).

Alloderm has been successfully used as a soft tissue graft for cosmetic and reconstructive surgery (Jones et al., 1996). Downey et al. (2003), investigated Alloderm (0.3 mm thick versus autologous fascia graft for the closure of 30% to 40% dry tympanic perforations in Chinchillas model, with a statistically significant decrease in operative time shown in the Alloderm group than in the fascia group. In addition, neovascularization was present in 80% of the Alloderm group compared with 44% of the fascia one. Douglas (2001), demonstrated a trilaminar healing process with a thick fibrous layer with Alloderm graft in animal model, while Mc Feely et al. (2000), proved a bilaminar membrane with autologous fascia in Chinchillas model.

Comparative studies between Alloderm and temporalis fascia as a grafting materials in adults (Fishman et al. 2005), and in children (Philip et al. 2006), concluded that there was no statistical significance in closure rate when grafting with Alloderm versus temporalis fascia in both studies. The purpose of this study was to

compare the efficiency of Alloderm functionality versus temporalis fascia as a graft material in patients with large tympanic membrane perforation.

### **Patients and Methods**

Adult patients of both sexes (age ranged from 20 through 43y. with a mean of  $28.8 \pm 5.09$  years), 12 were males and 8 were females, who had suffering from chronic suppurative otitis media with moderate conductive hearing loss and a dry large central / subtotal perforations of the tympanic membrane. The ossicular chain must be intact as indicated by the pure tone, that favor applying type 1- tympanoplasty. Pre- and post-operative audiological assessment included pure tone average (PTA) obtained at 500, 1000, 2000, 4000Hz and air-bone gap (ABG), speech reception threshold (SRT), and immitancemetry, using Jerger classification (1970); were reported up to 4 months follow up as well as any complications. Pneumatocopy to assess the vibrations of the heald graft was taken post-operatively using Siegle's pneumatic speculum which allows magnification

through an obliquely-set lens and mobility of the drumhead can be determined by alternate compression and release of the bulb (Simon & Bernard, 1982). All patients were divided consecutively, randomly and equally into 2 groups. Group (A), Alloderm was used as a graft material, while in Group (T), autologous temporalis fascia was used. The outcome criteria are : closure of the perforation, post-operative hearing gain, and complications (otorrhea, residual perforation, and failure), and mobility of the drum. Surgical technique : Special thin-sectioned pieces of Alloderm (thickness = 0.3 mm) were used. The graft was rehydrated in sterile physiological saline with two washes for at least 5 minutes each, but no more than 4 hours prior to use. Under local anesthesia, the perforation was trimmed. Tympanomeatal flap 5-6mm from the annulus was elevated. The middle ear cavity was filled with Gelfoam to support the overlying graft material. In Group (A), a small piece of Alloderm, approximately 1.5 times the size of the perforation was trimmed and placed to overlap the medial surface of the drum by at least 2-

3mm. A slit is made in the superior aspect of the Alloderm to allow the malleus handle to come lateral to the graft inferior to the insertion of the tensor tympani tendon, to ensure that any remaining squamous epithelium on the malleus handle remains lateral to the neo-tympanic membrane. In Group (T), autologous temporalis fascia was taken through a high post-auricular incision, under local anesthesia. The fascia graft, was placed medial to the drum mucosa with an upper radial slit in the fascia to incorporate the handle of malleus. Gelfoam soaked in antibiotic solution was placed in the canal and small cotton balls were placed in the meatus. Post-operative antibiotic for one week was prescribed.

### **Results**

In Group (A), where Alloderm graft material was used, all 10 patients tolerated the procedure without difficulty or surgical complications. Closure of the perforation, was achieved in 9 cases out of 10 (90% success rate) within 2-3 weeks post-operative. Air-bone gap was closed to less than 17 dB in 90% of the group.

In Group (T), 8 cases out of 10, had closed perforation (80% success rate) within 3-5 weeks post-operative. Air-bone gap was closed to less than 12 dB in this group. Although the early perforation closure rate was higher with Allo-derm grafting (90%) compared with temporalis fascia (80%), yet, this finding did not attain statistical significance ( $P>0.05$ ). There were significant relative improvements in pure tone average and air-bone gap within (T) Group compared with that obtained within (A) Group. There was a trend toward improvement in speech reception threshold with surgery in both groups, however, this finding did not attain significance (ANOVA,  $P> 0.05$ ). Sieglization of the new tympanic membrane showed a better vibration of the TM in (T) group than in (A) one. Acoustic impedance tympanometry showed low normal compliance in both groups.

### **Discussion**

The primary goal of repairing a tympanic membrane perforation is to prevent otitis media and to restore hearing. An ideal graft material for myringoplasty would be

one that is permanent and that promotes migration of epithelium from the advancing edge of the perforation both on the lateral and medial surfaces of the tympanic membrane (Saadat et al. 2001).

The normal TM consists of three layers, including a surface epithelium, a middle fibrous lamina propria, and an internal mucosa. In most cases of acute TM perforation, the membrane heals spontaneously in a three-staged process. The initial stage involves hemostasis and inflammation. In the next stage, the epidermal layer first close the perforation, followed by the inner mucosal layer. The fibrous lamina propria is the last layer to regenerate across the perforation and it often fails to do so, leaving a dimeric layer with only loose disorganized fibers between layers (Gladstone et al. 1995).

The most commonly used autograft is the temporalis fascia (Storrs, 1961), which provides a thin, pliable, and sturdy graft material. In addition, the temporalis fascia has the advantage of being harvested at the surgical site as

the affected ear. Although, Vartiainen et al. (1993), had a success rate of 95% with temporalis fascia in closing TM perforation, compared with our result in Group (T) 80%, yet, temporalis fascia is limited by the donor site morbidity, and the extra time consumed.

Youssef (1999), has described the use of Alloderm for tympanoplasty with a successful outcome of 27 cases out of 30. Bencke (2001), in a retrospective study, compared 2 series of tympanoplasty with temporalis fascia and Alloderm and he had 100% success rate of graft taking in both groups with no statistically significant difference between the fascia and Alloderm hearing results. Our results showed 90% success rate of graft taking with Alloderm, compared with 80% in temporalis fascia group which had an added operative time and morbidity. Fishman et al. (2005), concluded that there was no statistical significance in closure rate when grafting with Alloderm versus temporalis fascia and there was a statistically significant shortened healing time observed with Allo-

derm. Alloderm is stronger than fascia (Downey et al., 2003). Saadat et al. (2001), described the successful closure 6 of 7 dry central 10% to 30% TM perforation by using an office-based transcanal myringoplasty technique with Alloderm. All showed improvement in hearing, and non showed rejection of the graft at 1-year follow up.

Alloderm has the advantages of being readily available, relatively inexpensive, easy to work with, has predilection for host tissue integration, with no evidence of immune rejection or disease transmission (Mc Feely et al. 2000). Alloderm grafts consistently demonstrated a trilaminar healing process with a thick fibrous layer undergoing varying degrees of host tissue integration surrounded by squamous epithelium on one side and mucosa on the other (Douglas, 2001). This may explain the lower vibratory properties of Alloderm compared with temporalis fascia. Further study including laser Doppler vibrometry (Shinsei & Richard, 1997) and laser Doppler velocimetry (Kempe et al. 1997) may be needed to test the acousti-

cal properties of both materials, adding to the functionality assessment.

### Conclusion

Alloderm graft taking had the incidence of 90% success rate compared with 80% in temporalis fascia group, but without statistical significance. Temporalis fascia grafting forming neo-membrane, showed better vibration than that obtained with Alloderm, reflecting better hearing and, functionality. Both groups showed normal middle ear pressure and low normal compliance in immittanceometry. The significant improvement of air-bone gap closure within group (T), added to its positive score functionality. However, Alloderm deserve to be used in revision cases to shorten the operative time and to reduce donor site morbidity.

### References

**Benecke J. E. jr. (2001):** Tympanic membrane grafting with Alloderm. *Laryngoscope* 111 : 1525- 7.

**Douglas W. Laidlaw, Peter D. Costantino, Satish Govindaraj,**

**David H. Hiltzik (2001):** Tympanic membrane repair with a dermal allograft. *Laryngoscope* 111: Apr; 702-7.

**Downey T. G., Champeaux A. L. and Silva A. B. (2003):** Alloderm tympanoplasty of tympanic membrane perforations. *Am J Otolaryngol.* 24 (1): 6-13.

**Dunlap A. M. and Schuknecht H. F. (1958):** Closure of perforations of tympanic membrane. *Laryngoscope* 68: 501-7.

**Fishman A. J., Marrinon M. S., Hung T. C. and Kanowitz S. J. (2005):** Total tympanic membrane reconstruction: Alloderm versus Temporalis fascia. *Otolaryngology Head Neck Surg.* Jun vol 132 No. (6): 906-15.

**Gladstone H. B., Jakler R. K. and Varar K. (1995):** Tympanic membrane wound healing: an overview. *Otolaryngol Clin North Am.* 28: 913-32.

**Glasscock M. E. and Kano K. M. M. (1977):** Tympanoplasty –a chronological history. *Otolaryngol Clin North Am.*10: 469-77.

- Goeverts P. J., Jacob W. A. and Marquet J. (1988):** Histological study of the thin replacement membrane of human tympanic perforations. *Acta Otolaryngol.* 105: 297-302.
- Harber J. R. and Livesy S. A. (1998):** Soft tissue regeneration using an acellular dermal matrix as a natural scaffold. In Savag LM, ed. *Bioengineering of skin substitutes.* Southborough MA: International Business Communications Inc. p: 19-41.
- Jerger J. (1970):** Clinical experience with impedance audiometry. *Arch Otolaryngol.* 92: 311-24.
- Jones F. R., Schwartz B. M. and Silverstein P. (1996):** Use of a nonimmunogenic acellular dermal allograft for soft tissue augmentation. *Aesthetic Surgery Quarterly;* 16: 196-201.
- Kempe C., Stasche N., Bar-mann M., Foth H., Baker-Schreyer A. and Hormann K. (1997):** Laser Doppler velocimetry-a method supporting differential diagnosis of middle and inner ear disorders. In: *Middle ear me-*
- chanics in research and otosurgery,* ed. By: Karl-Bernd Huttenbrink, published by: Bibliothek der HNO-Universitätsklinik.P: 95-99.
- Mc Feely W. J., Bojrab D. I. and Kartush J. M. (2000):** Tympanic membrane perforation repair using Alloderm. *Otolaryngol Head Neck Surg.* 123: 17-21.
- Philip L., Evan J. P. and Black C. P. (2006):** Lateral graft type 1 tympanoplasty for tympanic membrane reconstruction in children. *International J of Pediatric otolaryngol.* 70: 1423-29.
- Saadat D., Matthew N. G., Satish Vadapalli and Uttam K. Sinha (2001):** Office Myringoplasty with Alloderm. *Laryngoscope* 111: Jan; 181-84.
- Sheehy J. L. (1984):** Surgery of chronic otitis media. In: English GM, ed. *Otolaryngology,* vol 19. Philadelphia: Harper & Row Publishers: 1-86.
- Shinsei N. and Richard L. G. (1997):** Measurement of tympanic membrane vibration in 99 human

ears. In: Middle ear mechanics in research and otosurgery, ed.by: Karl-Bernd Huttenbrink, published by: Bibliothek der HNO-Universitätsklinik. P: 91-94.

**Simon H. and Bernard H. C. (1982):** Examination equipment, in: Diseases of the Nose, Throat and ear, twelfth ed. The English Language Book Society and Churchill Livingstone, p: 2.

**Storrs L. A. (1961):** Myringoplasty with the use of fascial grafts. Arch Otolaryngol. 74: 45-49 .

**Vartiainen E. and Nuutinen J. (1993):** Success and Pitfalls in myringoplasty : Follow up study of 404 cases. Am J Otol. 4 : 301-5.

**Wainwright D. J., Madden M. and Luterman A. (1996):** Clinical evaluation of an acellular allograft dermal matrix in full thickness burns. J Burn Care Rehabil. 17: 124-36.

**Youssef A. M. (1999):** Use of acellular human dermal allograft in tympanoplasty. Laryngoscope 109: 1832-33.



REPRINT

# **BENHA MEDICAL JOURNAL**

**ALLODERM FUNCTIONALITY  
VERSUS TEMPORALIS FASCIA IN  
LARGE TYMPANIC MEMBRANE  
PERFORATION**

**Mohamed Abdul. M. Eltoukhy MD**

**Published by  
Benha Faculty of Medicine**

*Volume 26 Number 3  
Sept. 2009*

## DEEP VEIN THROMBOSIS AFTER VARICOSE VEIN SURGERY. IS IT WORTHWHILE ?

**Abdel Salam F. Megahed and Ahmed A. Abdel Razik MD**

*Departments of Surgery (Vascular Surgery Unit) & Diagnostic Radiology\**

*Faculty of Medicine, Mansoura University, Egypt*

### Abstract

**Background:** Deep vein thrombosis (DVT) is an uncommon but serious complication of varicose vein surgery and can very occasionally lead to detachment of blood clot from veins in the leg and pelvis which then migrates to the heart and lungs (pulmonary embolus). A major pulmonary embolus can result in sudden cardiac arrest and death (Libertiny et al., 2000). Prospective duplex screening identifies DVT in 5% of patients compared to clinical incidence of approximately 1%. Universal duplex screening is costly, and the benefits of diagnosing subclinical DVT are unproven. This study evaluate whether a policy of using clinical indication (leg swelling) to determine the need for duplex imaging is safe after varicose vein surgery. **Methods:** Patients undergoing varicose vein surgery in a 2-years period were studied. Postoperative venous duplex imaging was performed if leg swelling occurred within 6 weeks of surgery. Long-term follow-up was performed to detect any missed occurrence of clinical DVT or pulmonary embolization. **Results:** A total of 77 patients had 97 leg operations with 20 bilateral procedures, 9 patients with leg swelling underwent duplex imaging, 3 of whom had duplex-proven DVT. No patient without early clinical signs went on to develop clinical DVT on long-term follow-up. **Conclusion:** Using of clinical signs as a triage for duplex imaging detected all clinically significant DVTs.

### Introduction

Varicose vein surgery is a common procedure with overall complication rates of up to 18% may

follow varicose vein surgery (Crichley et al., 1997); however, most patients do not develop serious clinical sequelae. Deep vein

thrombosis (DVT), with its inherent risk of pulmonary embolization (PE), is the most serious complication. Reported rates of DVT following varicose vein surgery vary with the method of assessment. The incidence of clinically diagnosed DVT was 0.15% to 0.50% (Crichley et al., 1997 and Haggmuller, 1992) compared with a recent prospective duplex diagnosed rate of 5.0% (van Rij et al., 2004). Clinical diagnosis of DVT may therefore underestimate the true DVT incidence and may potentially expose patients with sub-clinical DVT to the possibility of developing such complications because anticoagulation therapy is not applied. However, universal duplex screening detects significant numbers of calf vein DVT, thrombi in venous channels of the calf musculature, that may have no clinical relevance and thus lead to over-treatment (Righini et al., 2006).

#### **Aim of the work**

Our study was to assess whether a clinical sign (leg swelling) could be safely used to triage patients into a high-risk group for duplex imaging.

#### **Patients and Methods**

Patients underwent varicose vein surgery between January 2007 and December 2008 were included in the study. Most of the patients had a single preoperative assessment, and all underwent preoperative duplex imaging, the finding of which directed the actual operative procedure performed. During preoperative duplex screening, no patients were found to have asymptomatic or occult lower limb DVT. Surgery involved spinal or general anaesthesia, ligation at the sapheno-femoral and/or saphenopopliteal junction with stripping of incompetent trunks and phlebectomies. All patients were managed in compression bandaging for 48 hours and graduated compression stocking for 2 weeks. Operations were usually performed as day cases with early mobilization. Inpatients treatment was reserved for the elderly, and those with significant co-morbidity. A single preoperative dose of low molecular weight (L.M.W) heparin was given to inpatients and to day patients who were considered to be at increased risk of thrombosis and continued for seven days postoperative.

All patients were reviewed approximately 6 weeks after surgery or sooner, but patients were told and had access to fast-track clinic appointments if they noted any postoperative problems. Patients presenting with persistent leg swelling (change in leg or foot size compared with other leg or tightness of socks) with or without calf tenderness underwent postoperative duplex imaging. Any degree of swelling was an indication for duplex imaging. Pain alone was not used as an indication for scanning. Clinical DVT was defined, in line with Wells et al. (1998), as an increase in calf circumference of >3cm.

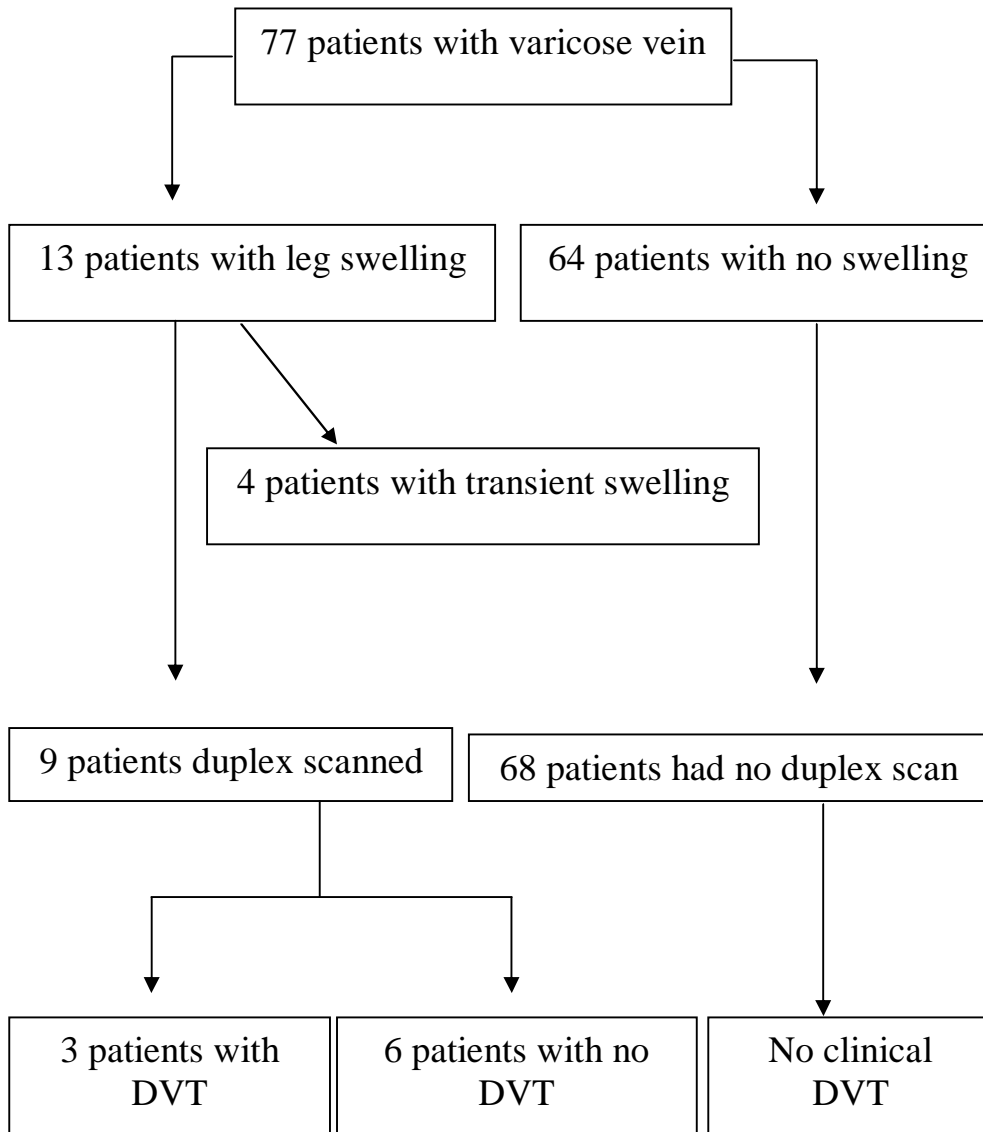
Long-term follow-up was performed and the patients were asked at their planned follow-up if they had any reason to consult about a problem with their leg since their last follow-up clinic appointment.

The sensitivity, specificity and predictive value of using leg swelling as a predictor of clinically significant DVT were calculated.

## Results

A total of 77 patients underwent varicose vein surgery in 97 legs (20 bilateral procedures) with 73% as a day case. All 20 bilateral procedures were performed simultaneously. Altogether, 17 patients had bilateral long saphenous vein surgery; in the remaining 3 patients, surgery was performed to the long saphenous venous system in one leg and short saphenous venous system in the contralateral leg. These patients had a mean age of 47.3 year (range 18-67 years) and the female/male ratio was 2.3:1.0. Most (77.9%) legs underwent long saphenous vein surgery, 12.3% short saphenous vein surgery; and 9.8% had combined short and long saphenous vein procedures. In total 83.7% leg underwent primary procedures, and 16.3% had surgery for recurrent varicose veins.

A total of 13 patients reported leg swelling with or without pain during the postoperative period (Fig. 1). Four patients who had transient swelling with full resolution at their 6-week follow-up review and were not duplex-imaged.



**Fig. (1):** Flow chart showing patients with and without leg swelling, those undergoing duplex scanning, and those with and without deep vein thrombosis

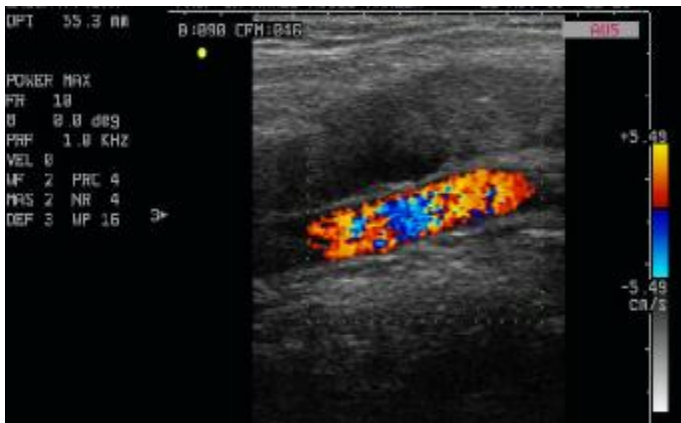
A total of 9 patients with limb swelling were duplex-imaged. Three had duplex-proven DVT as follows: one 63-years old patient developed DVT 21 days after primary left sapheno-femoral surgery, and two patients (aged 52 and 37 years, respectively) developed unilateral DVT 27 and 33 days, respectively, after bilateral sapheno-femoral surgery.

The DVTs of two patients were limited to tibial veins and one patient developed a popliteal vein DVT (Fig. 2 & 3).

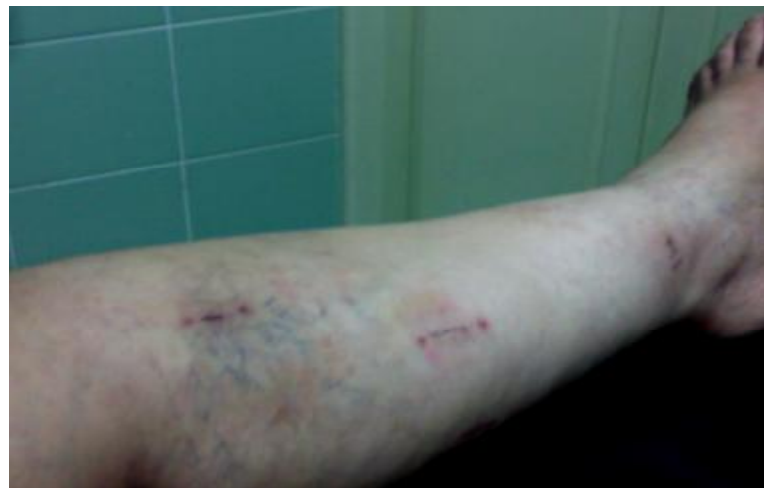Based on the results of our

study, it seems that patients undergoing bilateral varicose vein surgery are at greater risk of developing postoperative DVT: two of the patients with confirmed DVTs in our study group underwent this type of surgery. Furthermore, two of the patients were above the age of 50 years.

The sensitivity and specificity of using leg swelling to predict clinical DVT were 100% and 91%, respectively. The positive predictive value of leg swelling for DVT was 19%, and the negative predictive value was 100%.



**Fig. (2):** Thrombosis of the popliteal vein.



**Fig. (3):** Photo for the patient who had popliteal vein thrombosis.

### **Discussion**

The true incidence of clinically relevant DVT after varicose vein surgery is difficult to determine (Gilles et al., 1996). Clinically detected incidence of 0.15% to 0.5% have been reported (Crichley et al., 1997 and Hagmuller, 1992). However, clinical methods of DVT detection were unreliable, and up to 30% of DVTs go unrecognized (Van Rij et al., 2004 and Enoch et al., 2003).

Crichley et al. recommend enoxaparin 40 mg daily for one week given to all patients with a previous history of thrombo-embolic disease, starting the day before operation (Crichley et al., 1997).

van Rij et al. have reported a DVT rate of 5.3% detected by universal duplex imaging after varicose vein surgery; 3.2% of the thrombi were small calf vein DVTs, and only 2.1% of patients developed clinical symptoms (van Rij et al., 2004).

Critchley et al. reported low incidence of thrombo-embolic complication, suggesting that the risk of DVT in varicose vein surgery is

about 1:200 and the risk of pulmonary embolism is 1:600 (Crichley et al., 1997).

Hagmuller, suggest a much lower incidence a 0.15% for deep vein thrombosis and 0.06% for pulmonary embolism (Hagmuller, 1992).

The clinical importance of duplex-detected subclinical calf vein DVT remain unproven. This is more so because the natural history of isolated calf vein DVT is that they have a low risk of proximal propagation, and clot lysis is seen in 88% of cases by 3 months (Masuda et al., 1998). McLafferty et al., have shown that there is no significant long-term clinical sequelae following isolated infragenicular vein DVT (McLafferty et al., 1998).

In this study we have not commented on the incidence or development of post-phlebotic limb as a sequelae of varicose vein surgery. Previous studies have shown that long-term serial duplex imaging, not patient symptoms, is required to detect deep vein insufficiency and a post-phlebotic limb (Yamaki

& Nozaki, 2005). Development of post-phlebotic limb is seen in patients who do not recanalize veins leading to valvular incompetence (O'Shaughnessy & Fitzgerald, 1997). In addition post-phlebotic limb is more commonly seen in proximal vein DVT and multisegment venous disease (Yamaki & Nozaki, 2005).

Routine universal postoperative duplex scanning after varicose vein surgery is not practical. We have shown that using leg swelling to select patients with possible DVT for duplex scanning is safe and has a high predictive value for clinically relevant DVTs in patients who have undergoing varicose vein surgery.

### References

**Crichley G., Handa A., Maw A., et al., (1997)** : Complications of varicose vein surgery. *Am R Coll Surg Engl* 79 : 105-110.

**Enoch S., Woon E. and Blair S. D. (2003)** : Thromboprophylaxis can be omitted in selected patients undergoing varicose vein

surgery and hernia repair. *Br. J. Surg* 90:818-820.

**Gilles T. E., Ruckley C. V. and Nixon S. J. (1996)** : Still missing the boat with fatal pulmonary embolism. *Br J Surg* 83:1394-1395.

**Hagmuller G. W. (1992)** : Complications in surgery of varicose veins. *Langenbecks Arch Chir Suppl Kongressbd* 470 - 474.

**Libertiny G., Perkins J. M. T., Magee T. R., et al., (2000)** : Varicose vein surgery. *European Journal of Vascular and Endovascular Surgery* 20:386-9.

**MacDonald P. S., Kahn S. R., Miller N., et al., (2003)** : Short term natural history of isolated gastrocnemius and soleal vein thrombosis. *J Vasc Surg* 37:523-527.

**Masuda E. M., Kessler D. M., Kistner R. L., et al., (1998)** : The natural history of calf vein thrombolysis of thrombi and development of reflux. *J Vasc Surg* 28:67-73.



**McLafferty R. B., Moneta G. L., Pussman M. A., et al., (1998)** : Late clinical and haemodynamic sequelae of isolated calf vein thrombosis. *J Vasc Surg* 27:50-56.

**O'Shaughnessy A. M. and Fitzgerald D. E. (1997)** : Natural history of proximal deep vein thrombosis assessed by duplex ultrasound. *Int Angiol* 16 : 45-49.

**Righini M., Paris S., Le Gal G., et al., (2006)** : Clinical relevance of distal deep vein thrombosis : review of literature data. *Thromb Haemost* 95 : 56 - 64.

**Van Rij A. M., Chai J., Hill G. B., et al., (2004)** : Incidence of deep vein thrombosis after varicose vein surgery. *Br J Surg* 91:1582-1585.

**Wells P. S., Hirsh J., Anderson D. R., et al., (1998)** : A simple clinical model for the diagnosis of deep vein thrombosis combined with impedance plethysmography: potential for an improvement in the diagnostic process. *J Intern Med* 243:15-23.

**Yamaki T. and Nozaki M. (2005)** : Patterns of venous insufficiency after an acute deep vein thrombosis. *J Am Coll Surg* 201: 231-238.

REPRINT

# BENHA MEDICAL JOURNAL

**DEEP VEIN THROMBOSIS AFTER  
VARICOSE VEIN SURGERY.  
IS IT WORTHWHILE ?**

**Abdel Salam F. Megahed and Ahmed A. Abdel Razik MD**

**Published by  
Benha Faculty of Medicine**

*Volume 26 Number 3  
Sept. 2009*

## **ROLE OF MULTI-DETECTOR CT ANGIOGRAPHY IN MANAGEMENT OF DIABETIC PATIENTS WITH PERIPHERAL ARTERIAL OCCLUSIVE DISEASE**

**Ashraf Abdel El-Rahman MD, Abdel Salam Megahed MD  
and Manal El-Tarshouby MD**

*Departments Diagnostic Radiology, General Surgery (Vascular Surgery Unit) &  
Internal Medicine (Diabetes, Endocrinology Unit), Faculty of Medicine  
Mansoura University, Egypt*

### **Abstract**

**Background:** *The diagnostic standard for evaluation of peripheral arterial occlusive disease (PAOD) is digital subtraction angiography but this technique has several disadvantages such as invasiveness and high cost. Because of these disadvantages and the increasing incidence of PAOD, a non-invasive diagnostic alternative to angiography is in high demand, sparing catheter based angiography for therapeutic intervention rather than purely diagnostic studies. The two most important non-invasive method for evaluation of PAOD are MR angiography and CT angiography. CT angiography has improved fastly with the clinical availability of multi-detector CT scan.* **Methods:** *A total number of 30 diabetic patients with PAOD were examined by 16 row multi-detector CT angiography. They were 22 male and 8 female, their aged ranged from 43-77 years and mean age of 62.5 years. All patients were examined using non ionic contrast media and automated bolus triggering technique.* **Results:** *Multi-detector CT angiography revealed grade I stenosis (0-10%), in 149 arterial segment and grade II stenosis (10-<50%), in 331 arterial segment, grade III stenosis (50-<99%) was seen in 155 arterial segment and complete occlusion was seen in 55 arterial segment. According to CT angiography finding, endovascular treatment was used in 8 patients, surgical procedures in 7 patients, combined surgical & endovascular procedures in 2 patients and conservative treatment in 13 patients.* **Conclusion:** *Multi-detector CT angiography makes it possible to evaluate short segmental stenosis accurately and permits evaluation of the vascular wall itself and can clearly depict the course of the vessel which is important in managment of patients with PAOD.*

---

### **Introduction**

Patients with peripheral artery disease who have significant, life-style-altering claudication or critical limb ischemia require some form of diagnostic imaging for the purpose of treatment planning (Josephs et al., 2008).

The diagnosis of peripheral arterial occlusive disease (PAOD) is usually made clinically on the basis of the medical history and ankle-brachial index. It is categorized on the basis of pain-free walking distance and the absence or presence of tissue loss. Stage I PAOD is asymptomatic. Intermittent claudication is classified as stage II. Stage IIa indicates a pain-free walking distance greater than 200 m; otherwise the disease is stage IIb. Stage III PAOD is characterized by rest pain. Ulcerations are classified as stage IV PAOD (Scherthaner et al., 2007).

The current imaging standard of reference for complete delineation of the peripheral vasculature is digital subtraction angiography (DSA) because it has high spatial and temporal resolution. However, it is hampered by

invasiveness and by exposure of the investigator and patient to ionizing radiation. It also is a time- and cost-consuming with one night of hospitalization or a minimal recovery period of at least 4 hours. Finally, digital subtraction angiography results only in luminograms, and thus information about plaque constituents and vessel surroundings cannot be acquired (Scherthaner et al., 2007).

A noninvasive alternative to digital subtraction angiography in evaluation of PAOD is in high demand. Sonography does not depict complete inflow (including the iliac arteries) or outflow (including the pedal arteries) for routine purposes because acquisition of a complete duplex angiogram is extremely time-consuming and investigator-dependent. Furthermore, there is a risk of missing lesions in patients with multiple stenoses. Finally, for postoperative surveillance of lower extremity venous bypass grafts, sonography often does not depict the actual site of stenosis (Scherthaner et al., 2007 and Willmann et al., 2005).

Computed tomographic (CT) angiography is increasingly used for noninvasive imaging of various vascular territories. The introduction of multi-detector row CT scanners has substantially improved CT angiography by offering increased volume coverage, decreased dose of contrast medium, decreased acquisition time, and improved spatial resolution for assessment of smaller arterial branches, including the aortoiliac and lower extremity arteries (Willmann et al., 2005).

Advantages of CTA over MRA include better patient acceptance with no claustrophobia or contraindications, speed of examination, better spatial resolution, less cost of equipment. MRA also cannot be used to evaluate the vascular wall for mural thickness or calcification, and metallic devices such as stents may cause artifacts that interfere with the evaluation of arteries. Disadvantages of CTA include image interference from calcified arteries and the need for potentially nephrotoxic contrast and radiation exposure (Josephs et al., 2008; Otal et al., 2004 and Quwendijk et al., 2005).

Multi-detector CT angiography (MDCT) has two advantages over digital subtraction angiography. First, eccentric stenosis can be evaluated accurately with the use of cross-sectional MDCT angiograms, whereas additional views, including oblique and lateral views, are required in digital subtraction angiography. Second, MDCT angiography makes it possible to show segments immediately distal to the point of occlusion, which are not opacified on digital subtraction angiography. This finding may be due to higher contrast resolution of MDCT, which shows only faintly opacified lumen distal to the complete occlusion, probably via collateral vessels (Otal et al., 2004)

Important nonvascular findings are not uncommon in the population being evaluated for vascular disease because patients often have multiple risk factors, such as smoking and advanced age. Nearly half of the patients undergoing CTA for vascular disease had unsuspected findings that were clinically insignificant, but 5% had life-threatening pathology, such as unsuspected malignancies

(Josephs et al., 2008)

A major drawback of CT angiography is the difficulty in assessing arterial luminal stenosis in extensively calcified vessels. Several groups of investigators (Ota et al., 2005; Graziani et al., 2008 and Al-Aly, 2007) reported that calcified plaques were the main reason for misinterpretations of CT angiograms. In the presence of extensive vessel wall calcifications, especially in small arteries, it is difficult to produce interpretable maximum intensity projection images. Continuous calcification of the vessel wall may lead to false-negative findings of patency, whereas high-attenuation artifacts, or "blooming," caused by calcification on transverse images may result in a false-positive diagnosis of a substantial stenosis or occlusion (Quwendijk et al., 2006).

Vascular calcification of the media is an increasingly recognized problem in patients with diabetes and patients with chronic kidney disease. Medial vascular calcification is also associated with significant morbidity and

mortality in both patients with diabetes and patients with advanced chronic kidney disease. Recent evidence suggests that medial vascular calcification is not a passive but rather active and a highly orchestrated process that involves molecular reprogramming, phenotypic and functional changes of vascular smooth muscle cells (Al-Aly, 2007)

In a recent study, diabetes mellitus, cardiac disease, and age were found to be independently predictive for the presence of vessel wall calcifications (all  $P < .05$ ). Regional calcification scores showed that only the effect of age was significantly different for the femoropopliteal region than that for the crural region and the aortoiliac region being about twice as strong for the former (Schernathner et al., 2007).

### **Patients and Methods**

This study included 30 patients (22 male and 8 females) ranging in age between 43 and 77 years (mean age 62.5 years). All patients were diabetic for a period ranging between 1 year and 14 years (mean duration 6.7

years). 3 patients presented with disabling claudication (<100 m.), 7 patients presented with chronic critical lower limb ischemia and 20 patients presented with tissue necrosis. Patients with serum creatinine exceeding 2 mg/dL or on chronic hemodialysis were excluded from this study.

Baseline data includes information on history of cardiovascular disease (including chest pain, percutaneous transluminal coronary angioplasty, coronary artery bypass graft, and myocardial infarction) cardiovascular risk factors (smoking history, Diabetes mellitus, hyperlipidemia), cerebrovascular disease (including transient ischemic attack and stroke), renal disease (including renal insufficiency, hemodialysis, and renal transplantation), and previous vascular interventions (including percutaneous transluminal angioplasty and vascular surgery). The stage of peripheral arterial disease (intermittent claudication or critical ischemia) was also defined.

Adequate hydration of patients was insured by oral administration of 1 liter of water 30 minutes

prior to start of examination to avoid any renal insult.

All patients underwent CT angiography with a 16-detector CT scanner (Brilliance-16; Philips Medical Systems, Cleveland, Ohio) from the level of the renal arteries down to the feet, at the following settings: rotation time, 0.5 second; voltage, 120 kV; and tube current, 200- 250 mAs, detector configuration of 16 x 1.5 mm was combined with a pitch of 0.98. This protocol allowed mean coverage of the examined region in a mean period of 26 seconds. Images were reconstructed at 2 mm thickness at 1-mm intervals using a standard filter and a mean image field of view of  $310 \pm 27$  mm (range, 260-374 mm).

Automated bolus-triggering technique (bolus pro ultra , Philips) was used in all patients. Non-incremental images were obtained at the level of the abdominal aorta starting 5 seconds after the start of the injection of contrast medium. The CT angiographic acquisitions were initiated at a trigger threshold of 180 H within the aorta.

Automated injections of contrast medium were performed with a programmable power injector. Iopamidol (Scanlux, Sanochemia AG, Austria), was used at a concentration of 370 mg I/mL for all CT studies. Biphasic injections of contrast medium were used in all patients. The first phase (duration, 5 seconds) consisted of injection of 25 mL of the contrast agent at a flow rate of 5 mL/s and was followed by a second phase in which the remaining contrast agent was injected at a flow rate of 3.8 mL/s. The total volume of contrast medium was 150 mL.

Adequate enhancement of the distal arteries was verified by visualization of early venous filling in the distal leg and foot veins otherwise a short second phase of examination for the foot and distal leg was initiated automatically immediately after termination of first phase to ensure adequate collateral contrast transit across occluded sections.

Post-processing was carried out on second work station (Extended Brilliance workspace, Philips Med-

ical Systems, Cleveland, Ohio). The following sets of images were generated: 3D volume rendered images (VR) maximum intensity projections (MIPs), multipath curved planar reformations (CPRs). Each set of images was generated over a viewing range of 180° in 9° intervals.

The arterial tree was subdivided into the following segments aorta, common iliac, internal iliac, external iliac, common femoral, deep femoral, superficial femoral, popliteal, tibio-peroneal trunk, anterior tibial, posterior tibial and peroneal arteries (23 segments for each patient).

Stenosis of arterial segment is graded by using a four-point scale. Grade I indicates a normal vessel or mild vessel irregularities (<10% luminal narrowing). Grade II indicates moderate arterial stenosis (10%-49% luminal narrowing). Grade III indicates severe arterial stenosis (50%–99% luminal narrowing). Grade IV indicates occlusion. Stenosis with a grade of I or II (<50% luminal narrowing) is considered to be hemodynamically insignificant, whereas



arterial stenosis with a grade of III or IV (50%-100% luminal narrowing) is considered hemodynamically significant. In case of concurrent arterial stenosis in a single arterial segment, only the stenosis with a higher grade was evaluated.

Calcifications were graded as 0= no calcifications, I= calcifications involving less than 50% of vessels circumference and II = calcifications exceeding 50 % of vessel circumference.

Management of the patients were decided according to the clinical assessment and the findings of the MDCT angiography.

### **Results**

This study included 30 patients with PAOD (690 arterial segment) adequate contrast filling of all segments of the arterial tree was achieved. No patients reported any adverse effects for contrast material administration.

In our 30 patients, stenotic segments was variable from grade I to grade IV. Table (1) shows the distribution of different grade of

vascular stenosis and occlusion along the examined part of the aorta, iliac and both lower limbs arteries:

As regard vascular calcification among examined patients, table (2) shows the degree of calcifications in the different parts of the examined arterial tree.

According to the finding of CT angiography, 8 patients were referred for endovascular treatment (5 percutaneous transluminal angioplasty PTAs and 3 stent implantation) and 7 patients referred for surgery (1 aortofemoral, 1 femorofemoral, 3 femoropopliteal, 1 femoroposterior tibial bypass and 1 patch). A combined endovascular and surgical approach was chosen for another 2 patients. The combined approach consisted of improvement of inflow by means of endovascular treatment before bypass graft surgery. For 13 patients, conservative treatment was indicated after CT angiography either due to mild degree of stenosis, no distal outflow vessel or unfit patients for surgery. Summary of treatment of 30 patients after CT angiography

shown in table (3).

In all patients in home endovascular treatment was indicated on the basis of CT angiographic result (n=8), the diagnostic angiogram obtained during intervention confirmed the CT angiographic finding.

During follow up of patients

treated conservatively, 9 of 13 patients treated after initial CT angiography had no additional finding. The other 4 patients had clinical progression of disease and underwent several treatment (2 bypass graft, 1 patch and 1 PTAs). One patient in home no distal outflow vessels was detected on CT angiography underwent amputation at thigh level.

**Table (1):** Number and distribution of stenotic segment in thirty patients (60 lower limb and 690 arterial segments).

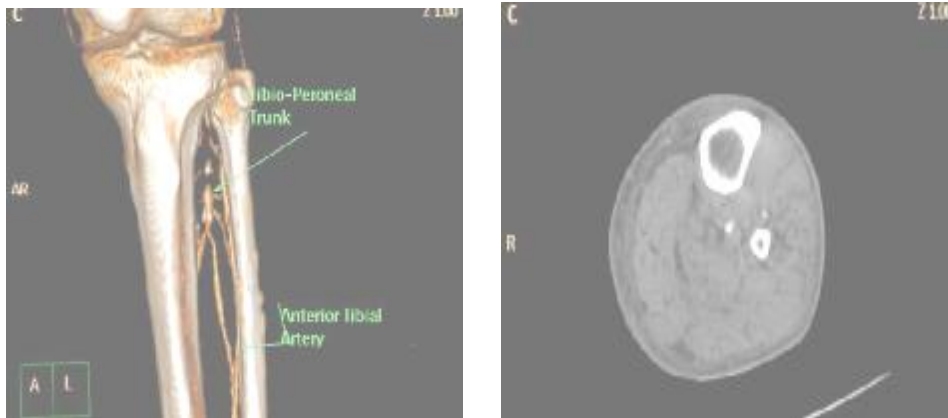
	<b>No or mild grade (0 - &lt;10 %)</b>	<b>Grade II (10 - &lt;50%)</b>	<b>Grade III (50 - &lt;99%)</b>	<b>Complete occlusion</b>
Aorto-iliac segment	57 (27.1%)	116 (55.2 %)	27 ( 12.9%)	10 (4.8%)
Femoro-popliteal segment	49 (20.4%)	131 (54.6 %)	42 (17.5 %)	18 (7.5%)
Distal run-off segment	43 (17.9%)	84 (35%)	86 (35.8 %)	27 (11.3%)

**Table (2):** The degree of calcification in examined arterial segments (690 arterial segments).

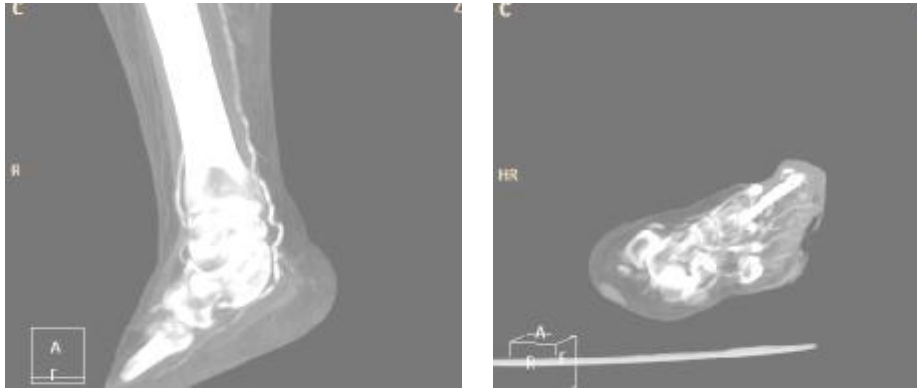
	<b>No calcifications</b>	<b>Grade 1 (&lt;50% of vessel margin)</b>	<b>Grade II (&gt;50% of vessel margin)</b>
Aorto-iliac segment	0	116 (55.3 %)	96 (45.7 %)
Femoro-popliteal segment	0	138 (57.5 %)	102 (42.5 %)
Distal run-off segment	0	129 (53.7 %)	111 (46.3 %)

**Table (3):** Summary of treatment of 30 patients after CT angiography

Procedure	No
Endovascular procedures:	
Percutaneous transluminal	5
Percutaneous transluminal angioplasty with stent	3
Surgical procedures:	
Patch	1
Bypass:	
<i>Femoropopliteal</i>	3
<i>Femoroposterior tibial</i>	1
<i>Femorofemoral</i>	1
Bifurcated aortic graft	1
Combined procedures ( endovascular & surgical)	2
Conservative treatment	13

**Fig. (1):** Total occlusion of left tibioperoneal trunk:

- (a) Three D-reformatting of Rt. L.L. arteries revealed total occlusion of the left TPT with adequate filling of the distal arteries (peroneal, anterior and posterior tibial arteries). Also it show hyperdense area of calcification in the occluded TPT.
- (b) Axial CT scan of the same patient at lower level revealed calcification in the wall of Rt. Peroneal artery with associated 50% stenosis.



**Fig. (2):** Calcified Rt. Posterior tibial artery with short stenotic segment as well as stenosis in plantar arch.

- (a) MIP technique (maximum intensity projection) technique shows multiple hyperdense areas of calcification in the distal PTA with short stenotic segment and another stenotic segment (more than 50%) in the plantar arch.
- (b) Coronal reformatting of the foot of the same patient revealed large skin ulcer of Rt. Foot, amputation of the 2nd, 3rd, 4th and fifth toes and the arteries of the foot could be seen.

### Discussion

The diagnostic standard for the evaluation of peripheral arterial occlusive disease (PAOD) is digital subtraction angiography, even though this technique has several disadvantages, such as invasiveness and high cost. Because of these disadvantages and the increasing incidence of PAOD a non-invasive diagnostic alternative to angiography is in high demand (Schernathner et al., 2007).

Recent advances in imaging

technology allowed noninvasive imaging of the vascular system with greater speed and improved resolution. The "gold standard," catheter-based angiography, is now more often used with therapeutic interventions rather than purely diagnostic studies (Josephs et al., 2008).

The two most important non-invasive methods for evaluation of PAOD are MR angiography and CT angiography. CT angiography has improved vastly with the clinical

availability of MDCT scanners. Studies comparing MR and CT angiography with digital subtraction angiography with regard to diagnostic accuracy in the detection of vascular lesions in patients with PAOD have shown high sensitivity and specificity of both MR angiography and CT angiography. The advantages of CT angiography over MR angiography are higher image resolution for better evaluation of the small vessels in the calves and higher patient acceptance due to a shorter examination time (Josephs et al., 2008; Schernathner et al., 2007 and Ofer et al., 2003).

Schernthaner et al. (2007), examined 58 patients with PAOD in diabetic patients by 16 multirow detector CT. These patients had age matched with our patients (43 to 77 y, mean age 62.5 y). They used the obtained CT data for treatment planning. In their group, forty-seven (81%) of 58 patients, CT angiographic examination of the abdominal aorta and runoff vessels revealed stenotic lesions. In our group we have similar results, where stenotic lesions were seen in 541 from 690 arterial

segments (78.4%). On the basis of CT findings, 18 patients of their group were referred for endovascular treatment and nine for surgery. A combined endovascular and surgical approach was chosen for another two patients. For 29 patients conservative treatment was indicated after CT angiography. In our group 30 patients (690 arterial segment) referred for endovascular treatment, 7 patients referred to surgery, 8 patients were referred for endovascular treatment, 2 patients referred for combined surgical and endovascular treatment and 13 patients treated conservatively.

Willmann et al. (2005), compared 16 detector row CT angiography and digital subtraction angiography in aortoiliac and lower extremities occlusive disease in a total 1365 evaluated arterial segments. They found that the image quality was considered diagnostic if all clinically relevant diagnostic information could be obtained with good differentiation of the arterial vasculature from background tissue (Willmann et al., 2005). In our study 30 patients (690 arterial segment) we have

similar results and we adopt the same role.

Stenosis of the arterial segment was graded by using four point Likert scale. Grade I indicated a normal vessel or mild vessel irregularities (<10% luminal narrowing), grade II indicated moderate arterial stenosis (10% - 49% luminal narrowing), grade III indicated severe arterial stenosis (50% - 99% luminal narrowing), grade IV indicated occlusion (Willmann et al., 2005). In our group (30 patients, 690 arterial segment) we used the same grading system and we found 57 segment (27.1%) in the aortoiliac region with grade I stenosis, 116 segment (55.2%) with grade II stenosis, 27 segment with grade III (12.9%) and complete occlusion of the aortoiliac region in 10 segment (4.8%). In the femoropopliteal segments we found grade I in 49 (20.4%), grade II in 131 (54.6%) grade III in 42 segment (17.5%) and total occlusion in 18 segment (7.5%), in distal run off segments we found 43 segments grade I (17.9%), grade II in 84 segment (35%), grade III in 86 segment (35.8%) and total occlusion in 27 segment (11.3%).

The feasibility of visualizing the course of the occluded segment is a great advantage of multi-detector row CT angiography in planning vascular intervention or bypass surgery, especially for lower peripheral arteries (Ota et al., 2005).

A major advantage of multi-detector row CT angiography is that it can provide information about extraluminal structures, wall status (e.g., calcifications, plaques), and the course of an occluded vessel, in addition to information made available with intraluminal contrast material-enhanced imaging. All of this information is essential for the success of an interventional procedure. Furthermore, optimal window width and level settings allow differentiation between luminal enhancement and adjacent high-attenuation structures such as calcifications and indwelling stents (Ota et al., 2005).

A shortcoming of multi-detector row CT angiography is that dense calcification may degrade the accuracy of the evaluation of stenosis due to beam-hardening arti-

facts (Ota et al., 2005). However routine use of a bone window setting in the evaluation of arterial segments when calcium is present may allow better evaluation of these calcified segments (Willmann et al., 2005).

Ota et al. (2004) graded calcification into 3 main grades: grade 0 no calcification, grade I less than 50% of the vessel margin and grade II more than of 50% of the vessel margin. We used the same grade of calcification and we found that grade 0 was not seen in any of our arterial segment. While, grade I was seen in 116 segment of the aortoiliac region (55.3%), and grade II in 96 segment (45.7%), while in the femoropopliteal segment, grade I in 138 segment (57.5%) and grade II in 102 segment (42.5%) while in the distal run off, grade I was seen in 129 segment (53.7%) and grade II in 111 segment (46.3%).

In conclusion MDCT makes it possible to evaluate short segmental stenosis accurately. MDCT angiography permits the precise evaluation of the vascular wall itself. It can clearly depict the

courses of vessels not only in patent but also in completely occluded segments; such depictions provide useful information for planning interventional radiology revascularization procedures. If a surgical procedure is required, the preoperative information concerning the vascular wall, such as the degree of mural calcification and plaques, obtained with MDCT angiography is important in determining the anastomotic sites for bypass grafting. In addition, extra-vascular causes of occlusion may be detected on CT angiography.

### References

**Al-Aly Z. (2007)** : Medial vascular calcification in diabetes mellitus and chronic kidney disease: The role of inflammation. Cardiovasc and Haematological Discord-Drug Targets 7:1-61.

**Graziani L, Silvestro A, Monge L., et al., (2008)** : Transluminal Angioplasty of Peroneal Artery Branches in Diabetics: Initial Technical Experience. Cardiovasc Intervent Radiol 31:49-55.

**Josephs S. C., Rowley H. A., Rubin M. D., et al., (2008)** : Ath-

erosclerotic Peripheral Vascular Disease Symposium II. Circulation 118:2837-2844.

**Ofer A., Nitecki S. S., Linn S., et al., (2003)** : Multi-detector CT angiography of peripheral vascular disease: A prospective comparison with intraarterial digital subtraction angiography. AJR 180:719-724.

**Ota H., Takase K., Igarashi K., et al., (2004)** : MDCT compare with digital subtraction angiography for assessment of lower extremity arterial occlusive disease: Importance of reviewing cross-sectional images. AJR 182 : 201-209.

**Ota H., Takase K., Rikimaru H., et al., (2005)** : Quantitative Vascular Measurements in Arterial Occlusive Disease. RadioGraphics 25:1141-1158.

**Quwendijk R., De Vries M., Pattynama P. M., et al., (2005)** : Imaging peripheral arterial dis-

ease: A randomized controlled trial comparing contrast-enhanced MR angiography and multi-detector row CT angiography. Radiology 236:1094-1103.

**Quwendijk R., Kock M. C., Van Dijk L. C., et al., (2006)** : vessel wall calcifications at multi-detector Row CT angiography in patients with peripheral arterial disease : Effect on clinical utility and clinical predictors, Radiology; 241:603-608.

**Schernthaner R., Fleischmann D., Lomoschitz F., et al., (2007)** : Effect of MDCT Angiographic Findings on the Management of Intermittent Claudication. AJR 189:1215-1222.

**Willmann J., Baumert B., Schertler T., et al., (2005)**: Aortoiliac and Lower Extremity Arteries Assessed with 16-Detector Row CT Angiography : Prospective Comparison with Digital Subtraction Angiography Radiology 236: 1083-109.



REPRINT

# **BENHA MEDICAL JOURNAL**

## **ROLE OF MULTI-DETECTOR CT ANGIOGRAPHY IN MANAGEMENT OF DIABETIC PATIENTS WITH PERIPHERAL ARTERIAL OCCLUSIVE DISEASE**

**Ashraf Abdel El-Rahman MD, Abdel Salam Megahed MD  
and Manal El-Tarshouby MD**

**Published by  
Benha Faculty of Medicine**

*Volume 26 Number 3  
Sept. 2009*

## **EVALUATION OF A VARIETY OF SUTURE MATERIALS USED IN FRONTALIS SUSPENSION SURGERY FOR SEVERE UPPER EYELID PTOSIS**

**Nader R. El-Metwally MD and Nashaat Shawky MD**

*Department of Ophthalmology, Faculty of Medicine,  
Mansoura University, Egypt*

### **Abstract**

**Purpose :** *To compare three different suture materials that was used in frontalis suspension surgery for correction of severe upper eyelid ptosis.*

**Patients & Methods :** *Thirty patients (55 eyes) with severe congenital ptosis attending the outpatient clinic of Mansoura Ophthalmic Centre during the period from 2004 to 2005 were included in this study. Frontalis suspension surgery was performed to all patients using three different suture materials namely (autogenous fascia lata, monofilament nylon suture and silicone rod). Functional and cosmetic success, ptosis recurrence, lagophthalmos and other complications were evaluated.*

**Results :** *Thirty patients (55 surgeries, 25 bilateral & 5 unilateral cases) were included in this study. There were 16 males and 14 females. The age ranged from 6 months to 12 years. We used autogenous fascia lata in 6 eyes, silicone rod in 12 eyes and monofilament nylon suture in 37 eyes. Follow up ranged from 3 - 5 years postoperatively. The early functional and cosmetic results were nearly similar between all groups without statistically significant differences. All cases receiving autogenous fascia lata were bilateral including 2 cases of Marcuss-Gunn jaw-winking phenomena.*

*Regards the complications, recurrence of ptosis was noted more in cases of silicone rod than monofilament nylon suture, while recurrence rate was least in cases receiving autogenous fascia lata which also occurred after long period from surgery. Lid lag was noted in all three groups but less evident in the first group receiving autogenous fascia lata. In cases*

receiving silicone rod, 2 cases (3.6 %) of pyogenic infection were found which necessitate removal of the silicone rod and one case (1.8 %) of extrusion of the silicone suspensor was noted. No granuloma formation was noted in the incision site in any case of all groups.

**Conclusion:** No statistically significant difference was noted between the three different suture materials used in this study for frontalis suspension procedure regarding the functional and cosmetic results. The lowest incidence of ptosis recurrence and lid lag was noted among cases receiving autogenous fascia lata. Further comparative studies are needed to detect the best suture material which can be used in frontalis suspension procedure with the least incidence of recurrence & other complications.

### **Introduction**

Frontalis suspension is the operative procedure often used for treatment of severe blepharoptosis with poor or absent levator muscle function. Poor levator function has been broadly defined as levator muscle movement of 2 mm or less and no more than 6 mm by variable authors. (Wagner RS, et al., 1984 & Steinkogler FJ, et al., 1993) Frontalis suspension creates a linkage between the frontalis muscle and the tarsus of the upper eyelid, which allows for a better eyelid position in primary gaze. Eyelid elevation is then performed with the use of the frontalis muscle. (Evoli A, et al., 2001 & Becher M, et al., 2001)

Frontalis suspension is most commonly used for congenital ptosis but is also used to treat blepharophimosis syndrome, Marcus Gunn jaw-winking phenomenon, congenital fibrosis syndrome, cranial III nerve palsy and double elevator palsy. Treatment is most important when an eyelid blocks the visual axis causing amblyopia, or when an anomalous head posture is apparent. (Saunders R, Grice CM, 1991 & Roggenkamper P, Nussgens Z, 1997).

Frontalis suspension surgery may use several surgical techniques and different sling materials. (Goldberger S, et al., 1991 & Dailey R, et al., 1991) Materials include autogenous or banked fas-

cia lata and alloplastic materials that include chromic gut, collagen, polypropylene, silicone, stainless steel, silk, nylon monofilament, polyester and polytetrafluoroethylene (PTFE). (Liu D, 1999 - Wasserman B, et al., 2001 - Fan J, 2001 - Bernardini F, et al., 2002 - Leibovitch I, et al., 2003 - Metha P, et al., 2004 & Bajaj M, et al., 2004) Autogenous fascia lata has long been considered the material of choice for frontalis suspension, with comparably low rates of recurrent ptosis and infections. (Crawford J, 1977 - Sweep H, Sqauwen PH, 1992 & Leibovitch I, et al., 2003).

Cosmetic issues that are raised with standard frontalis suspension surgery include scarring in young children, unsatisfactory tenting of the pretarsal and pre-septal skin, obliteration of the eyelid crease and a poor tarso-corneal interface noted with brow elevation and downgaze. These may be related to the choice of the sling material and to the superficial location of the sling in the eyelid. (Wilson M, Johnson RW, 1991 - Wasserman B, et al., 2001 & Leibovitch I, et al., 2003).

The purpose of this study was to compare three different suture materials that was used in frontalis suspension surgery for correction of severe upper eyelid ptosis namely (autogenous fascia lata, monofilament nylon suture and silicone rod) as regards the functional and cosmetic success, ptosis recurrence, lagophthalmos and other complications.

#### **Patients and Methods**

Thirty patients (55 eyes) with severe congenital ptosis attending the outpatient clinic of Mansoura Ophthalmic Centre during the period from 2004 to 2005 were included in this study. There were 16 males and 14 females. The age ranged from 6 months to 12 years. Frontalis suspension surgery was performed to all patients using three different suture materials namely (autogenous fascia lata, monofilament nylon suture and silicone rod). We used autogenous fascia lata in 6 eyes, silicone rod in 12 eyes and monofilament nylon suture in 37 eyes. Patients were examined 1 day, 1 week, 1, 3, 6, 12 months after the operation and every year thereafter for a period ranging from 3 - 5 years.

Functional and cosmetic success, ptosis recurrence, lagophthalmos and other complications were evaluated.

Functional success was defined as improved eyelid position above the pupillary margin with good linkage between the frontalis muscle and the upper eyelid, no ptosis recurrence during the follow up period, and no severe complications such as suture exposure or infection. Linkage is measured by manual elevation of the eye brow on the operated side and measurement of motility of the upper eyelid along with eye brow elevation. If manual eye brow elevation results in similar eyelid elevation, then 100% linkage was achieved with surgery. If only one half of the elevation is noticed in the eyelid, then 50% linkage was achieved with surgery.

Cosmetic outcome was graded on a 0 to 2 scale, with 0 score indicative of excellent results, 1 as good, and 2 as poor. Outcome was defined as excellent if the eyelids were within 1 mm height between the eyelids with an acceptable crease and contour, good if there

was > 1 mm difference in eyelid height and/or assymmetric crease, and poor if there was a poorly defined eyelid crease and contour assymetry.

A detailed history especially about the onset of ptosis, the degree of its variability throughout the day, associated diplopia, history of prior trauma, previous ocular surgery or use of botulinum toxin was taken from all patients. A complete eye examination was done for every patient especially emphasizing on extraocular muscle balance, pupillary function, interpalpebral fissure height, margin reflex distance (MRD), levator muscle function, upper lid crease position, presence of Bell's phenomenon and evaluation of Muller's muscle function.

The surgical technique as described anywhere in the literature was performed for all cases under general anaesthesia in a double pentagon fashion. (Yip CC, et al., 2004) (Figure 1) All the results are statistically analyzed using SPSS program (version 13.0; SPSS Inc, Chicago, Illinois, USA) using one sample t test, Chi-square non-

parametric test and One-way analysis of variance (ANOVA) test to evaluate different suture materials.

### Results

Thirty patients with severe congenital ptosis (Figure 2) attending the outpatient clinic of Mansoura Ophthalmic Centre during the period from 2004 to 2005 (55 surgeries; 25 bilateral & 5 unilateral cases) were included in this study. There were 16 males and 14 females. The age ranged from 6 months to 12 years. We used autogenous fascia lata in 6 eyes, silicone rod in 12 eyes and monofilament nylon suture in 37 eyes. Follow up ranged from 3 - 5 years postoperatively. (Table 1)

The upper lid was elevated in all patients, improving their head position and unmasking their visual axis in the primary gaze. The early functional and cosmetic results were nearly similar between all groups without statistically significant differences. All cases receiving autogenous fascia lata were bilateral including 2 cases of Marcus-Gunn jaw-winking phenomena.

Regards the complications, recurrence of ptosis was noted more in cases of silicone rod than monofilament nylon suture, while recurrence rate was least in cases receiving autogenous fascia lata which also occurred after long period from surgery. Lid lag was noted in all three groups but less evident in the first group receiving autogenous fascia lata. In cases receiving silicone rod, 2 cases (3.6%) of pyogenic infection (Figure 3) were found which necessitate removal of the silicone rod and one case (1.8 %) of extrusion of the silicone suspensor (Figure 4) was noted. No granuloma formation was noted in the incision site in any case of all groups. (Table 2)

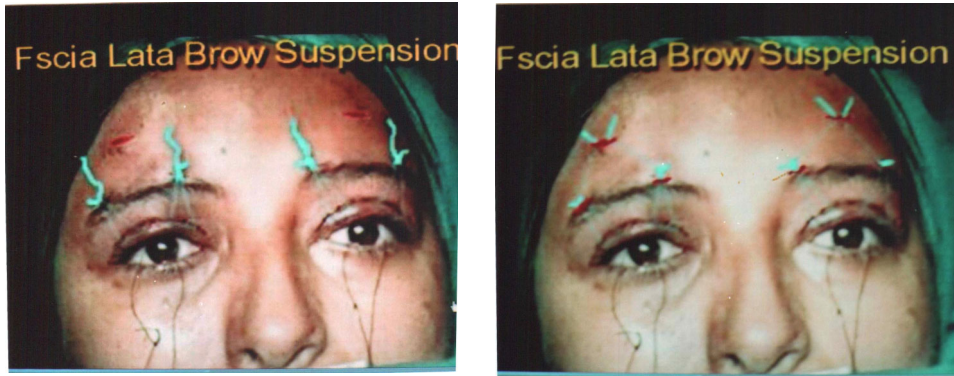Most patients achieved good cosmetic outcome, with a mean score of  $0.7 \pm 0.5$  on a 0 to 2 scale (0 = excellent; 1 = good and 2 = poor) without statistically significant differences between all groups (ANOVA test). Nearly similar functional outcome and ptosis recurrence was found for autogenous fascia lata and alloplastic materials including monofilament nylon suture or silicone rod.

**Table (1):** Cases and diagnosis.

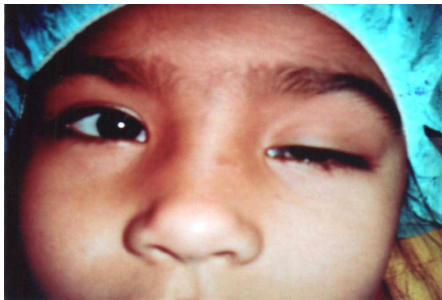
Age (range)	6 months - 12 years
Sex	16 males (53.3 %)
	14 females (40.7 %)
Bilateral	25 cases (83.3 %)
Unilateral	5 cases (16.7 %)
Diagnosis	28 congenital ptosis
	2 cases jaw-winking
Degree of ptosis	Severe (4 mm or more)
Levator function	Poor
Follow up time	3 - 5 years
Suture Material used:	
1. Autogenous fascia lata	6 eyes (10.9 %)
2. Monofilament nylon suture	37 eyes (67.3 %)
3. Silicone rod	12 eyes (21.8 %)

**Table (2):** Results and postoperative complications.

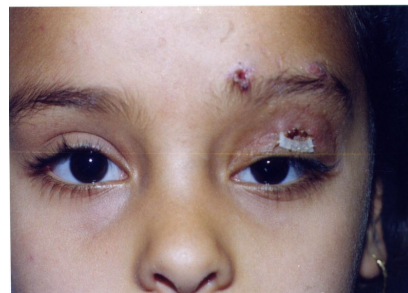Lid level results	No. of patients	Percentage
Excellent	5 patients	16.7 %
Good	18 patients	60 %
Moderate	7 patients	23.3 %
Posoperative complications		
1. Ptosis recurrence	Fascia 1 eye Nylon 8 eyes Silicone 4 eyes	16.7 % 21.6 % 33.3 %
2. Lid lag	Fascia 2 eyes Nylon 18 eyes Silicone 6 eyes	33.3 % 48.6 % 50.0 %
3. Pyogenic infection	Fascia No case Nylon No case Silicone 2 eyes	00.0 % 00.0 % 3.6 %
4. Extrusion	Fascia No case Nylon No case Silicone 1 eye	00.0 % 00.0 % 1.8 %



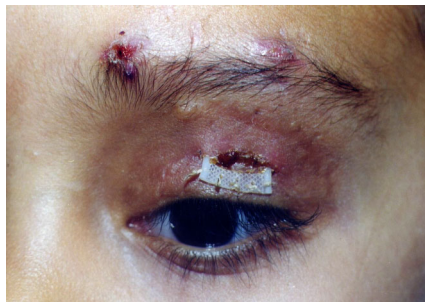**Fig. 1:** Bi-triangular (modified Crawford) method for frontalis suspension using fascia lata. (according to Leatherbarrow B, 2002) .



**Fig. 2:** A case of severe congenital ptosis of the left eye.



**Fig. 3:** a case of postoperative pyogenic infection following silicone rod frontalis sling which necessitate its removal.



**Fig. 4 :** a case of extrusion of the silicone rod postoperatively.



### **Discussion**

Children with severe congenital ptosis are at risk of developing amblyopia if lids obscure the visual axes. Generally these patients have poor levator function, and frontalis sling operation is required, it is generally agreed that fresh autogenous fascia lata is the material of choice for frontalis sling procedures in congenital ptosis. (Crawford JS, 1982 - Wagner RS, et al., 1984 & Wasserman B, et al., 2001).

In recent years, many studies have tried to evaluate the functional success of various sling materials in frontalis suspension surgery. Autogenous fascia lata has been considered to result in lower ptosis recurrence and lower complications rate (as noted in our patients) and therefore has been considered the material of choice. (Wilson M, Johnson RW, 1991 & Liu D, 1999).

Recurrence rate after frontalis suspension vary and reported to be between 0 and 100%; PTFE and autogenous fascia have the lowest recurrence rate, reported to be between 4 and 20% and nylon

or silicone have reported recurrence rates between 40 and 100%. Suture material serves as a temporary skeleton for scar formation, by local inflammation. Scar tissue and not the sling material may be the actual bridge between the frontalis muscle and the eyelid; therefore no difference is anticipated between different materials as long as they remain in good position during the inflammation and the scarring process. (Ben Simon GJ, et al., 2005).

Ptosis recurrence is a severe problem that evolves after surgery; many investigators believe that eventually all cases of congenital ptosis that are treated with frontalis suspension will recur. This is evident from a higher recurrence rate published in studies with a longer follow up periods, regardless of suture material (range, 7 to 100%). (Wilson M, Johnson RW, 1991 - Carter S, Meecham WJ, 1996 - Esmaeli B, et al., 1998 & Ben Simon GJ, et al., 2005).

The survival analysis described by Wilson and Johnson (Wilson M, Johnson RW, 1991) shows decreasing success of suspension

with lyophilized human fascia lata with longer follow up period, from 90 % at 2 to 3 years after surgery to 50% at 8 and 9 years after surgery. In cases of congenital ptosis, parents and children should realize that ptosis recurrence rate is high after surgery and that the patient is likely to have additional surgeries. However, despite the fact that autogenous fascia has better biocompatibility than alloplastic materials; similar functional and cosmetic outcomes may be achieved with alloplastic materials. (Jeong S, et al., 2000 & Ben Simon GJ, et al., 2005).

An important goal of ptosis surgery is symmetric and natural-appearing cosmetic results. Tenting of pretarsal and preseptal skin, obliteration of eyelid crease, and pulling away of the upper eyelid from the globe with brow elevation may all influence cosmetic outcome. The superficial location of the sling in the eyelid may result in poor outcome, and deeper placement of the sling behind superior orbital rim may yield better cosmetic and functional results. (Pattinelly J, Anderson RL, 2006).

Common complications that are associated with frontalis suspension include early postoperative exposure keratopathy (15 %), inflammation or pyogenic granuloma, suture infection with preseptal cellulitis, and suture exposure. Rates of each complication vary with different sling material and are reported to be 2 to 17 % for suture granuloma, 3 to 7 % for suture infection or preseptal cellulitis, and 5 to 17 % for suture extrusion. (Esmaeli B, et al., 1998 - Liu D, 1999 - Fan J, 2001 - Metha P, et al., 2004 - Metha P, et al., 2004) We had a relatively low rate of postoperative complications with 3.6 % incidence of suture infection and 1.8 % of suture exposure all occurring in cases receiving silicone rod.

The primary surgical goal in patients with minimal levator function congenital blepharoptosis is to utilize the elevating power of the frontalis muscle to raise the eyelid, thus opening the visual axes. Secondary goals include establishment of a defined symmetric eyelid crease and an appropriate matching eyelid contour. Of course, desirable characteristics

inherent in any surgery include sustained results with a low incidence of complications.

### Conclusion

In this group of patients, frontalis suspension surgery for severe cases of upper eyelid congenital ptosis resulted in similar functional and cosmetic outcomes with different materials, including autogenous fascia lata, monofilament nylon sutures and silicone rod and the least rate of ptosis recurrence and lid lag was achieved in cases receiving autogenous fascia lata. Further studies with a longer follow up period are required to compare the longevity of different suture materials.

### References

**Bajaj M., Sastry S. S., Ghose S., et al., (2004)** : Evaluation of polytetrafluoroethylene suture for frontalis suspension as compared to polybutrylate-coated braided polyester. Clin Exp Ophthalmol.; 32: 415-419.

**Becher M., Morrison L., Davis L. E., et al., (2001)** : Oculopharyngeal muscular dystrophy in

Hispanic New Mexicans. JAMA.; 286:2437-2440.

**Ben Simon G. J., et al., (2005)** : Frontalis suspension for upper eyelid ptosis: evaluation of different surgical designs and suture materials. Am J Ophthalmology.; 140: 877-885.

**Bernardini F., de Conciliis C. and Devoto M. P. (2002)** : Frontalis sling using a silicone rod in patients affected by myogenic blepharoptosis. Orbit.; 21: 195-198.

**Carter S., Meecham W. J. (1996)** : Silicone frontalis slings for the correction of blepharoptosis: indication and efficacy. Ophthalmology.; 103: 623-630.

**Crawford J. (1996)** : Repair of ptosis using frontalis muscle and fascia lata: a 20-year review. Ophthalmic Surg. 1977; 8: 31-40.

**Crawford J. S. (1982)** : Frontalis sling operation. J Pediatr Ophthalmol Strabismus.; 19: 253-255.

**Dailey R., Wilson D. J. and**

- Wobig J. L. (1991)** : Transconjunctival frontalis suspension (TCFS). *Ophthal Plast Reconstr Surg.*; 7: 289-297.
- Esmaeli B., Chung H. and Pashby R. C. (1998)** : Long-term results of frontalis suspension using irradiated banked fascia lata. *Ophthal Plast Reconstr Surg.*; 14: 159-163.
- Evoli A., Batocchi A. P., Minisci C., et al., (2001)** : Therapeutic options in ocular myasthenia gravis. *Neuromusc Disord.*; 11: 208-216.
- Fan J. (2001)** : Frontalis suspension technique with a temporal-fasciae-complex sheet for repairing blepharoptosis. *Anesth Plast Surg.*; 25 : 147-151.
- Goldberger S., Conn H. and Lemor M. (1991)** : Double rhomboid silicone rod frontalis suspension. *Ophthal Plast Reconstr Surg.*; 7: 48-53.
- Jeong S., Ma Y. R. and Park Y. G. (2000)** : Histopathological study of frontalis suspension materials. *Jpn J Ophthalmol.*; 44 : 171-174.
- Leatherbarrow B. (2002)** : *Oculoplast Surg.* Martin Dunitz.; 2: 48.
- Leibovitch I., Leibovitch L. and Dray J. P. (2003)** : Long-term results of frontalis suspension using autogenous fascia lata for congenital ptosis in children under 3 years of age. *A J Ophthalmol.*; 136: 866-871.
- Liu D. (1999)** : Blepharoptosis correction with using a nylon monofilament sling: duration of effect. *A J Ophthalmol.*; 128 : 772-773.
- Metha P., Patel P. and Olver J. M. (2004)** : Functional results and complications of Polyester mesh use for frontalis suspension ptosis surgery. *Br J Ophthalmol.*; 88 : 361-364.
- Metha P., Patel P. and Olver J. M. (2004)** : Management of Polyester mesh chronic eyelid complications : a systematic approach. *Eye.*; 18 : 640-642.

- Patrinely J. and Anderson R. L. (2006)** : The septal pulley in frontalis suspension. Arch Ophthalmology.; 104 : 1707-1710.
- Roggenkamper P. and Nussgens Z. (1997)** : Frontalis suspension in the treatment of essential blepharospasm unresponsive to botulinum- toxin therapy: long-term results. Graefes Arch Clin Exp Ophthalmol.; 235: 486-489.
- Saunders R. and Grice C. M. (1991)** : Early correction of severe congenital ptosis. J Pediatr Ophthalmol Strabismus.; 28: 271-273.
- Steinkogler F. J., Kuchar A., Huber E. and Arock-Mettinger E. (1993)** : Gore-Tex soft tissue patch frontalis suspension technique in congenital ptosis and in blepharophimosis syndrome. Plast Reconstr surg.; 92:1057-1060.
- Sweep H. and Squawen P. H. (1992)** : Evaluation of expanded polytetrafluoroethylene (e-PTFE) and autogenous fascia lata in frontalis suspension : a comparative clinical study. Acta Chir Plast.; 34 : 129-137.
- Wagner R. S., Mauriello J. A., Nelson L. B., Calhoun J. H., Flanagan J. C. and Harley R. D. (1984)** : Treatment of congenital ptosis with frontalis suspension: a comparison of suspensory materials. Ophthalmology.; 91: 245-248.
- Wasserman B., Sprunger D. T. and Helveston E. M. (2001)** : Comparison of materials used in frontalis suspension. Arch Ophthalmol.; 119 : 687-691.
- Wilson M. and Johnson R. W. (1991)** : Congenital ptosis: long-term results of treatment using lyophilized fascia lata for frontalis suspension. Ophthalmology.; 98: 1234-1237.
- Yip C. C., Goldberg R. A., Cook T. L. and McCann J. D. (2004)** : Incision-less frontalis suspension. Br J Ophthalmol.; 88: 585-586.

REPRINT

# **BENHA MEDICAL JOURNAL**

**EVALUATION OF A VARIETY OF  
SUTURE MATERIALS USED IN  
FRONTALIS SUSPENSION  
SURGERY FOR SEVERE  
UPPER EYELID PTOSIS**

**Nader R. El-Metwally MD and Nashaat Shawky MD**

**Published by  
Benha Faculty of Medicine**

*Volume 26 Number 3  
Sept. 2009*

## **A COMPUTER SOFTWARE SYSTEM FOR MEASURING SIZE CHANGES IN OPTIC DISK IN PATIENTS WITH GLAUCOMA**

**Mostafa G. M. Mostafa MD, Abdullah M. Albinali MD  
and Nashaat S. Ibrahim MD\***

*Computer Science Department, College of Computer Science & Engineering,  
Taibah University, Al-Madinah Al-Munawwarah, K.S.A.*

*\*Ophthalmology Department, College of Medicine, Taibah University, Al-Madinah  
Al-Munawwarah, K.S.A.*

### **Abstract**

**Purpose:** *Building a quantitative, readily available, inexpensive, reproducible, and valid optic disk staging system using a computer software will replace the use of such expensive highly sophisticated instruments like HRT & OCT which are not always available especially in rural areas and primary health care centers, which will assist ophthalmologists by providing them with some of the tools necessary to assist in the diagnosis and follow up of glaucoma patients, through the digital image analysis techniques of fundus images obtained from fundus camera.*

**Materials & Methods:** *We implemented three different image analysis techniques: Expectation Maximization (EM), Fuzzy c-Mean (FCM), and Neural Networks (NN) using digital images of glaucomatous patients taken from an relatively inexpensive commonly used fundus camera. We used the three methods to segment both intensity (grayscale) and color images. Then, we use these segmented images to measure the optic disk and the cup, from which we measure other important factors, e.g. cup-to-disk ratio, rim-to-disk ratio. The results obtained from this software program were compared to the same parameters obtained from OCT and HRT instruments.*

**Results:** *Results show that the EM and the NN methods produce good results for both intensity (grayscale) and color images, while FCM method gives the lowest performance for both images. The error rate of the proposed methods, about 33%, is comparable to the expected error from the*

*HRT and the OCT devices.*

**Conclusion:** *the EM and the NN methods produce good results for both intensity (grayscale) and color images, while FCM method gives the lowest performance for both images. The error rate of the proposed methods, about 33%, is comparable to the expected error from the HRT and the OCT devices. In future work, we plan to employ segmentation techniques that takes into account the geometry of the image, e.g the employ edge detection and detect conic shape, to be able to localize both the disk and the cup more efficiently.*

**Keywords:** *Medical Image Analysis, Fuzzy c-mean Classification, Optic Cup-to-Disk Ratio, Glaucoma Diagnosis.*

### **Introduction**

The digital image processing for producing topographical information of the retina is specifically very useful in diagnosis and observation of the progression of some eye diseases, such as glaucoma, which is one of the most common causes of blindness [Lee BL, et al., 1998]. The irreversible vision damage from glaucoma makes the early diagnosis significantly important for timely treatment. The characteristic of glaucoma is cupping of the optic nerve head (optic disc). Hence, measuring the cupping area in the optic disc, is an aiding tool for early glaucomatous diagnosis as well as a following-up tool for the glaucomatous optic disk to monitor the progression of the disease [Anderson DR, Caprioli J, 1995]

[Gupta N, Weinreb RN, 1997].

There are four quite separate aspects of disk evaluation as it relates to glaucoma: 1) distinguishing between the healthy and the sick, that is, diagnosing; 2) grouping the patients into large categories of disease such as healthy, mild, moderate, and advanced disease; 3) monitoring change for the better or for the worse; and 4) quantitatively measure the rate of any change that has occurred [Iester M., et al., 2001].

A great research has been done for finding ways to measure the optic disk in glaucomatous patients. The cup is defined at approximately 150  $\mu\text{m}$  down from the top edge of disk boundary. Some clinicians use a stereoscope to obtain 3-D visualization from a



stereo image pair, but its result depends on the experience and skill of each doctor [Musch DC, et al., 1999]. The more advanced alternatives are to use more specialized and uncommon medical instruments such as Heidelberg retina tomography (HRT), which is based on scanning laser technique. However, these instruments involve higher-level training and high cost of expensive proprietary hardware and software; the image size and depth resolution are fixed by HRT; only pseudo-colors are assigned on the 3-D image by HRT and the original colors of retina cannot be obtained by this instrument [Kamal DS, et al., 2000]. Another effective instrument is the optical coherence tomography (OCT) [Choplin NT, Lundy DC, 2001], which is used to obtain cross-sectional images of the retina. However, the full 3-D visualization and true color information cannot be obtained from OCT. On the other hand, digital fundus camera with higher resolution and more advanced performance are becoming more affordable. This research work has made the idea of having an easy-to-use, automatic measurement of the C/

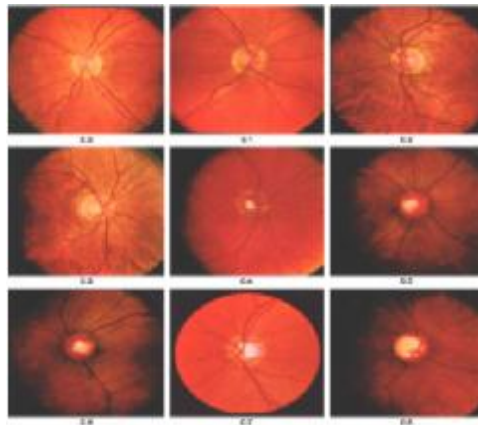
D ratio from a cost-efficient, fundus camera more attractive.

This research is organized as follows. In Section 2, we present a background of the subject and review some of the currently used imaging modalities. Section 3 presents the proposed methodology for measuring the C/D ratio using image segmentation methods. Finally, Section 4 concludes the study and mention the future work.

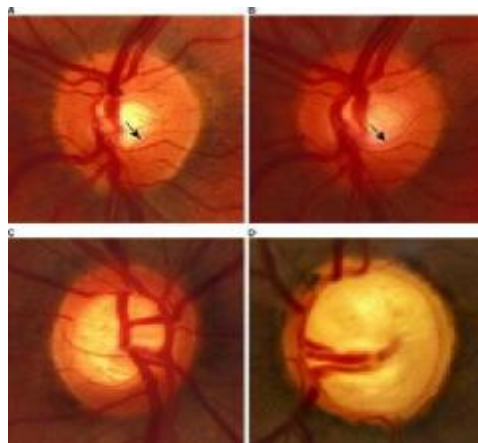
#### **Background**

The cup/disk (C/D) ratio is one of the significant measurements that is found to be suspicious for glaucoma above a particular size - usually 0.3. When the cup/disk ratio is greater than 0.6, the disk is often considered to be glaucomatous [Musch DC, et al., 1999]. Indeed, this method continues to be used as a way to separate normal disk from abnormal disk, as shown in Fig. 1. The true method of estimating cup/disk ratio depends on the angulation & dipping in of the small blood vessels on the surface of the disk rather than the area of pallor, as shown in Fig. 2. However, cup/disk ra-

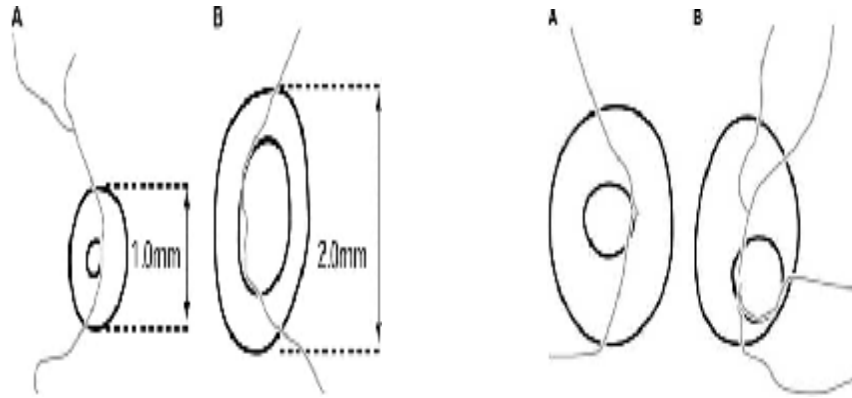
tios tend to be misleading because it depends on many factors such as the total size of the disc, as shown in Fig. 3a, the site of the cup within the disc, as shown in Fig. 3b, and other factors.



**Fig. 1:** Armaly's nomogram for cup/disk ratio system.



**Fig. 2 :** C/D ratio depends on angulation of small B.V. rather than area of pallor.



**Fig. 3 :** Cup/disk ratio depends on the total size of the disk (left) and on the site of the cup within the disk (right).

#### **Image Acquisition Devices**

There are three imaging modalities that can be used to characterize the topography of the optic disk: Namely: The fundus camera [Soliman MA, et al., 2002], the scanning laser ophthalmoscope (Heidelberg Retina Tomography, HRT) [Kamal DS, et al., 2000], and the optical coherence tomography (OCT) [Choplin NT, Lundy DC, 2001]. The HRT and the OCT methods provide quantitative estimates of disk size, rim area, cup depth, cup shape, etc. (more parameters obtained with HRT) while the fundus camera provides only photographic digital images. In the following sections we elaborate more on each of these imaging devices.

#### **The Fundus Camera**

A cost-efficient imaging device for the retina is the computer-connected digital fundus camera [Soliman MA, et al., 2002], which provides color computer digital optic disk images with resolution 576x768 pixels. Two dimensional photos, whether color or black and white, have the advantages of simplicity and lower cost. In addition, the relative dimension of the pallor and cup can be measured directly on the photograph [Hitching RA, et al., 1983]. Qualitative evaluation of disc photographs is highly subjective and planimetry is subjective and requires experienced technicians. The methods are thus prone to high inter observer variation. In addition, clear

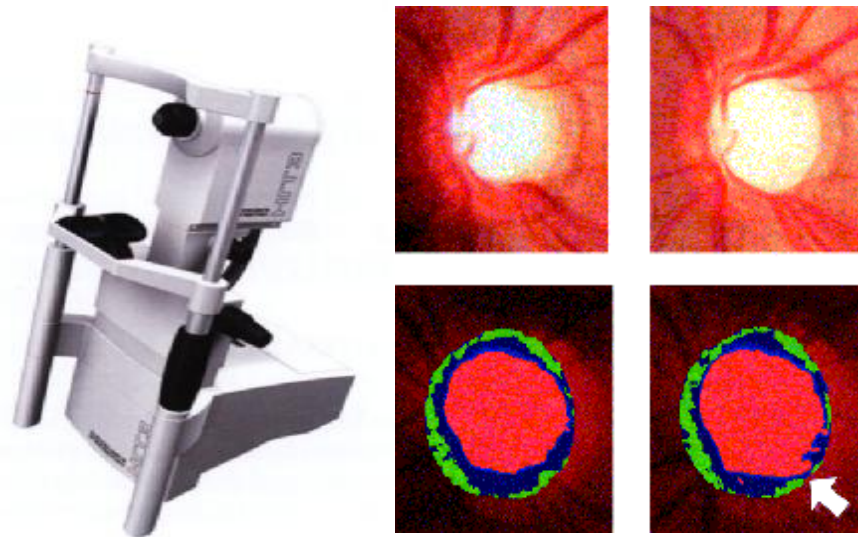
optic media and good pupillary dilatation are required for optic disc photography [Iester M., et al., 2001]. The specificity of this method has been found to be 67% with a sensitivity of 62% [M. G.-H. Mostafa, et al., 2003].

#### **The HRT Imaging Device**

The Heidelberg Retinal Tomograph (HRT) [Schuman J and Kim J, 2000 - Kesen MR, et al., 2002 - Mardin CY, et al., 2003 & Correnti AJ, et al., 2003] uses confocal scanning laser ophthalmoscopy (CSLO) to produce pseudo-three-dimensional images of the nerve head. Confocal scanning laser ophthalmoscopy (CSLO) [E.Z. Blumenthal and R.N. Weinreb, 2001] provides a three-dimensional topographic representation of the optic disk and peripapillary retina, which is constructed from a series of two-dimensional slices. This three-dimensional representation consists of 256x256 pixel elements, each of which is a measurement of retinal height at its corresponding location. Three topography images are usually acquired in a single session and thereafter are automatically aligned and averaged to obtain a

single mean topography image [E.Z. Blumenthal and R.. N. Weinreb, 2001]. Although the CSLO is similar, in many respects, to a CT scan, the light rays used for CSLO cannot penetrate tissue; this limits this modality to depicting the surface topography of the optic disk and parapapillary retina. CSLO does not measure RNFL thickness directly. Instead, the image is aligned for any tilt (whether anatomical or due to the scanning angle), the parapapillary retinal surface height is subtracted from an imaginary plane running 50 microns below the surface of the temporal parapapillary retina along the disk margin. By assuming that this plane separates the RNFL from the underlying remainder of the retina, a RNFL thickness map is then constructed. Two Heidelberg Retina Tomograph (HRT, Heidelberg Engineering, Heidelberg, Germany) parameters summarize this data: RNFL thickness and RNFL cross-sectional area. In addition to quantitative RNFL thickness data, the CSLO can present the acquired data in the form of optical slices. Some of these slices, particularly those at the plane of the

RNFL, may show qualitative focal RNFL defects (Fig. 4).



**Fig. 4 :** HRT device & its estimation of optic disk changes in glaucoma.

Several limitations of CSLO have been identified. Correct measurement of the disk topography and associated summary indices is dependent upon correct placement of the contour line (optic disk margin) by the operator, as well as upon intraocular pressure and cardiac pulsations. As with other technologies reviewed here, short and long-term fluctuations exist and confidence intervals need to be validated. Finally, a uniform consensus regarding the most appropriate summary measures remains to be estab-

lished. One could argue that such an indirect measure, relying on assumptions that seem crude, undermines the validity of CSLO data on RNFL thickness. At this point, it is important to highlight that all available clinical methods for measuring RNFL are based on assumptions and approximations that introduce at least some error into the RNFL thickness measurement.

**Optical coherence tomography :**

Optical coherence tomography,

shown in Fig. 6, is a new imaging technique analogue to ultrasound B-scan that can provide cross sectional images of the retina with micrometer scale resolution. It is a non-invasive imaging of high resolution of human retina [Soliman MA, et al., 2002]. Optical coherence tomography uses low-coherence or white light interferometry to perform high-resolution range measurement and imaging. Optical coherence Tomography (OCT) is a high resolution technique that can create cross sectional images of the NFL, as shown in Fig. 5. It provides higher resolution in the axial dimension and better sectioning capability than the HRT. It provides images with high resolution in both axial and lateral dimension and do not require direct contact with the eye. It uses an infrared (850 nm) super-luminescent diode light. In the evaluation of glaucoma, OCT is used to create cylindrical sections of the retina around the optic nerve. A circle diameter 3.4 mm is scanned for this purpose, producing the most reproducible data of the diameter tested with most of the retina composed of NFL at this distance from the ONH and large

enough to avoid the ONH and peripapillary atrophy in nearly all discs [Schuman J and Kim J, 2000].

**The advantages of this instrument are as follow:**

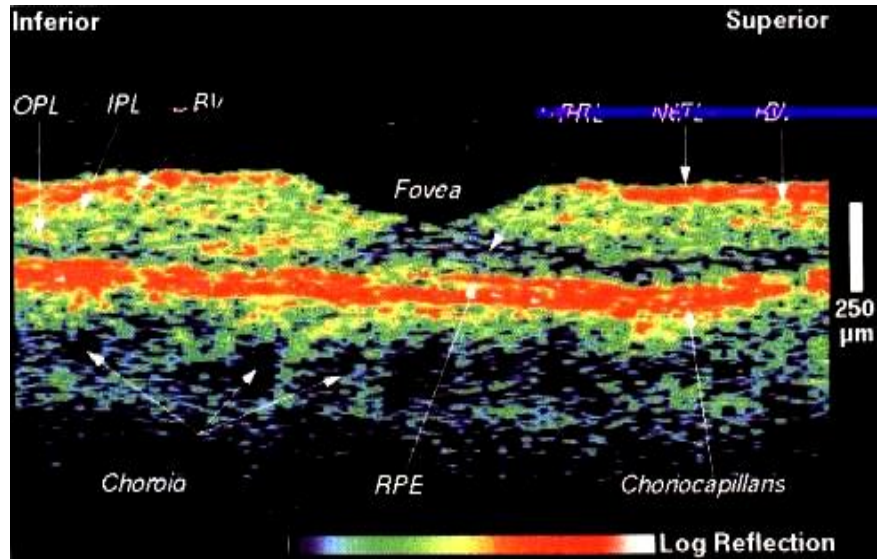
- No reference plane is required to determine NFL thickness because OCT provides an absolute cross sectional measurement of retinal substructure from which the RNFL is calculated.
- It is not affected by the refractive state of the eye or the axial length of the eye, nor is it affected by changes in nuclear sclerotic cataract density or similar media opacities.

**The disadvantages of this instrument are as follow:**

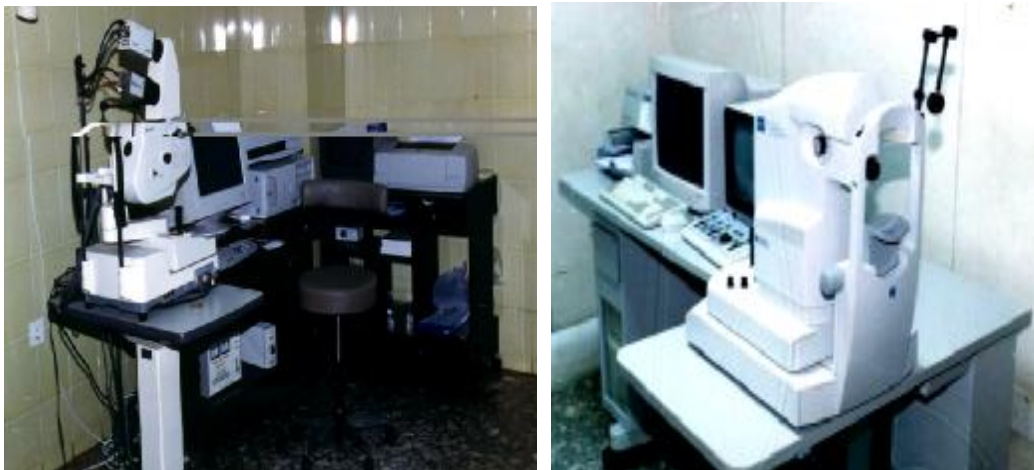- It requires pupillary dilatation.
- Posterior subcapsular and cortical cataracts impair the ability to perform OCT [Kesen MR, et al., 2002].

**The Proposed Methodology :**

Cases of primary open angle glaucoma (POAG) attending the outpatient clinic of the Ophthalmic Department of Ohud Hospital, Al-Madinah Al-Munawwarrah,



**Fig. 5:** Normal OCT of human retina (Carmen, 1999).



**Fig. 6 :** Fundus camera instrument (left) and Optical coherence tomography instrument (right).

KSA throughout the year 2008 were included in this study.

**Diagnosis of POAG was based on the following criteria:**

1. An open angle of the anterior chamber gonioscopically.
2. Glaucomatous visual field changes in the form of:
  - Reproducible defects of 10 dB in more than 2 contiguous points or 5 dB in more than 3 contiguous points in the Bjerrum zone or.
  - Difference of more than 10 dB across the nasal horizontal meridian at more than contiguous points.
3. Intraocular pressure (IOP) of more than 21 mmHg or IOP less than 21 mmHg when associated with suspicious optic disk changes.

**All subjects were subjected to the following:**

1. Visual acuity testing and refraction.
2. IOP measurement using Goldmann applanation tonometry.
3. Slit-lamp biomicroscopy of the anterior segment of the eye.
4. Ophthalmoscopy for fundus and optic disk evaluation.

5. Visual field examination using Humphrey Field Analyzer (central 24-2 threshold test program).
6. Fundus photography both grayscale and coloured photos using Topcon digital fundus camera.
7. Measurement of cup/disk ratio using spectral domain OCT instrument.
8. Measurement of all optic disk parameters using HRT machine (Heidelberg Engineering GmbH, Dossenheim, Germany).

All fundus photos obtained were subjected to the proposed software program & compared to the results of OCT and HRT instruments with statistical analysis.

Digital image analysis is an active area of research for more than three decades in the computer science and engineering fields. Many techniques were established for image enhancement, filtering, segmentation, and measurements of areas of interest in digital images [M. G.H. Mostafa, et al., 2001]. In this research we used three popular segmentation methods for the analysis and determination of the



optic disk in glaucomatous patients. Our methodology can be summarized in the following steps:

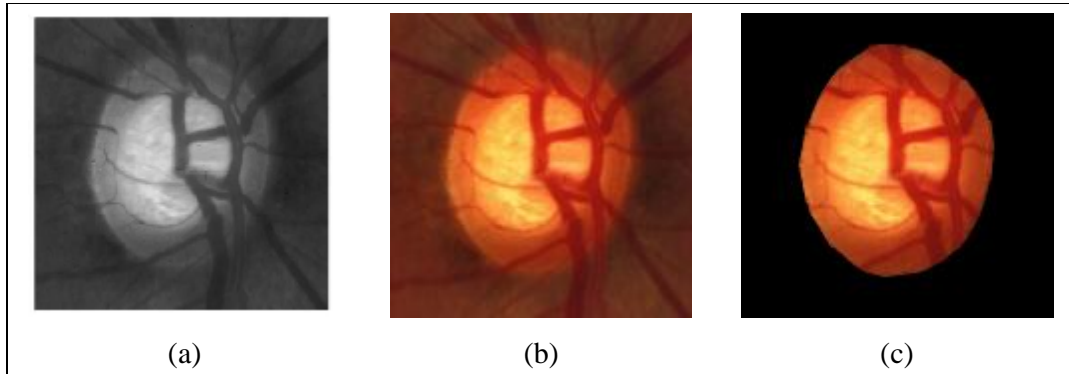
1. Image enhancements: Images are preprocessed for enhancement
2. Image segmentation using three methods [J. C. Bezdek, et al., 1992 - Mostafa G.-H. Mostafa, et al., 2000 - R. Smolikova, et al., 2000 & Tarek F. Gharib and Mostafa G.-H. Mostafa, 2002]:
  - a. Neural Networks
  - b. Statistical Decision Theory (Mixtures Models)
  - c. Fuzzy c-Mean
3. Measuring the region of interest (ROI) of the optic disk and the cup with standard techniques [M. G.H. Mostafa, et al., 2001] from the segmented images, and determining the other important measure, e.g. cup to disk ratio, etc.
4. Comparing the results obtained from the three methods with the ground truth measurements using the HRT

and the OCT devices.

### **Medical Image Segmentation**

#### **Methods :**

A wide variety of approaches have been proposed for medical image segmentation. The currently available methods for medical image segmentation can be categorized into classical, statistical, fuzzy, and neural networks techniques. Classical techniques include the use of standard image processing techniques such as thresholding. Statistical techniques are based on modeling the image as a statistical random field, such as Gaussian Mixture model, and then they employ the priori information to estimate such models. Fuzzy techniques utilize the fuzzy set membership function to find the class of each pixel. Neural networks are nonlinear classifiers that use sample patterns to learn the hidden representation (classes) of the data through minimization of an objective function [Duda].



**Fig. 7 :** A fundus camera image for a disk with 0.6 C/D ratio used in testing the proposed methods, the image in (a) grayscale, (b) color formats and (c) color with a mask.

**Results and Discussions**

We implemented the proposed methodology for measuring the cup-to-disk (C/D) ratio and the rim-to-disk (R/D) ratio using fundus camera images of a glaucomatous patient with a ground truth of 60% C/D and 40% R/D ratios. Figure 7 shows the image in grayscale format (Fig. 7-a) and in true color format (Fig. 7-b), and the third image (Fig. 7-c) is the color image with a mask that enclose the disk area only. We implemented the three methods proposed in this work using these three images in order to find which one will give us the best performance. The reason for the masked image is to eliminate the error that arises from the clas-

sification error for the background, as will be discussed later in this section. For the gray scale image we use only the image intensity information, while for the color images we use the color components in the classification.

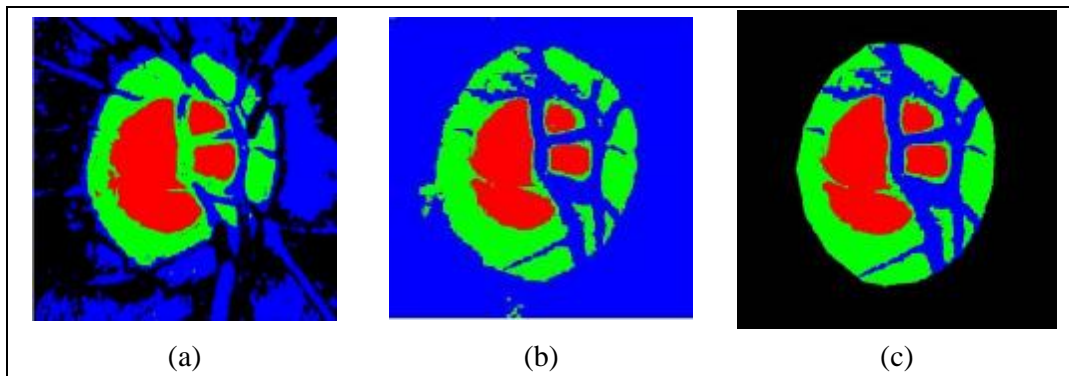
**1. The EM Results**

Figure 8 shows the results of the implementation of the EM segmentation method to the images shown in Fig. 7. The result from the grayscale image is shown in Fig. 8 (a). The error rate obtained by the EM method using the grayscale sample data is 29%. A large area of the background (the retina that surrounding the disk area) and a part of the rim area

are misclassified as blood vessels (the blue color). This is also clear from Table 1, which presents the confusion matrix of the EM classification of the grayscale data. It is seen that the best accuracy (Acc.) and reliability (Rel.) of the method are obtained with the first and the second classes (the cup and the rim areas), while they are low with the other two classes. The C/D ratio measured from the grayscale image is 42% and the R/D ratio is 58%, which give error rate about 30%.

For the color image, a large error rate is obtained in the classification results of the color sample data, about 34 %. The background is completely misclassified

as blood vessels, as shown in Fig. 8 (b). This is also clear from the confusion matrix presented in Table 2. However, the classification results of the blood vessels are much better than that of the grayscale image. This large error rate may be due to the close values of the color components of the blood vessels and the background, which lead to this low performance of the EM in higher dimensions. The measurements results of the disk area are 33 % and 67% for the C/D and the R/D ratios, respectively. Using the masked image, shown in Fig. 8 (c), allows us to consider the blood vessels in the measurements, which improves the ratios to 45% and 55%, respectively.



**Fig. 8 :** The classification results of the EM method for the images in Fig. 7, (a) result of grayscale, (b) result of color, and (c) result of color with mask.

The EM is found to be the slowest algorithm in training and its convergence greatly depends on the initial values for the class centers and classification.

**Table 1: The confusion matrix of the classification results of the EM method for the grayscale image.**

	C1	C2	C3	C4	Acc.
C1	38	3	0	0	93
C2	0	43	6	1	86
C3	0	7	29	15	57
C4	0	0	26	29	53
Rel.	100	81	48	64	72

**Table 2: The confusion matrix of the classification results of the EM method for the color image.**

	C1	C2	C3	C4	Acc.
C1	34	7	0	0	83
C2	0	48	2	0	96
C3	0	2	49	0	95
C4	0	2	53	0	0
Rel.	100	81	47	0	69

## 2. The FCM results

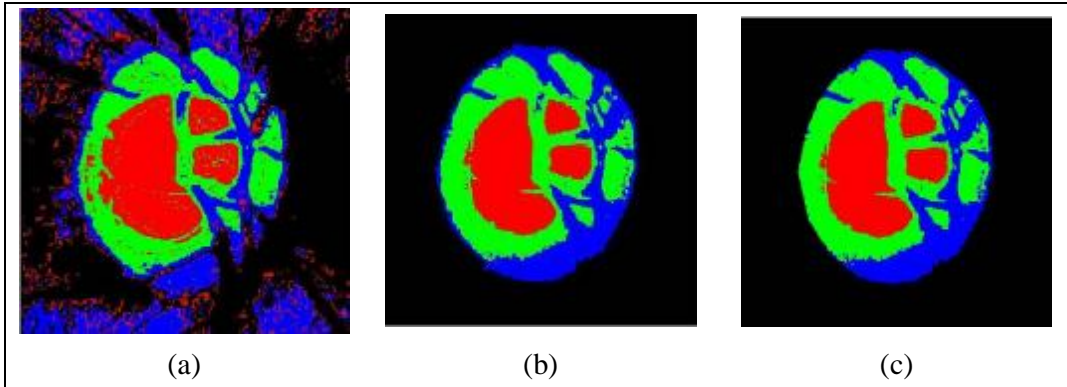
Results of the Fuzzy c-Mean (FCM) classification method are shown in Fig. 9. The classification result of the grayscale image is shown in Fig. 9 (a). The error rate obtained by the FCM method using the grayscale sample data is about 34%. Generally, the classification results of the EM method are found to be better than that of the FCM except for the background. The performance of FCM method is much better in classifying the background, especially for the color image. The cup area is detected completely but some of the rim area is also classified as blood vessels. Table 3 presents the confusion matrix of the FCM classification of the grayscale data. It is seen that the best accuracy and reliability of the method are obtained with the first and the fourth classes (the cup and the background areas), while they are low with the other two classes. The C/D ratio measured from the grayscale image is 55% and the R/D ratio is 45%, which give 10% error rate.

For the color image, despite the large error obtained in the classifi-

cation results of the color sample data, about 21 %, the classification results are much better than that of the grayscale image. This large error rate is due to the misclassification of the blood vessels, which is classified as background, as shown in Fig. 9 (b) and also it is clear from the confusion matrix presented in Table 4. However, the algorithm results for the classification of the disk area is very good, where the C/D and the R/D ratios for the color image are about 40 % and 60%, respectively, and 34 % and 66%, respectively, for the masked color image, shown in Fig. 9 (c).

## 3. The Neural Networks Results:

The best configuration of a neural networks (NN) that gave us the best performance is a two-layer feedforward networks with structure 3-10-4-1 (input - first hidden - second hidden - output) for the color images and 1-10-4-1 for the grayscale images. The activation functions are tangent sigmoidal functions for the first hidden layer, logarithmic sigmoidal functions for the second hidden layer, and a linear function for the output layer. The learning algo-



**Fig. 9 :** The classification results of the FCM method for the images in Fig.10, (a) result of grayscale, (b) result of color, and (c) result of color with mask.

**Table 3: The confusion matrix of the classification results of the FCM method for the grayscale image.**

	C1	C2	C3	C4	Acc.
C1	38	3	0	0	93
C2	1	35	14	0	70
C3	1	7	23	20	45
C4	10	0	10	35	64
Rel.	76	78	49	64	68

**Table 4: The confusion matrix of the classification results of the FCM method for the color image.**

	C1	C2	C3	C4	Acc.
C1	41	0	0	0	100
C2	0	36	14	0	72
C3	0	9	24	18	47
C4	0	0	0	55	100
Rel.	100	80	63	75	80

rithm used is the Levenberg-Marquardt algorithm. Finally, the learning parameter ( $\eta$ ) = 0.1 and the learning rate ( $\theta$ ) = 0.1.


Figure 10 shows the classification results of the adopted neural networks (NN) for the images in Fig. 7. The classification of the grayscale image is shown in Fig. 10 (a). The error rate obtained by the NN method using the grayscale sample data is about 19% for the training and 36% for the testing samples. The training error is the lowest compared to that obtained by the EM or the FCM methods. Table 5 and Table 6 present the confusion matrices of the NN classification of the training and testing grayscale sample data. It is seen that the best accuracy and reliability of the method are obtained with the first and the fourth classes (the cup and the background areas), while they are low with the other two classes. The C/D and the R/D ratios measured from the grayscale image are 50% and 50%, which give 17% error rate.

The best classification results are obtained by the NN classifier

for the color image, as shown in Fig. 9 (a). The obtained error rate is 0% and 13 % for the training and the test samples, respectively. This is also obvious from the confusion matrices presented in Table.7 and Table 8, which show an overall accuracy of 100% and 99% for the training and test samples, respectively. The C/D and the R/D ratios for the color image are 33% and 67%, respectively, and 46% and 54%, respectively, for the masked color image, shown in Fig. 10 (c). The neural network is found to be slow in the learning mode; however it is the fastest method in the testing mode. This result indicates that error in the measurement of the C/D ratio is about 33%, which is comparable to that obtained from the HTR and OCT devices [M. G.-H. Mostafa, et al., 2003].

### **Conclusion and Future Work**

In this research, we proposed to use fundus digital images to measure the cup-to-disk (C/D) ratio in glaucomatous patients, since evaluation of the optic disk changes that occur in glaucoma patients including cup/disk ratio,



**Fig. 10 :** The classification results of the neural networks method for the images in Fig.10, (a) result of grayscale, (b) result of color, and (c) result of color with mask.

**Table 5: The confusion matrix of the classification results of the NN method for the training grayscale data.**

	C1	C2	C3	C4	Acc.
C1	41	0	0	0	100
C2	0	30	20	0	60
C3	0	3	38	10	75
C4	0	0	5	50	91
Rel.	100	91	60	83	81



**Table 6: The confusion matrix of the classification results of the NN method for the testing grayscale data.**

	C1	C2	C3	C4	Acc.
C1	38	3	0	0	93
C2	0	24	25	1	48
C3	0	5	28	18	55
C4	0	0	18	37	67
Rel.	100	75	39	66	66

**Table 7: The confusion matrix of the classification results of the NN method for the training color data.**

	C1	C2	C3	C4	Acc.
C1	41	0	0	0	100
C2	0	50	0	0	100
C3	0	0	51	0	100
C4	0	0	0	55	100
Rel.	100	100	100	100	100

**Table 8: The confusion matrix of the classification results of the NN method for the testing color data.**

	C1	C2	C3	C4	Acc.
C1	39	2	0	0	95
C2	1	47	1	1	94
C3	0	5	46	0	90
C4	0	1	14	40	73
Rel.	98	85	75	98	88

rim/disk ratio, cup volume and other parameters needs usually an expensive, evolving technology, e.g. HRT and OCT, which limits their availability as well as their usefulness as applied to patients with common, widespread chronic illnesses such as glaucoma.

We implemented three different image analysis methodologies: Expectation Maximization (EM), Fuzzy c-Mean (FCM), and Neural Networks (NN). We used the three methods to segment both digital intensity and color images taken from a relatively inexpensive commonly used fundus camera. Then, we use these segmented images to measure the optic disk and the cup, from which we measure other important factors, e.g. cup-to-disk ratio, rim-to-disk ratio.

Results show that the EM and the NN methods produce good results for both intensity (grayscale) and color images, while FCM method gives the lowest performance for both images. The error rate of the proposed methods, about 33%, is comparable to the expected error from the HRT and

the OCT devices [E.Z. Blumenthal and R. N. Weinreb, 2001].

In future work, we plan to employ segmentation techniques that takes into account the geometry of the image, e.g to employ edge detection and detect conic shape, to be able to localize both the disk and the cup more efficiently.

### References

**Anderson D. R. and Caprioli J. (1995)** : The optic nerve in glaucoma, in Jaeger E (ed): *Duane's Clinical Ophthalmology*, Vol 3. Philadelphia, Lippincott-Raven., chap 48.

**Carpineto P., Ciancaglini M., Zuppari E., et al., (2003)** : Reliability of nerve fiber layer thickness measurements using optical coherence tomography in normal and glaucomatous eyes. *Ophthalmology* 110:190-5.

**Choplin N. T. and Lundy D. C. (2001)** : The sensitivity and specificity of scanning laser polarimetry in the detection of glaucoma in a clinical setting. *Ophthalmology* 108:899-904.

- Correnti A. J., Wollstein G., Price L. L., et al., (2003)** : Comparison of optic nerve head assessment with a digital stereoscopic camera (discam), scanning laser ophthalmoscopy, and stereophotography. *Ophthalmology* 110: 1499-505.
- E.Z. Blumenthal and R. N. Weinreb. (2001)** : Assessment of the Retinal Nerve Fiber Layer in Clinical Trials of Glaucoma Neuroprotection SURVEY OF OPHTHALMOLOGY. vol. 45 (3).
- Gupta N. and Weinreb R. N. (1997)** : New definitions of glaucoma. *Curr Opin Ophthalmol* 8:38-41
- Hitching R. A., Genio C., Anderton S. and Clark P. (1983)** : An optic disc grid: Its evaluation in reproducibility studies on the cup/disc ratio. *Br. J. Ophthalmol.*; 67: 356.
- Iester M., Mikelberg F. S., Courtright P., Burk R. O. W., Caprioli J., Jonas J. B., Weinreb R. N. and Zangwill L. (2001)** : Interobserver variability of optic disc variables measured by confocal scanning laser tomography. *Am. J. Ophthalmol.*; 132 : 57-62.
- J. C. Bezdek and S. K. P al. (1992)**: Fuzzy Model for Pattern Recognition. IEEE, Piscataway, NJ.
- Kamal D. S., Garway-Heath D. F., Hitchings R. A., et al., (2000)** : Use of sequential Heidelberg retina tomography images to identify changes at the optic disk in ocular hypertensive patients at risk of developing glaucoma. *Br J Ophthalmology* 84:993-8.
- Kesen M. R., Spaeth G. L., Henderer J. D., et al., (2002)** : The Heidelberg Retina Tomograph vs clinical impression in the diagnosis of glaucoma. *Am J Ophthalmol* 133:613-6.
- Lan Y. W., Henson D. B. and Kwartz A. J. (2003)** : The correlation between optic nerve head topographic measurements, peripapillary nerve fibre layer thickness, and visual field indices in glaucoma. *Br J Ophthalmol* 87:1135-41.
- Lee B. L., Bathija R. and Weinreb R. N. (1998)** : The defini-

tion of normal tension glaucoma. J Glaucoma 7:366-71.

**M. G. H. Mostafa M. F. Tolba, T. F. Gharib and M. A. Megeed (2003)** : "Mr-Brain Image Segmentation Using Gaussian Multi-resolution Analysis And The Em Algorithm." Proceedings of International Conf. On Enterprise Information Systems - ICEIS2003, France.

**M. G. H. Mostafa, M. F. Tolba, T. F. Gharib and M. A. Megeed (2001)** : "Medical Image Segmentation Using a Wavelet-Based Multiresolution EM Algorithm." Proceedings of the Int. Conf. on Industrial Electronics, Technology & Automation (IETA 2001). 19-12 Dec., Cairo. Egypt.

**Mardin C. Y., Hothorn T., Peters A., et al., ( 2003)** : New glaucoma classification method based on standard Heidelberg Retina Tomograph parameters by bagging classification trees. J Glaucoma 12:340-6.

**Mostafa G. H. Mostafa, Timothy C. Perkins, and Aly A. Farag, (2000)** : "A Two-Step Fuzzy-

Bayesian Classification for High Dimensional Data." Proceedings of the IAPR International Conference on Pattern Recognition (ICPR), Barcelona, Spain, Vol. 3, pp.421.

**Musch D. C., Lichter P. R., Guire K. E., et al., ( 1999)** : The Collaborative Initial Glaucoma Treatment Study: study design, methods, and baseline characteristics of enrolled patients. Ophthalmology 106:653-62.

**R. C. Gonzalez and R. E. Woods, (2002)** : Digital Image Processing, 2nd ed., Prentice Hall.

**R. Smolikova, Mostafa G.-H. Mostafa, J. M. Zurada, and A. A. Farag. (2000)** : "Classification of Multispectral Data Using Fuzzy Neural Networks." Computational Intelligence New Trends and Approches in Computational Intelligence. P. Suncak and J. Vascak (eds.). Physica-Verlag, A Springer-Verlag Company, pp. 426.

**Schuman J. and Kim J. (2000)** : Imaging of the optic nerve head and nerve fiber layer in glaucoma. Ophthalmology Clinics of North America; 13: 383-406.

**Sihota R., Gulati V., Saxena R., et al., (2003)** : Correlation between confocal scanning laser ophthalmoscopy and scanning laser polarimetry in open angle glaucoma. Eur J Ophthalmol 13:266-75.

**Soliman M. A., Van Den Berg T. J., Ismaeil A. A., et al., (2002)** : Retinal nerve fiber layer analysis : relationship between optical coherence tomography and red-free photography. Am J

Ophthalmol 133:187-95.

**Tarek F. Gharib and Mostafa G. H. Mostafa. (2002)** : "Data Clustering Using a Two-Stage Fuzzy and Sequential K-means Algorithms." The International Conference on Artificial Intelligence - IC-AI'02: Las Vegas, USA, June 24-27.

**User Guide (2001)** : Neural networks Toolbox, The Mathworks Inc.

REPRINT

# **BENHA MEDICAL JOURNAL**

**A COMPUTER SOFTWARE SYSTEM  
FOR MEASURING SIZE CHANGES IN  
OPTIC DISK IN PATIENTS  
WITH GLAUCOMA**

**Mostafa G. M. Mostafa MD, Abdullah M. Albinali MD  
and Nashaat S. Ibrahim MD**

**Published by  
Benha Faculty of Medicine**

*Volume 26 Number 3  
Sept. 2009*

## **COMPARATIVE STUDY BETWEEN OPTICAL COHERENCE TOMOGRAPHY AND HEIDELBERG RETINAL TOMOGRAPHY IN PATIENTS WITH PRIMARY OPEN ANGLE GLAUCOMA**

**Nashaat Sh. Zaki MD**

*Department of Ophthalmology, Faculty of Medicine,  
Mansoura University, Egypt*

### **Abstract**

**Purpose:** *To compare between Heidelberg retinal tomography (HRT) and optical coherence tomography (OCT) in diagnosis and follow up of patients with primary open angle glaucoma (POAG).*

**Patients and Methods:** *This study included 80 eyes of 45 patients (20 males, 25 females) between the age of 45 and 65 years. Eyes were divided into 2 equal groups of similar age and sex: Group 1 (control group), included 40 eyes of 20 subjects with negative family history of glaucoma, IOP less than 21 mmHg, normal looking optic disc on fundus examination, visual field results within normal and refraction within  $\pm 2.0$  diopters. While group 2, included 40 eyes of 25 patients (15 bilateral & 10 unilateral cases) diagnosed as POAG and their refraction was within  $\pm 3.0$  diopters. All eyes underwent visual field assessment using Humphrey field analyzer, measurement of retinal nerve fiber layer (RNFL) thickness using OCT (the average reading of 3 successive scans was taken). Also HRT testing for assessment of various optic disk parameters was carried out for 3 tests (one baseline and 2 follow up tests) with an interval of 6 months between each visit. Results were recorded and statistically analyzed.*

**Results:** *The mean RNFL thickness values of both groups were compared. The glaucoma group values were found to be significantly less than that of the control group in clock hour distribution, in all 4 quadrants and also in the average overall value. ( $P < 0.001$ ). The mean value of each of the 8 main HRT parameters showed significant differences between the glaucoma and the control groups ( $P < 0.01$ ). While there was no statisti-*

*cally significant difference between base line value and follow up visits regarding all HRT main parameters. ( $P > 0.05$ )*

**Conclusions:** *OCT can be used in early detection of glaucomatous optic disk structural changes rather than HRT. The most significant use of HRT is in the follow up of glaucoma to detect glaucomatous changes over-time. Both are valuable tools in addition to clinical examination in diagnosis and follow up of glaucoma cases.*

### **Introduction**

Primary open angle glaucoma (POAG) is still one of the major causes of blindness in the world. It involves progressive retinal ganglion cell death which is detectable clinically as a structural changes of the optic disc or as a loss of retinal nerve fiber layer (RNFL) reflectivity, particularly when using blue or green light ophthalmoscopy. It is important to use objective quantitative measurements for detection of these changes and help to discriminate normal from glaucomatous conditions. (Miglior S, et al., 2001)

Because RNFL and optic disc damage have been shown to precede visual field loss, objective methods of measuring them may help physicians to diagnose and monitor primary open angle glaucoma. (Zangwill LM, et al., 2001)

Recent methods, such as optical coherence tomography (OCT) and Heidelberg retinal tomography (HRT), have been developed as a quantitative methods evaluating the optic disc and retinal nerve fiber layer (RNFL).

Optical Coherence Tomography (OCT) is a technology that permits high resolution cross sectional imaging of biological tissue using light. OCT enables non-contact and non-invasive imaging of the optic nerve head (ONH) and nerve fiber layer (NFL). OCT is used to create cylindrical sections of the retina around the optic nerve. A circular diameter of 3.4 mm is scanned for this purpose; the circular scan results in the cylindrical retinal cross-section. OCT is therefore a means of both imaging the NFL and directly quantitating NFL thickness. (Hee MR, et al., 1995).



The Heidelberg Retina Tomography (HRT) is a scanning laser ophthalmoscope that uses diode laser with wave length of 670 nm for the analysis of a three dimensional topographic image of the optic disc. HRT also determines the height of the RNFL in relation to a topographic reference plane. (Rohrschneider K, et al., 1994).

Many investigators had documented the ability of OCT to differentiate between normal and glaucomatous eyes and its role in early detection of glaucoma. (Badie OA, et al., 2001) Also, previous reports indicate that HRT is of great value for follow up of changes in ONH. (Weinreb RN, 1994 & Zangwill LM, et al., 2001).

This study aims to compare between the actual role of OCT versus HRT in diagnosis and follow up of early glaucomatous patients.

### **Patients and Methods**

This study included 80 eyes of 45 patients (20 males, 25 females) between the age of 45 and 65 years attending the outpatient clinic of Mansoura Ophthalmic Center, during the years 2003 &

2004. Eyes were divided into 2 equal age and sex matched groups: Group 1 (control group), included 40 eyes of 20 subjects with negative family history of glaucoma, IOP less than 21 mmHg, normal looking optic disc on fundus examination, visual field results within normal and refraction within  $\pm$  2.0 diopters. While group 2, included 40 eyes of 25 patients (15 bilateral & 10 unilateral cases) diagnosed as POAG and their refraction was within  $\pm$  3.0 diopters.

### **Diagnosis of POAG was based on the following criteria:**

- 1)- An open angle of the anterior chamber on gonioscopic examination.
- 2)- Glaucomatous visual field changes in the form of:
  - \* Reproducible defects of 10 dB in more than 2 contiguous points or 5 dB in more than 3 contiguous points in the Bjerrum zone or.
  - \* Difference of more than 10 dB across the nasal horizontal meridian at more than 2 contiguous points.
- 3)- Intra-ocular pressure (IOP) more than 21 mmHg or IOP less

than 21 mmHg when associated with suspicious optic nerve head changes.

**All subjects were subjected to:**

a)-Visual acuity testing using Snellen chart and automated refraction using Canon autorefractometer R 50, gonioscopy for visualization of the angle structure and width using Goldmann 3-mirror contact lens, ophthalmoscopy for assessment of glaucomatous optic disk changes, IOP measurement using Goldmann applanation tonometer, visual field examination by Humphrey field analyzer (using central 24-2 threshold test program).

b)- Measurement of RNFL thickness using Zeiss Humphrey OCT software. The retinal examination with OCT is performed in a manner similar to slit-lamp indirect ophthalmoscopy, with the restriction that the condensing lens is mounted and fixed along the slit-lamp optical axis. After the pupil is fully dilated, patients fixed internal blinking green light. A Volk lens of +78.0 D was used to focus the beam through the pupil

onto the retina. The viewing unit is moved towards the eye until the retinal image fills the video monitor. The optimal distance between the lens and eye is 9 mm. A circle diameter of 3.4 mm was centered on the optic disc. This diameter was selected because it was large enough to avoid overlap with the ONH in nearly all eyes and allowed measurement of RNFL in a thicker area than the 4.5 mm diameter circle.

The average reading of 3 successive scans was calculated and the image was displayed "unwrapped" as a flat image on the page. The values of RNFL thickness was expressed in 2 clocks, one representing the average thickness over quadrants and the other representing the average thickness over each clock hour (Fig. 1). Scanning always starts at 9 o'clock and progresses clockwise so that in the right eye it starts temporally and in the left eye it starts nasally.

c)- HRT testing for 3 tests (one baseline and 2 follow, up tests) with an interval of 6 months using HRT II machine (Heidelberg Engi-

neering GmbH, Dossenheim, Germany) was done for all patients. To ensure stable disc area in all the tests, contour lines were imported from the base line test and exported to the follow up tests. The main outcome parameters were collected and changes in the 2 follow up tests were calculated and statistically analyzed.

**Statistical analysis:**

Student t test was used to compare the mean OCT values of the normal and glaucoma groups and also to compare the difference in HRT parameters in normal and glaucoma groups.

**Results**

The present study included 80 eyes of 45 patients between the age of 45 and 65 years. Eyes were divided into 2 groups (control and glaucoma groups) of similar age and sex, each group included 40 eyes. The mean RNFL thickness values of both groups were compared. The glaucoma group values were found to be significantly less than that of the control group in all quadrants and in the average value. ( $P < 0.001$ ) (Table 1).

Analysis of HRT testing in glaucomatous patients (group 2) showed the following changes in the main 8 HRT parameters:

1- Rim area: in the 1st follow up visit decreased in (25 eyes) 62.5 % of eyes and in the 2nd follow up visit there was further decrease in (13 eyes) 32.5 % of eyes.

2- Rim volume: in the 1st follow up visit decreased in (18 eyes) 45.0 % of eyes with further decrease only in (4 eyes) 10% of eyes in the 2nd follow up visit.

3- Mean RNFL thickness: in the 1st follow up visit decreased in (20 eyes) 50.0% of eyes and in the 2nd follow up visit there was further decrease in (11 eyes) 27.5% of eyes.

4- Cup area: in the 1st follow up visit increased in (22 eyes) 55.0% of eyes and in the 2nd follow up visit there was further increase in (13 eyes) 32.5 % of eyes.

5- C/D area ratio: in the 1st follow up visit in-

creased in (25 eyes) 62.5% of eyes and in the 2<sup>nd</sup> follow up visit there was further increase in (12 eyes) 30 % of eyes.

6- Cup volume: in the first follow up visit increased in (30 eyes) 75.0 % of eyes and in the second follow up visit there was further increase in (9 eyes) 22.5 % of eyes.

7- Mean cup depth: in the 1st follow up visit increased in (21 eyes) 52.5% of eyes and in the 2nd follow up visit there was further increase in (8 eyes) 20% of eyes

8- Cup shape measure: showed a decrease (less steepening) in (28 eyes) 70.0 % of eyes in the first follow up visit while only (14 eyes) 35 % of eyes showed more steepening.

The mean value of each of the 8 main HRT parameters showed significant differences between the glaucoma and the control groups ( $P < 0.01$ ) (Table 2). Statistical analysis of the resulting difference in all the 8 main parameters, between base line and follow up HRT visits showed no statistically significant difference. ( $P > 0.01$ ) (Table 3).

**Table (1) :** NFL thickness in normal and glaucomatous eyes measured by OCT in various quadrants.

Measurement	Control group (µm)	Glaucoma group (µm)	P value
Superior	148 ± 14	116 ± 24	0.0001*
Inferior	146 ± 18	109 ± 33	0.0001*
Temporal	106 ± 11	82 ± 11	0.0004*
Nasal	112 ± 26	85 ± 17	0.0002*
Mean NFL quadrants	128 ± 17	98 ± 21	0.0001*

\* = Significant ( $P < 0.001$ ).

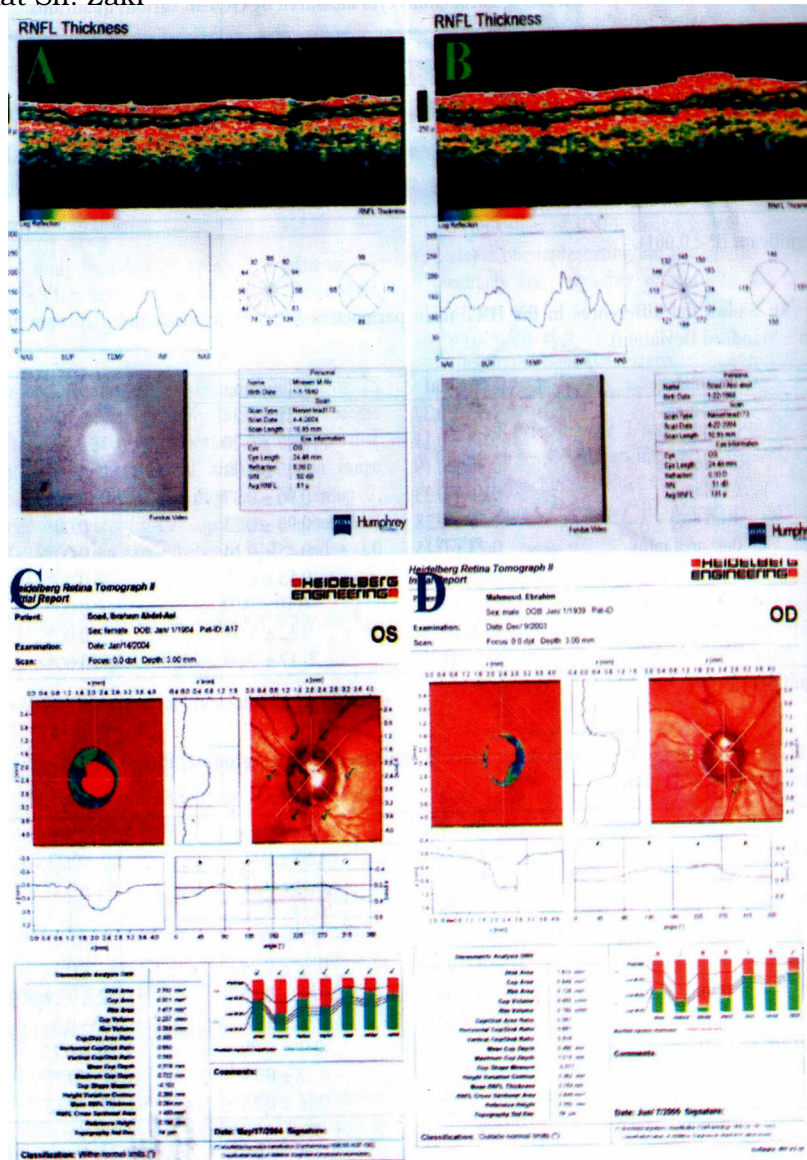
**Table (2):** Shows the differences in the HRT main parameters between control and glaucoma group (Mean + Standard Deviation).

Parameter	Normal	Glaucoma	P value
Disk area	1.92 ± 0.34	1.86 ± 0.36	0.16
Cup volume	0.09 ± 0.12	0.24 ± 0.22	< 0.00*
Rim volume	0.38 ± 0.18	0.16 ± 0.07	< 0.00*
Cup area	0.48 ± 0.35	0.98 ± 0.35	< 0.00*
Rim area	1.54 ± 0.27	0.95 ± 0.26	< 0.00*
Cup-disk area ratio	0.21 ± 0.18	0.44 ± 0.16	< 0.00*
Mean cup depth	0.26 ± 0.25	0.55 ± 0.28	< 0.00*
Cup shape measure	-0.19 ± 0.08	-0.11 ± 0.06	< 0.00*
Hight variation contour	0.37 ± 0.17	0.33 ± 0.09	< 0.00*
Mean RNFL thickness	0.28 ± 0.08	0.16 ± 0.08	< 0.00*

• = significant

**Table (3):** Changes in the HRT main parameters in glaucomatous eyes (group 2) during follow up visits : (Mean + Standard Deviation).

Parameter	Base line visit	1 <sup>st</sup> follow up visit	2 <sup>nd</sup> follow up visit
Disk area	1.86 ± 0.36	1.85 ± 0.44	1.89 ± 0.24
Cup volume	0.24 ± 0.22	0.34 ± 0.26	0.42 ± 0.27
Rim volume	0.16 ± 0.07	0.14 ± 0.13	0.12 ± 0.22
Cup area	0.98 ± 0.35	1.14 ± 0.42	1.28 ± 0.37
Rim area	0.95 ± 0.26	0.86 ± 0.26	0.81 ± 0.42
Cup-disk area ratio	0.44 ± 0.16	0.48 ± 0.23	0.54 ± 0.26
Mean cup depth	0.55 ± 0.28	0.62 ± 0.23	0.65 ± 0.31
Cup shape measure	-0.11 ± 0.06	-0.09 ± 0.08	-0.07 ± 0.13
Hight variation contour	0.33 ± 0.09	0.27 ± 0.13	0.23 ± 0.28
Mean RNFL thickness	0.16 ± 0.08	0.14 ± 0.16	0.11 ± 0.14



**Fig. (1) :** A) OCT circular scan around the disc, shows normal NFL at all quadrants (control group). B) OCT circular scan around the disc shows RNFL thinning at all quadrants (glaucoma group). C) HRT II report shows high variation contour and RNFL thickness within normal limits. D) HRT II report shows height variation contour and RNFL thickness outside normal limits.

### Discussion

Glaucoma frequently produces clinically detectable tissue damage in the optic nerve head and the RNFL. Several studies have found a close relationship between structural changes of the RNFL and the optic nerve head in glaucomatous eyes (Bid TM, et al., 1997).

Although most new technologies concentrate on assessing changes at the optic nerve head, those that allow measurement of the RNFL next to the optic disc offer several potential advantages. Compared with the optic nerve head, axons in the retina are spread out in a thin layer. This suggests that examination of the RNFL will be more sensitive to minor losses of axons than evaluating the optic nerve head (Schuman JS, et al., 2003).

This study could prove a statistically significant difference in RNFL thickness between normal and glaucomatous eyes by using OCT. This is parallel to several studies that documented the ability of OCT to differentiate between normal and glaucomatous eyes.

(Zangwill LM, et al., 2001) The study also provided diagnostic values for all quadrants helping to differentiate glaucomatous from normal subject.

Measurement of RNFL thickness by OCT is useful in detecting early RNFL damage. Furthermore, OCT measurements of RNFL thickness may provide clinically relevant information in monitoring glaucomatous changes. (Kenamori A, et al., 2003)

In the present study, the mean value of each of the 8 main HRT parameters showed significant differences between the glaucoma and the control groups. Also, statistical analysis of the resulting difference in all the 8 main parameters, between base line and follow up HRT visits showed no statistically significant difference.

These results are in agreement with the results of several investigators who proved the value of HRT in diagnosis and follow up of those suspected of having glaucoma however, they mentioned that the instrument and the technique requires further refinement to be

more useful.( Weinreb RN, 1995 & Kamal DS, et al., 2000)

The ONH and RNFL imaging devices provide quantitative information for the clinician. Based on studies that have compared the various available technologies directly, there is no single imaging device that outperforms the others in distinguishing patients with glaucoma from controls. Ongoing advances in imaging and related software, as well as the impracticalities associated with obtaining and assessing optic nerve stereophotographs, have made imaging increasingly important in many practice settings. The information obtained from imaging devices is useful in clinical practice when analyzed in conjunction with other relevant parameters that define glaucoma diagnosis and progression. (Shan CL, et al., 2007)

Now it is mostly established that the most significant potential use of HRT is to recognize progression of glaucomatous damage rather than diagnosing glaucoma. Although, HRT can also help in early detection of POAG but its value as a one-time definitive test

for diagnosing glaucoma is uncertain. This is because of some drawbacks. Firstly, manual determination of the disc in HRT gives a chance for error. Also, many clinical features of optic disc which help to make a diagnosis of glaucoma can not be captured in numerical indices, such as color of the disc and alteration in the blood vessel pattern. Moreover, examination of the RNFL is more sensitive to minor losses of axons than evaluating the optic nerve head and about 16% of cases with early V.F changes can not be diagnosed by this technique (Chauhan BC, 2003)

### **Conclusion**

OCT can provide accurate, objective and quantitative measurements of RNFL thickness. OCT can be used in early detection of glaucomatous changes rather than HRT. The most significant use of HRT is in the follow up of glaucoma rather than diagnosing early glaucoma.

However, clinical and therapeutic decisions can not be based only on OCT and HRT but in conjunction with other perimetric and



clinical methods of examination which remain reliable methods for diagnosis.

### References

**Badie O. A., Shoir A. T. and Taha R. H. (2001)** : Assessment of the retinal nerve fiber layer thickness in normal and glaucomatous eyes using Optical Coherence Tomography. Bull. Ophthalmol Soc. Egypt; 94: 347.

**Bid T. M., Spaeth G. L., Katz L. J., Azuara-Blanco A., Agudburger J. and Nicholl J. (1997)** : Quantitative estimation of retinal nerve fiber layer height in glaucoma patients and relationships with optic nerve head photography and visual field. J Glaucoma; 6: 221-230.

**Chauhan B. C. (2003)** : Quantitative imaging of the optic disc. In Glaucoma: Science and practice. Edited by Morrison JC and Pollack IP. Published by Thieme medical publisher, China.; 106-113.

**Hee M. R., Izatt J. A., Swanson E. A., Huang D., Schuman J. S., Lin C. P., Puliafito C. A. and**

**Fujimoto J. G. (1995)** : Optical Coherence Tomography of the human retina. Arch Ophthalmol.; 113: 325-332.

**Kamal D. S., Garway-Health D. F., Hitchings R. A. and Ritzke F. W. (2000)** : Use of sequential HRT images to identify changes at the optic disc in ocular hypertensive patients at risk of developing glaucoma. Br. J Ophthalmol.; 84: 993-998.

**Kanamori A., Nakamura M., Escano M. F., Seya R., Maeda H. and Negi A. (2003)** : Evaluation of the glaucomatous damage on retinal nerve fiber layer thickness measured by optical coherence tomography. A J Ophthalmol. 135: 513-520.

**Miglior S., Casula M., Guareschi M., Marchetti I., Lester M. and Orzalesi N. (2001)** : Clinical ability of Heidelberg Retinal Tomograph Examination to detect Glaucomatous visual field changes. Ophthalmology; 108: 1621- 1627.

**Rohrschneider K., Burk R. O. W., Kruse F. E. and Volcker H.**

**E. (1994)** : Reproducibility of the optic nerve head topography with a new laser topographic screening device. *Ophthalmology*; 101 : 1044-1049.

**Shan C. L., Kuldev S., Henry D. J., Elizabeth A. H., Scott D. S., Brian A. F., David K. D., Robert D. F., John S. S., Schuman J. S. and Minckler D. S. (2007)** : Optic nerve head and retinal nerve fiber layer analysis. *Ophthalmology*; 114: 1937-1949.

**Schuman J. S., Wollstein G., Farra T., Hertzmark E., Aydin A., Fujimoto J. G. and Paunescu L. A. (2003)** : Comparison of Optic nerve Head Measurements obtained by Optic Coherence Tomog-

raphy and Confocal Scanning Laser Ophthalmoscopy. *Am J Ophthalmol*; 135: 504-512.

**Weinreb R. N. (1995)** : Diagnosing and monitoring glaucoma with confocal scanning LASER ophthalmoscopy. *J Glaucoma*; 4: 225-227.

**Zangwill L. M., Bowd C., Berry C. C., Williams J., Blumenthal E. Z., Sanchez Galeana C. A., Vasile C. and Weinreb R. N. (2001)** : Discriminating between normal and glaucomatous eyes using the Heidelberg Retina Tomograph, GDx, nerve fiber analyzer and optical Coherence Tomograph. *Arch Ophthalmol*; 119: 985-993.

REPRINT

# **BENHA MEDICAL JOURNAL**

**COMPARATIVE STUDY  
BETWEEN OPTICAL COHERENCE  
TOMOGRAPHY AND HEIDELBERG  
RETINAL TOMOGRAPHY IN PATIENTS  
WITH PRIMARY OPEN  
ANGLE GLAUCOMA**

**Nashaat Sh. Zaki MD**

**Published by  
Benha Faculty of Medicine**

*Volume 26 Number 3  
Sept. 2009*

## **SEXUAL DIMORPHISM IN THE LUMBO-SACRAL REGION OF THE ALBINO RAT SPINAL CORD**

**Adel A. Bondok MD, Omar M. Gabr MD,  
Azza R. El-hadedy MD\*, Dalia M. Saleh MD  
and Hassan M. Rezk MD**

*Departments of Anatomy and Histology, Cytology\*,  
Faculty of Medicine, Mansoura Universit , Egypt*

### **Abstract**

*The present study was carried out to investigate the sexual dimorphism in the spinal nucleus of bulbocavernosus (SNB) in the spinal cord of male and female rats and to study the effect of testosterone replacement in castrated adult male rats and testosterone injection in adult female rats.*

*Thirty adult male & female albino rats were used in this study. The males were divided into two groups, control group (6 rats) and experimental group (12 rats). The experimental group was divided into two groups, one group was subjected to bilateral orchidectomy (6 rats) while the other group was subjected to bilateral orchidectomy followed by testosterone propionate injection at regular intervals (6 rats). The females were divided into two groups, control group (6 rats) and experimental group (6 rats). The experimental females were injected with testosterone propionate at regular intervals.*

*Castrated males, testosterone treated castrated males and testosterone treated females and their age matched control groups were sacrificed at 30 and 60 days from the start of the experiment.*

*The lumbosacral region of the spinal cord was processed for Haematoxylin and Eosin stain and immunohistochemical staining with polyclonal antiandrogen receptor primary antibody and the number of SNB was counted using image analyzer.*

*The castrated adult male rats showed decreased number of the SNB motoneurons. Immunohistochemical stained sections showed posi-*

*tive reaction in most of cells examined. However, two months after castration, some cells still showed intense reaction. The castrated and testosterone injected adult male rats showed decreased number of the SNB motoneurons. At age of two months, the rats had nearly half the number of the SNB motoneurons of the control rats. In immunohistochemical stained sections, the SNB motoneurons showed very strong positive reaction in their cytoplasm. The testosterone injected adult female rats showed gradual increase in the number SNB motoneurons than that of the control till reached the highest value at age of two months. Immunohistochemical stained sections showed weak to moderate positive immunohistochemical reaction in the cytoplasm of the SNB motoneurons. Two months after injection, the SNB motoneurons showed strong positive immunohistochemical reaction.*

### **Introduction**

In the beginning of this century, many researchers turned their attention to identify the evidence that sex differences in mammal are caused by the differential representation of sex chromosome genes in the genomes of males and females. However, it has not been considered relevant to theories of sexual differentiation till 1940s when Jost et al. (1973) demonstrated the endocrine control of differentiation of external genitalia and other structures (Arnold, 2002). More recently, several studies have indicated that sex differences are found in tissues prior to gonadal differentiation. Male and female embryos from

several species differ in size at specific gonadal stages, a difference influenced by both X and Y genes in mice (Wilson and Davies, 2007).

Some of the best known neural sex differences include differences in number and size of motoneurons in the spinal cord which often can be linked to well known sex differences in the function of target muscles. In the lumbosacral region of the spinal of the rat, the spinal nucleus of bulbocavernosus (SNB) is visible in males but difficult to detect in females and it innervates muscles that are present at the base of the penis and are absent or

vestigial in females (De Vries, 2004).

The spinal nucleus of bulbocavernosus muscle (SNB) is a group of motoneurons in the L5-S1 spinal cord segments which innervate the perineal muscles implicated in penile erection and genital reflexes (Nagy and Senba, 1985; Tobin and Payne, 1991).

### **Material and Methods**

#### **\* Animals Used:**

Thirty adult male & female albino rats were used in this study. The males were divided into two groups, control group (6 rats) and experimental group (12 rats). The experimental group was divided into two groups, one group was subjected to bilateral orchidectomy (6 rats) while the other group was subjected to bilateral orchidectomy followed by testosterone propionate injection at regular intervals (6 rats). The females were divided into two groups, control group (6 rats) and experimental group (6 rats). The experimental females were injected with testosterone propionate at regular intervals.

#### **\* Castration (Orchidectomy):**

Bilateral orchidectomy was performed. Each rat was anaesthetized with 10% chloral hydrate (300mg/kg, intraperitoneally), a small median incision was made at the distal tip of the scrotum, the testes were exposed and the peritoneal sacs of the testes were incised. Blood vessels and vas deference were ligated then the testes and epididymis were removed. The peritoneal sacs were then closed with absorbable sutures and the skin was sutured with silk or nylon (Pritchett and Corning, 2004).

#### **\* Hormonal Treatment:**

The castrated male rats and the adult female rats were subcutaneously injected with 500  $\mu$ g testosterone propionate (Sustanon, Organon / Sedico®) three times weekly (every other day) (Tobin and Payne, 1991).

#### **\* Specimen Collection:**

Castrated males, castrated males followed by testosterone propionate injection, testosterone propionate injected females and their age matched control groups were sacrificed at 30 and 60 days from the start of the experiment.

The lumbosacral region of the spinal cord was carefully dissected and the level of the first lumbar spinal segment was determined by the level of the tenth thoracic vertebra. The whole lumbosacral region was dissected from the roots of the spinal nerves, removed and divided into several segments (L1, L5 and S1 segments) according to attachments of spinal nerves, immediately immersed in 10% neutral formalin (Walker and Homberger, 1997) and kept in the fixative for at least three to four days before any further processing.

**\* Histological Techniques:**

1. Haematoxylin and Eosin stain: for routine histological examination.
2. Immunohistochemical stain with polyclonal antiandrogen receptor primary antibody: for androgen receptors in neurons (Thermo Fisher Scientific).

**\* Morphometry :**

The data were obtained using Leica Qwin 500 image analyzer

computer system (England) at the Department of Histology, Cairo University. Using the interactive measure menu, the number of motoneurons in the anterior horns of the spinal cord in immunohistochemical cross sections were counted in 5 fields (X 100) in each specimen and the mean value was obtained for each group. The data obtained were subjected to statistical analysis using Student's t-test of significance (Randall, 1958).

## **Results**

### **A. Control Animals:**

#### **\* Male rats:**

In one month old control albino rats, Immunohistochemical stained sections showed positive reactivity for androgen receptor in the nucleus and cytoplasm of motoneurons and neuroglia cells in the anterior horn of the spinal cord (Fig. 1).

In two month old control albino rat, the immunohistochemical stained sections showed strong immunohistochemical reactivity of the cytoplasm of the motoneurons in the anterior horn of the spinal cord (Figs. 2).

**Female rats :**

The haematoxylin and eosin sections of the spinal cord of one month old control female albino rat, showed few small size motoneurons in the anterior horn of the spinal cord. The motoneurons had vesicular rounded nuclei with small processes (Fig. 3).

In haematoxylin and eosin stained sections of two months old albino rat, the anterior horn of spinal cord appeared to be formed of small darkly stained nuclei of neuroglia cells and groups of small size motoneurons. Most of motoneurons are depleted of Nissl granules and had apoptotic-like nuclei (Fig. 4).

**B. Experimental Animals:**

**\* Castrated adult male albino rats:**

Immunohistochemical stained sections of the anterior horn of the spinal cord one month after castration showed strong immunohistochemical reaction in motoneurons and neuroglia cells (Fig. 5).

Two months after castration, immunohistochemical stained sec-

tions showed positive reaction in most of the cells compared to the previous group. However, some cells still had intense reaction (Fig. 6).

**\* Castrated and testosterone injected male albino rats:**

Two months after castration, the motoneurons in the spinal cord of male albino rats injected with testosterone for one month showed very strong positive immunohistochemical reaction in their cytoplasm (Fig. 7).

Immunohistochemical stained sections of the spinal cord of the rats injected with testosterone for two months showed strong positive reaction in the cytoplasm and nuclei (Fig. 8).

**\* Adult female albino rats injected with Testosterone:**

One month after testosterone injection, the haematoxylin and eosin sections of showed few number of small neurons of the anterior horn of the spinal cord. Some nerve cells appear vaculated and had apoptotic nucleus and displaced Nissl granules to the margin (Fig. 9).



Immunohistochemical stained sections showed weak to moderate positive immunohistochemical reaction in the cytoplasm of motoneurons (Fig. 10).

Two months after testosterone injection, Immunohistochemical stained sections of the spinal cord showed strong positive immunohistochemical reaction in the anterior horn of the spinal cord (Fig. 11).

**C. Statistical Analysis:**

**\* Changes in the number of the SNB motoneurons in adult rats:**

Comparing the number of motoneurons of the experimental rats to that of the control rats revealed that the castrated male rats had a highly significant decreased number of motoneurons than that of the control of the same age at all ages. At age of two months, the castrated rats had nearly half the number of motoneurons of the control rats.

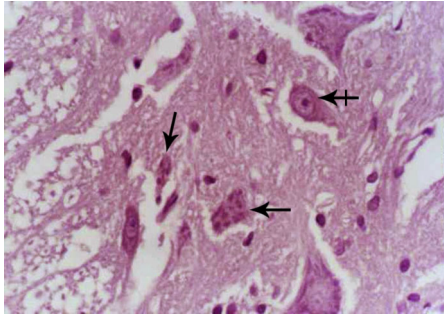
The castrated and testosterone injected rats had a highly significant decreased number of moto-

neurons than that of the control of the same age at all ages. At age of two months, the rats had nearly half the number of motoneurons of the control rats.

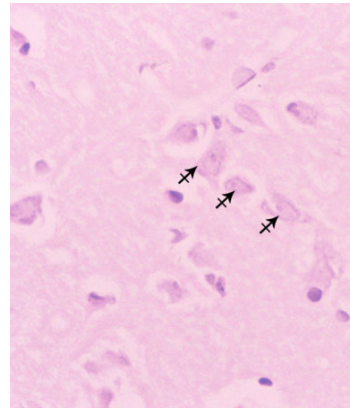
The testosterone injected female rats had a highly significant increased number of motoneurons than that of the control of the same age at all ages till it reached the highest value at age of two months.

The comparison between the control adult male and the control adult female revealed that the control adult female had a highly significant decreased number of motoneurons than that of the control adult male at all ages.

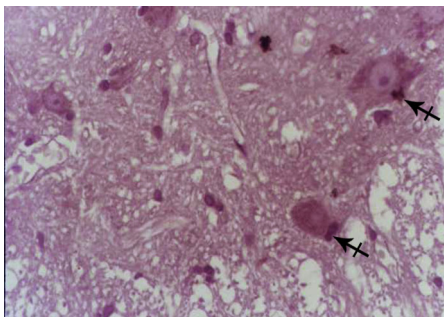
The number of motoneurons in the testosterone injected female rats showed a highly significant increase in the number of motoneurons compared with the castrated and testosterone injected males. The number of motoneurons in females increased than that of the males at 2 months old (Fig. 12).



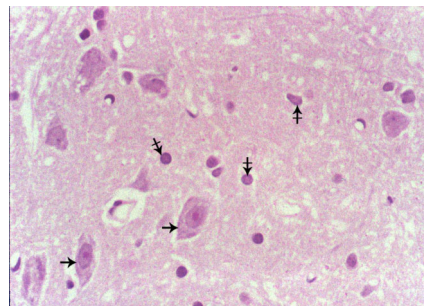
**Fig. 1.** A photomicrograph of a section of the L5 spinal cord segment of a control male albino rat aged 1 month stained for androgen receptors using polyclonal antiandrogen receptor antibody showing positive androgen receptor immunohistochemical reactivity in the cytoplasm (arrows) and nucleus (crossed arrows) of neurons in SNB. (Immunohistochemical stain, counterstained with Hx. & Eosin, X 400).



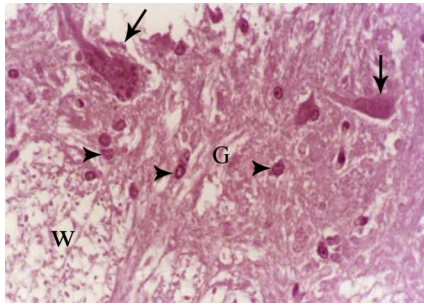
**Fig. 3.** A photomicrograph of a section of the L5 spinal cord segment of control female albino rat aged 1 month showing few small size neurons with vesicular rounded nuclei in the SNB nucleus in the anterior horn of the spinal cord (crossed arrows). (Hx.& Eosin, X 400)



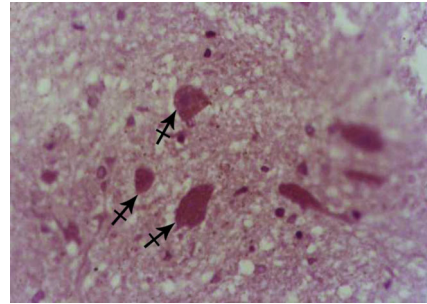
**Fig. 2.** A photomicrograph of a section of the L5 spinal cord segment of a control male albino rat aged 2 months stained for androgen receptors using polyclonal antiandrogen receptor antibody showing strong staining of the cytoplasm of large neurons in the anterior horn of the spinal cord (crossed arrows). (Immunohistochemical stain, counterstained with Hx. & Eosin, X 400)



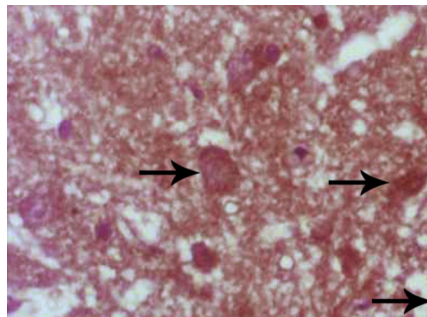
**Fig. 4.** A photomicrograph of a section of the L5 spinal cord segment of control female albino rat aged 2 months showing that most of the motoneurons are small in size (arrows) and some show darkly stained apoptotic-like nuclei (crossed arrows). (Hx.& Eosin, X 400)



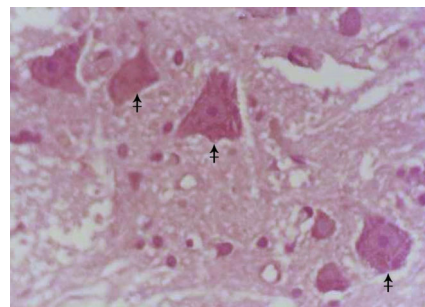
**Fig. 5.** A photomicrograph of a section of L5 spinal cord segment of a male albino rat after one month of castration stained for androgen receptors using polyclonal antiandrogen receptor antibody showing the white matter (W), the gray matter (G), and strong reaction of large neurons (arrows) and neuroglia cells (arrowheads) in the anterior horn of the spinal cord. (Immunohistochemical stain, counterstained with Hx. & Eosin, X 400)



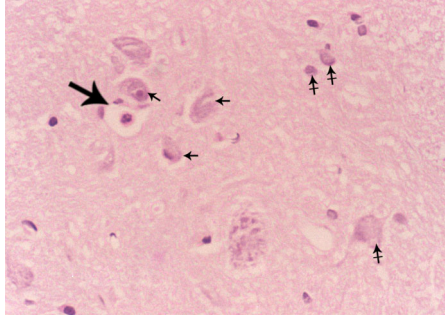
**Fig. 7 :** A photomicrograph of a section of L5 spinal cord segment of a male albino rat injected with testosterone for 1 month after 2 months of castration stained for androgen receptors using polyclonal antiandrogen receptor antibody showing very strong immunohistochemical reaction in the cytoplasm of the nerve cells (crossed arrows). (Immunohistochemical stain, counterstained with Hx. & Eosin, X 400).



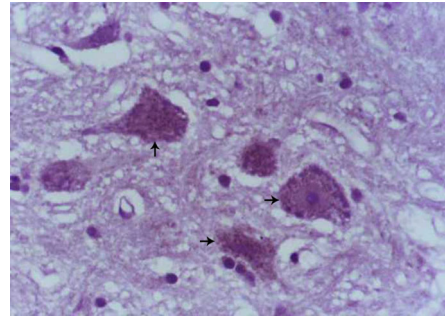
**Fig. 6 :** A photomicrograph of a section of the L5 spinal cord segment of a male albino rat after 2 months of castration stained for androgen receptors using polyclonal antiandrogen receptor antibody showing a positive reaction in most of cells (arrows). (Immunohistochemical stain, counterstained with Hx. & Eosin, X 400).



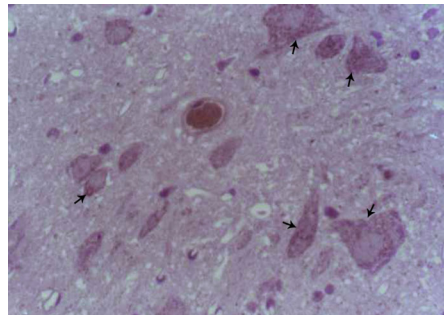
**Fig. 8 :** A photomicrograph of a section of the L5 spinal cord segment of a male albino rat injected with testosterone for 2 months 2 months after castration stained for androgen receptors using polyclonal antiandrogen receptor antibody showing groups of large size neurons in the anterior horn of the spinal cord with positive immunohistochemical reaction in the cytoplasm and nuclei of motoneurons (crossed arrows). (Immunohistochemical stain, counterstained with Hx. & Eosin, X 400).



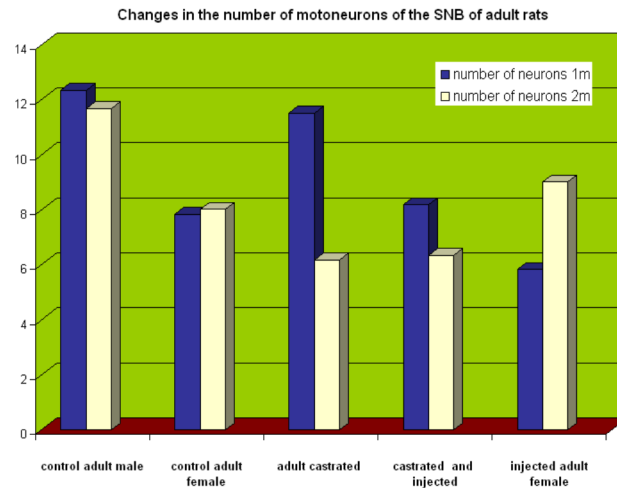
**Fig. 9** : A photomicrograph of a section of the L5 spinal cord segment of 1 month old female albino injected with testosterone showing few scattered motoneurons. Most of the nerve cells appear small (crossed arrows) and show apoptotic like figures (arrows). A nerve cell appear vacuolated with apoptotic nucleus and displaced Nissl granules to the margin (large arrow). (Hx.& Eosin, X 400)



**Fig. 10** : A photomicrograph a section of the L5 spinal cord segment of 1 month old female albino injected with testosterone stained for androgen receptors using polyclonal antiandrogen receptor antibody showing a weak to moderate positive immunohistochemical reaction in the cytoplasm of motoneurons (arrows). (Immunohistochemical stain, counterstained with Hx.&Eosin, X 400)



**Fig. 11:** A photomicrograph stained section of the L5 spinal cord segment of 2 months female albino rat injected with testosterone stained for androgen receptors using polyclonal antiandrogen receptor antibody showing strong positive immunoreactivity of motoneurons (arrows). (Immunohistochemical stain, counterstained with Hx. & Eosin, X 400)



**Fig. 12.** Changes in the number of the SNB motoneurons in the spinal cord of adult control and experimental albino rats at different ages.

### Discussion

In the present investigation the number of SNB motoneurons was significantly reduced in rats one month after castration. Two months after castration, the rats had nearly half the number of SNB motoneurons in comparison to the control rats. Zuloaga et al. (2007) confirmed decrease in number of SNB motoneurons as short as 4 weeks after castration. Others have found effects at 6-7 weeks after castration (Park et al., 2002). These findings suggest that the morphological endpoints of SNB are maintained by adult gonadal androgens. Many SNB moto-

neurons may have shrunken so severely after several months of castration making it difficult to identify SNB motoneurons. This would explain why fewer SNB motoneurons were counted in castrated males than in gonadally intact rats (Jordan et al., 2002).

Testosterone injection after castration increased significantly the size of SNB motoneurons without significant increase in the number of motoneurons. The size and number of motoneurons was increased by testosterone injection in adult females albino rats. These findings were explained by (Breed-

love, 1994) that androgens do not stimulate neurogenesis but prevent cell death in the SNB motoneurons and promote the migration of motoneurons from the DLN to the SNB, probably along radially arranged glial cells. Similar reports have been reported by Watson et al., (2001) that a large majority of SNB motoneurons express androgen receptors in which SNB soma size decreases following adult castration. Adult SNB motoneurons size also depends on adult level of androgen that act directly via androgen receptors. The difference in response to testosterone injection between the castrated males and the adult females can be explained by positive and negative feedback on hypothalamic pituitary axis (Foecking et al., 2005).

The SNB motoneurons of castrated adult male showed strong immunohistochemical reaction in the cytoplasm one month after castration but the reactivity became weak two months after castration. While the perineal muscles of the same age group showed positive immunoreactivity.

These observations were almost similar to those of Freeman et al. (2004) who found cytoplasmic staining in the SNB motoneurons of untreated castrated rats suggesting that androgen receptors (AR) accumulated in the cytoplasm and then translocated to the nucleus on binding to androgen receptors in these motoneurons. He found also that no motoneurons in the SNB displayed nuclear immunostaining in long-term castrated males that renders AR incompetent. Matsumoto et al. (2003) and Sengelaub and Forger, (2008) confirmed that after castration, concentration of receptor sites was more than doubled. The increase in the sites began within the first 24 hours after castration and reached a plateau level within 7 days.

### References

**Arnold A. P. (2002)** : Concepts of genetic and hormonal induction of vertebrate sexual differentiation in the twentieth century, with special reference to the brain. *Horm. Brain and Behavior.*, 4:105-135.

**Breedlove S. M. (1994)** : Sexu-

al differentiation of the human nervous system. *Ann. Rev. Neurosci.*, 45: 389-418.

**De Vries G. J. (2004)** : Mini-review: sex differences in adult and developing brains. *Endocrinol.* 145 (3): 1063-1068.

**Foecking E. M.; Szabo M., Schwartz N. B. and Levine J. E. (2005)** : Neuroendocrine consequences of prenatal androgen exposure in the female rat: absence of luteinizing hormone surges, suppression of progesterone receptor gene expression, and acceleration of the gonadotropin-releasing hormone pulse generator. *Biol. Rep.*, 72: 1475-1483.

**Freeman L. M., Padgett B. A., Prins G. S. and Breedlove S. M. (2004)** : Distribution of androgen receptor immunoreactivity in the spinal cord of wild-type, androgen-insensitive and gonadectomized male rats. *J. Neurobiol.*, 27 (1): 51-59.

**Jordan C. L., Breedlove S. M., Anderson J. L. and Pouliot W. A. (2002)** : Evidence that androgen acts through NMDA receptors to

affect motoneurons in the rat spinal nucleus of the bulbocavernosus. *J. Neurosci.*, 22 (21): 9567 - 72.

**Jost A., Vigier B., Prepin J. and Perchellet J. P. (1973)** : Studies on sex differentiation in mammals. *Rec. Prog. Horm. Res.*, 29 : 1-41.

**Matsumoto A., Arai Y. and Prins G. (2003)** : Androgenic Regulation of Androgen Receptor Immunoreactivity in Motoneurons of the Spinal Nucleus of the Bulbocavernosus of Male Rats. *J. Neuroend.*, 8: 553-559.

**Nagy J. I. and Senba E. (1985)** : Neural relations of cremaster motoneurons, spinal cord system and the genitofemoral nerve in the rat. *Brain Res. Bull.*, 15: 609-627.

**Park J. J., Zup S. L., Verhovshek T. and Forger N. G. (2002)** : castration reduces motoneuron size but not dendritic length in the spinal nucleus of bulbocavernosus of wild-type and BCL2-overexpressing mice. *J. Neurobiol.*, 53 (3): 403-12.



- Pritchett K. P. and Corning B. F. (2004)** : Biology and medicine of rats. In: Laboratory Animal Medicine and Management. Reuter, J. D. and Suckow, M. A. (Eds). International veterinary information services, Ithaca, New York, USA.
- Randall J. E. (1958)** : Elements of Biophysics. The Year Book Publisher, Chicago, P. 114-123.
- Sengelaub D. R. and Forger A. P. (2008)** : The spinal nucleus of the bulbocavernosus: firsts in androgen-dependent neural sex differences. *Horm. Behav.*, 53(5): 596-612.
- Thermo Fisher Scientific:** Anatomical Pathology. <http://www.thermo.com/labvision>
- Tobin A. M. and Payne A. P. (1991)** : Perinatal androgen administration and the maintenance of sexually dimorphic and nondimorphic lumbosacral motoneuron groups in female Albino Swiss rats. *J. Anat.*, 177: 47-53.
- Walker W. F. and Homberger D. G. (1997)** : Nervous system. In anatomy and Dissection of the rat. 3rd ed., New York.
- Watson N. V., Freeman L. M. and Breedlove S. M. (2001)** : Neuronal size in the spinal nucleus of bulbocavernosus: direct modulation by androgen in rats with mosaic androgen insensitivity. *J. Neurosci.*, 21 (3): 1062-6.
- Wilson C. A. and Davies D. C. (2007)** : The control of sexual differentiation of the reproductive system and brain. *Rep.*, 133 : 331-359.
- Zuloaga D. G., Morris J. A., Monks D. A. and Breedlove S. M. (2007)** : Androgen-sensitivity of somata and dendrites of spinal nucleus of the bulbocavernosus (SNB) motoneurons in male C57BL6J mice. *Hom. Behav.*, 51 (2): 207-212.



REPRINT

# **BENHA MEDICAL JOURNAL**

**SEXUAL DIMORPHISM IN  
THE LUMBO-SACRAL REGION  
OF THE ALBINO RAT SPINAL CORD**

**Adel A. Bondok MD, Omar M. Gabr MD,  
Azza R. El-hadedy MD, Dalia M. Saleh MD  
and Hassan M. Rezk MD**

**Published by  
Benha Faculty of Medicine**

*Volume 26 Number 3  
Sept. 2009*

## COMPARATIVE STUDY OF DNA CYTOMETRY AND OTHER PROGNOSTIC FACTORS OF DIFFERENTIATED THYROID CARCINOMA

**Hanem A. Sakr MD, Niveen A. Abo-Touk MD,  
Salah A. Keshta MD and Yaser Ali MD\***

*Departments of Clinical Oncology and Nuclear Medicine  
and Surgical Endocrinology,\* Faculty of Medicine, Mansoura University, Egypt.*

### Abstract

**Objective :** *To analyse the initial manifestations, pathological findings, therapy, outcome and prognostic factors in patients with differentiated thyroid carcinoma and also to evaluate DNA flow cytometry as a prognostic factor in differentiated thyroid carcinoma.*

**Patients and Methods :** *Analysis of clinical and pathological records was conducted on 420 patients (96 male and 324 female) treated form well differentiated thyroid carcinoma referred to Clinical Oncology and Nuclear Medicine Department and Surgical Endocrinology Unit, Mansoura University Hospital in the period from January 1990 to December 2000. Nuclear DNA content was analyzed in 80 patients with DNA flow cytometry post operatively.*

**Results:** *The patients were 96 males (22.8%) and 324 females (77.2%). Papillary carcinoma constituted 68.6% of patients. The majority of cases were in the fifth decade. The duration of symptoms was less than 6 months ( 79%) of cases, 21% of cases presented with neck node metastases, while distant metastases in 4%. The five years disease free survival rate was 100% to all patients, while the ten years survivals were 91, 88 and 88 percent in papillary, follicular and mixed type, respectively. The univariate analysis identified age at time of diagnosis, glandular extracapsular extension, tumor size and distant metastases as significant prognostic factors with major effect on survival. Other factors such as gender, multifocality or regional lymph node metastases had no effect on survival. DNA content was diploid in 57% of follicular carcinoma and 37%*

*of papillary carcinoma. Aneuploid pattern was found in 43% and 63% of follicular and papillary carcinoma respectively. DNA diploid pattern was associated with less mortality due to cancer.*

**Conclusions:** *We concluded that there is a high prevalence of papillary carcinoma in our country. Age at time of diagnosis, glandular extra thyroid extension, tumor size and distant metastases were significant prognostic factors by univariate analysis with major effect on survival. Other factors such as gender, multifocality or regional lymph node metastases had no effect on survival. In studying response to treatment and disease free survival for comparison with the result of DNA flow cytometry, it was found that complete response to treatment and disease free period were higher in cases that showed diploid pattern whether the pathological type was follicular or papillary.*

### **Introduction**

Differentiated thyroid carcinoma is a relatively indolent disease. Despite the usually favorable prognosis, differentiated thyroid carcinoma is fatal in some patients. In the past, treatment strategies were often based upon incomplete knowledge of inaccurate assumptions regarding the significance of the presenting characteristics of the tumor and patient. More recently, several large retrospective reviews have identified those that have prognostic significance and those that do not. Using this knowledge, patients can be grouped into low, intermediate and high risk groups (Loree TR, 1995).

Prognostic factors and risk group analysis have facilitated the development of more rational treatment algorithms and makes a selective approach to differentiated thyroid carcinoma possible (Sebastian et al, 2000).

Such an approach can spare many patients morbidity and expense of unnecessarily aggressive treatment without compromising outcome. In a wide range of human cancers, tumor cell nuclear DNA content has been considered to represent one of the best prognostic indices of the malignant potential in thyroid carcinoma and the presence of an abnormal DNA. Stemline has been regarded as the

single most reliable marker of neoplasia and has predictive power significantly greater than that of all other prognostic factors combined (Backdahl, Hamberger, 2005).

### **The Aim of the Work**

The purpose of this study was to review our experience with differentiated carcinoma of thyroid and studying different prognostic factors and its effect on survival in addition to evaluation of DNA ploidy as a significant prognostic variable.

### **Patients and Methods**

From January 1990 to December 1998, 420 patients diagnosed pathologically as differentiated thyroid carcinoma, referred to Clinical Oncology and Nuclear Medicine Department and Surgical Endocrinology Unit, Mansoura University Hospital were enrolled in this study. From these patients 288 (68.6%) had papillary thyroid carcinoma, 92 patients (21.9%) had follicular carcinoma and 40 patients (9.5%) had mixed papillary and follicular type.

Different parameters were stud-

ied including age, gender, tumor size, extracapsular extension, focality of primary tumor, presence or absence of distant metastases, lymph nodes involvement, histological type, treatment and five and ten years survival to all cases.

The primary treatment comprised of total thyroidectomy, TSH suppressive therapy with L-thyroxin and post operative radioiodine therapy in all patients. The radicality of previous thyroid surgery was assessed by I131 whole post-operative body scintigraphy using 5 mCi of I131 performed after 4 weeks of L-thyroxin withdrawal and operation.

Nuclear DNA content was analyzed in 80 patients by DNA flow cytometry post-operatively. DNA histograms were scored as either diploid or aneuploid by single cell suspension preparation and the result was correlated with the survival and other prognostic factors.

The fresh tissue was stored at -80°C in citrate buffer. A fresh tissue cell suspension was prepared according to the method of

Vindelov and colleagues and stained with propidium iodine (Vindelov et al 1983). Chicken red blood cells (CRBCs) and trout red blood cells (TRBCs) were added as internal reference standards. The cells for fresh tissue flow cytometry (fFCM) were analyzed by use of a leitz MPV Flow (Leitz, Wetzlar, Federal Republic of Germany) and a Monroe OC8888® microcomputer. Histograms included at least 20,000 cells, resulting in a coefficient of variation (CV) of less than 5.1% (mean = 2.9%).

Specifically, regarding follicular neoplasms, the entire capsule or at least six sections of the capsule were examined for evidence of capsular or vascular invasion. Also, the tumors were examined for cytologic atypia and subjectively graded on a scale of 0-3 (0=no atypia ; 3= marked atypia).

Kaplan-meier survival analysis was used to calculate both cancer related mortality and disease free survival in the patients followed up. Cox's proportional hazard regression analysis for disease free survival was also used in this study.

## Results

This study evaluated the different prognostic factors in 420 patients with differentiated thyroid carcinoma attended Clinical Oncology and Nuclear Medicine Department and Surgical Endocrinology unit, Mansoura University from January 1990 to December 1998.

They were 96 (22.8%) males and 324 (77.2%) females (Table 1). Of this group 288 (68.6%) patients presented with papillary thyroid carcinoma 92 (21.9%) patients had follicular carcinoma of thyroid and 40 (9.5%) had mixed papillary and follicular carcinoma.

Table 1 shows the high incidence (58.0%) among the age of 40:49 years. Neck mass was the commonest symptom (80%). Duration of symptoms was less than 6 months in 79% of cases. Extra thyroid invasion was found only in 8% of cases and neck node metastases was present in 88 patients (21%). Distant metastases was present in 4% of cases while the number of lesion of cases was multiple in 21% of cases. (Table 1).

During whole period of follow up 16 (4%) patients suffered from distant metastases. 8 in lungs, 7 in bones, 1 in liver .

Regarding the results of DNA flow cytometric analysis and its relation to histopathological analysis., Twenty four cases out of 42 with follicular carcinoma showed diploid pattern (57%) and 18 cases were of aneuploid pattern (43%), of the 38 cases with papillary carcinoma, 24 were of aneuploid pattern (60.3%) and 14 were diploid (39.7%)

Important prognostic factors identified on multivariate analysis were age older than 45 years ( $P < 0.001$ ), extrathyroid extension, tumor size exceeding 5 cm, and the presence or absence of distant metastases ( $P < 0.001$ ) (Table 2).

The five to ten years survival for the entire series of patients with papillary carcinoma was

100% and 91% and of follicular carcinoma it was 100% and 88% respectively while for patients with mixed carcinoma it was 100% and 88% respectively (Table 3).

In studying response to treatment and disease free survival in comparison with DNA flow cytometry results, it was found that complete response to treatment and disease free period were higher in cases showed diploid pattern whether the pathological; type was follicular or papillary, it was 90% and 96% respectively in comparison to 86% and 90% respectively in cases showed aneuploid pattern, (Table 4).

Statistical analysis found no correlation between the histologic grade of atypia (0-3) and the DNA index . The presence or absence of aneuploidy could not be predicted on the basis of light microscopic criteria.

**Table (1):** Clinical Investigational Characteristics of 420 Cases with differentiated Thyroid Carcinoma.

Characteristics	Number	Percent
<b>Age (years)</b>		
40-49	244	58.0
50-59	130	31.0
60-69	20	4.8
70-79	16	3.8
80-89	10	2.4
<b>Gender</b>		
Male	96	22.8
Female	324	77.2
<b>Symptoms</b>		
Neck tumour	336	80.0
Hoarseness	80	19.0
Neck Pain	10	2.4
Dyspnea	4	0.9
Dysphagia	4	0.9
<b>Duration of symptoms in months</b>		
≤6	332	79
>6	88	21
<b>Maximum diameter of the tumour</b>		
≤5 cm	316	75
>5cm	104	25
<b>Number of lesions</b>		
Solitary	332	79
Multiple	88	21
<b>Extrathyroid invasion</b>		
Absent	388	92
Present	32	8
<b>Nodal metastases</b>		
Absent	332	79
Present	88	21
<b>Local recurrence</b>		
In Thyroid bed	12	2.8
In Neck Lymph Nodes	6	1.4
In Both	12	2.8
<b>Distant metastases</b>		
Absent	404	96
Present	16	4

P = 0.001

**Table (2):** Analysis of Prognostic Factors in Patients with Differentiated Thyroid Carcinoma

Factor	No	%	P-value
Age <45 Years	244	58	<0.001
Male	96	22.9	N.S
Size > 5cm	104	24.8	<0.001
Solitary	332	79	N.S
Extra Capsular Extension	32	7.6	<0.001
Nodal Metastases	68	16.2	N.S
Distant Metastases	16	4	<0.001

N.S: Not Significant

**Table (3) :** Five and ten Years Survival for Differentiated Thyroid Carcinoma.

Type	No. of cases	5 years survival %	10 years survival %	P-value
Papillary	288	100%	91	<0.001
Follicular	92	100%	88	<0.001
Mixed	40	100%	88	<0.001

**Table (4):** DNA Pattern and its Relation to 5 years survival in 80 patients.

Histopathology	Number	10 years Disease Free Survival %	P-value
<b>I-Follicular:-</b>			
a-Diploid	24	90%	N.S.
b-Aneuploid	18	86%	N.S.
<b>II-Papillary:</b>			
a-Diploid	14	96%	N.S.
b-Aneuploid	24	90%	N.S.



### **Discussion**

Well differentiated thyroid carcinoma are usually slow growing neoplasm with an indolent clinical course. Assessment of the results to different treatment modalities for well differentiated thyroid carcinoma requires a long-term follow-up in a large number of patients (Tseng et al , 1996) . The concept of prognostic factors in thyroid cancer was first described more than 40 years ago (Wollier et al, 2005).

Our understanding of the natural history of differentiated thyroid carcinomas has improved with the definition of prognostic factors. These prognostic factors have helped us to identify patients in various risk groups (Hughes et al, 2000). As regard survival and prognostic factors, Wein and Weber 2005 (Wein and Weber ,2005) reported that in papillary adenocarcinoma of the thyroid, the survival is not decreased when compared with age matched population until 12 years after the diagnosis. Even with distant metastases patients often survive many years without therapy. The raw 10

years survival rate is 95% of patients <40 years of age and 75% of patients >40 years of age. Woodrum and Gauger 2005, reported that factors that adversely affect prognosis , which both increase the recurrence rate and decrease the survival rate were, age below 40 years, size of nodule >5cm, tumor extend through thyroid capsule, presence of symptoms such as hoarseness or dysphagia, distant metastases and residual tumor fails to take up I 131. As regard follicular Carcinoma without vascular invasion, it has essentially the same survival rate as papillary Carcinoma for age matched population (Woodrum and Gauger, 2005).

In our study, univariate analysis identified age, glandular extracapsular extension, tumor size and distant metastases as significant prognostic factors with major effect on survival. The same prognostic factors were identified by a study done by Tsuchiy et al. 2006. He found also that lymph nodes metastases and operative procedure have a significant prognostic factors (Tsuchiy et al, 2006).

Ten years survival in our study was 91% in cases of papillary carcinoma and 88% in cases with follicular carcinoma. It was 92% and 88% respectively, a study done by (Steinmuller et al., 2001).

Multivariate analysis was conducted on survival data of 374 patients who underwent curative resection for differentiated thyroid cancers. The important prognostic factors identified were age older than 45 years, extrathyroid extension, tumor size exceeding 5 cm and presence or absence of distant metastases. These results were in agreement with many studies (Rao et al ,2007 - Tsuchiy et al 2006 - Tubian et al,1990).

Based on data derived from our study in DNA pattern done for 80 patients (42 of follicular and 38 of papillary subtypes), 5 years survival rates was noticed to be higher in the groups which showed diploid DNA patterns (90% vs 86%) in cases with aneuploid pattern in follicular carcinoma and 96% vs 90% in papillary carcinoma and this reflected that the finding of non-diploid DNA appears to be associated with higher cancer mor-

tality, these results were in coordinate with results reported by many authors (El-Naggar et al, 1998 - Ryan et al, 2005)

DNA index determinations have been used successfully to separate aggressive lesions from more indolent tumors of breast and prostate as well as thyroid tissue (Auer et al, 1980 - Zetterberg and Esposti, 1980). Cohn and associates could separate survivors of papillary thyroid carcinoma from nonsurvivors based on DNA content(Cohn et al, 1984). Joensuu and co-workers (Joensuu et al, 1986), found DNA aneuploidy to be an adverse prognostic factor in papillary, follicular, and medullary thyroid carcinomas and closely associated with the age of the patient at diagnosis. In a separate report they found DNA aneuploidy not to be associated with an adverse prognosis in follicular adenomas of the thyroid if the tumor has been surgically removed (Joensuu et al, 1986).

Lang and associates studied a large series of thyroid lesions and classified 9.8% of the tumors as atypical adenomas, with increased

mitotic rates similar to those seen in encapsulated follicular carcinoma. There was no statistical significance between the atypical adenomas and encapsulated carcinomas, however, the follow-up period was relatively short. Vascular invasion and capsular penetration are the most widely accepted parameters for differentiating these follicular thyroid tumors. With the development of new cytometric methods, DNA index determinations on paraffin-embedded tissue may be additional parameter to help separate these borderline follicular neoplasms (Lang et al, 1980).

### **Summary and Conclusion**

Analysis of clinical and pathological records was conducted on 420 patients (96 male and 324 female) treated form well differentiated thyroid carcinoma. We concluded that there is a high prevalence of papillary carcinoma in our country. Age at time of diagnosis, glandular extra thyroid extension, tumor size and distant metastases were significant prognostic factors by univariate analysis with major effect on survival. Other factors such as gender,

multifocality or regional lymph node metastases had no effect on survival. In studying response to treatment and disease free survival for comparison with the result of DNA flow cytometry, it was found that complete response to treatment and disease free period were higher in cases that showed diploid pattern whether the pathological type was follicular or papillary.

### **References**

**Loree T. R. (1995)** : Therapeutic implications of the prognostic factors in differentiated carcinoma of the thyroid gland. *Semin, Surg. Oncol*, May, 11 : 3, 246-55.

**Sebastian S. O., Gonzalez J. M., Perez J. S., et al., (2000)** : Papillary thyroid carcinoma, Prognostic index for survival including the histological variety. *Arch. Surg*, Mar, 135:3, 272-7.

**Backdahl M. and Hamberger B. (2005)** : Ploidy in thyroid tumours In van hereden JA (ed). *Common problems in Endocrine Surgery*. Chicago, year Book medical pp 49-53.

- Vindelov L. L., Christensen I. J. and Nissen N. I. (1983)** : A detergent -trypsin method for the preparation of nuclei for flow cytometric DNA analysis. *Cytometry*.3:323-327.
- Tseng L. M., Lee C. H., Wang H. C., et al., (1996)** : The surgical treatment and prognostic factors of well differentiated thyroid cancers in Chinese patients a 20-year experience. *Chung hua, Hsueh Tsa* Aug. 58-2121-31.
- Wollier L. B., Beahrs O. H., Black B. M., et al., (2005)** : Thyroid carcinoma, follow up data on 1181 cases. In young S, In man Dr (eds): thyroid Neoplasia, New-York: Academic press, pp 51-79.
- Hughes C. J., Shaha A. R., Shah J. P., et al., (2000)** : Impact of lymph node metastases in differentiated carcinoma of the thyroid: a matched-Pair analysis. *Head Neck*, Mar, 18:2, 127-32.
- Wein R. O. and Weber R. S. (2005)** : Contemporary management of differentiated thyroid carcinoma. *Otolaryngeal Clin N Am*. 38:161.
- Woodrum D. T. and Gauger P. G. (2005)** : Role of I 131in treatment of well differentiated thyroid cancer. *J surg Oncology*. 89:114.
- Rao R. S., Parikh H. K., Deshmane V. H., et al., (2007)** : Prognostic factors in follicular carcinoma of the thyroid: A study of 198 cases. *Head Neck*, Mar. 18:2,118-24.
- Steinmuller T., Klupp J., Rayes N., et al., (2000)** : Prognostic factors in patients with differentiated thyroid carcinoma *Eur. J. Surg.* Jan. 166:1; 29-33.
- Tsuchiy A., Suzuki S., Kanno M., et al., (2006)** : Prognostic factors associated with differentiated thyroid cancer *Surg. Today*, 25:9, 778-82.
- Tubian M., Mchlum benger M., Raugier P., et al., (1990)** : Long term results and prognostic factors in patients with differentiated thyroid carcinoma. *Cancer*, 55, 794-804.
- El-Naggar A. K., Batsakis J. G., Luna M. A., et al., (1998)** : Hurthle cell tumours on the thy-

roid a flow-cytometric DNA analysis Arch. Otolarygeal Head neck Surg. 114:520-521.

**Ryan J. J., Hay I. D., Grant C. S., et al., (2005)** : Flow cytometric DNA measurements in benign and malignant hurthle cell tumors of the thyroid. World J. Surg. 12:482-487.

**Auer G., Caspersson T. and Wallgren A. (1980)** : DNA content and survival in mammary carcinoma. Analytical Quantitative Cytology. 2:161-165.

**Zetterberg A. and Esposti P. (1980)** : Prognostic significance of nuclear DNA levels in prostatic carcinoma. Scand J Urol Nephrol. 55:53-58.

**Cohn K. H., Backdahl M., Forsslund G., et al., (1984)** : Bio-

logic consideration and operative strategy in papillary thyroid carcinoma : Arguments against the routine performance of total thyroidectomy. Surgery. 96 : 957-970.

**Joensuu H., Klemi P., Eerola E., et al., (1986)** : Influence of cellular DNA content on survival in differentiated thyroid cancer. Cancer. 58:2462-67.

**Joensuu H., Klemi P., Eerola E., et al., (1986)** : DNA aneuploidy in follicular adenoma of thyroid gland. Am J Pathol. 124:373-376.

**Lang W., Georgii G., Strauch G., et al., (1980)** : The differentiation of atypical adenomas and encapsulated follicular carcinomas in the thyroid gland. Virchows Arch [Pathol Anat]. 385:125-141.

REPRINT

# **BENHA MEDICAL JOURNAL**

**COMPARATIVE STUDY OF  
DNA CYTOMETRY AND OTHER  
PROGNOSTIC FACTORS OF  
DIFFERENTIATED THYROID  
CARCINOMA**

**Hanem A. Sakr MD, Niveen A. Abo-Touk MD,  
Salah A. Keshta MD and Yasser Ali MD**

**Published by  
Benha Faculty of Medicine**

*Volume 26 Number 3  
Sept. 2009*

## UNCERTAIN ROLE OF MENOPAUSE IN CARDIO- VASCULAR DISEASE RISK

**Abdalla M. El-Moslmani MD, Ashraf E. Belal MD  
and Abadalla E. Deiab MD**

*Departments of Community Medicine , Physiology and Gynecology,  
Benha and Zagazig Universities, Egypt*

### **Abstract**

**Background:** Cardiovascular disease(CVD) risk increases after menopause which may be related to metabolic and hormonal changes. Menopause is a risk factor of CVD because estrogen withdrawal affects cardiovascular function and metabolism. **Objective:** Recognizing the role of menopause as a risk factor of cardiovascular disease. **Subject and Methods:** 500 women living in Azazzi village, Sharkia Governorate and aged between 45-55 years were invited to attend the health unit for participation in this cross-sectional study, during the period from February-to-August, 2008. Only 270 women shared in the study after exclusion of the unfit and refusing women. All women were subjected to self-administered questionnaire, measuring blood pressure, weight and height for BMI, serum samples for FSH and E2 hormones and blood samples for lipids, lipoproteins and glucose. The collected data were analyzed by using the mean, standard deviation and multivariate analysis(SPSS). **Results:** The study showed a significant relation between the menopause and systolic blood pressure ( $p<0.001$ ) , total cholesterol ( $p<0.001$ ), LDL-cholesterol ( $p<0.05$ ) and triglycerides( $p<0.001$ ). Also, there was a significant relation with age ( $p<0.001$ ), current smoking ( $p<0.05$ ) and BMI ( $P<0.05$ ). These significant variables in the menopause making it as a risk factor of cardiovascular disease. **Conclusion:** Menopause is a risk factor of cardiovascular disease because it is accompanied with increased lipids, lipoproteins, systolic blood pressure and withdrawal of estrogen hormone which causes changes in function and metabolism of cardiovascular system. **Recommendations:** The menopausal women are educated to control hypertension, diabetes and getting hormone therapy

*under supervision of cardiologist and gynecologist. They are, also, advised to stop smoking, avoid sedentary life and maintain normal body weight.*

### **Introduction**

The world Health Organization (WHO) has defined the menopause as the permanent cessation of menstruation resulting from loss of ovarian follicular activity.( WHO, 1996). Cardiovascular disease risk (CVD) increases after the menopause which may be related to metabolic and hormonal changes. (Zarate A et al, 2007). Menopause is a risk factor of CVD because estrogen withdrawal has a detrimental effect on cardiovascular function and metabolism. The menopause compounds many traditional CVD risk factors, including changes in body fat distribution from a ganooids to an android pattern, reduced glucose tolerance, abnormal plasma lipids, increased blood pressure, increased sympathetic tone, endothelial dysfunction and vascular inflammation. (Rosano GM et al., 2007) Moreover, cardiovascular risks are poorly managed in women, especially during the menopausal transition when susceptibility to cardiovascular events increases. Key risk factors that

need to be controlled in the perimenopausal women are hypertension, dyslipidemia, obesity and other components of the metabolic syndrome (Collins P et al, 2007) Hormone replacement therapy is acknowledged as the gold standard for the alleviation of the distressing vasomotor symptoms of the menopause ( Kalsiwal RR et al, 2006) .

So, this study is objective to recognize the role of menopause as a risk of cardiovascular disease

### **Subject and Methods**

Five hundred women aged between 45-55 years and have lived in Al-Azazi village, Sharkia Governorate, were invited to participate in this study. Only 270 women had shared in this study after exclusion of unfit women. These women attended the health unit of this village for interview. Permission of the health authorities was obtained .The study was carried out in the period between February- to- August, 2008.



All women filled in a standardized self-administered questionnaire which provided information about family and personal history of coronary heart disease (CHD), diabetes and hypertension, consumption of antihypertensive and anticoagulant drugs, sex hormones, smoking habits and menopausal status (the date of last menstrual cycle & manifestations of menopause). All self-administered questionnaires were reviewed during an interview. All women with CHD, suspected diabetes, taking anticoagulants, incomplete gynecological data, uncertain menopause, hysterectomy, Oophorectomy and hormone therapy, were excluded.

Serum samples were taken from 39 pre-menopause and 52 from post-menopausal women for testing follicular stimulating hormone (FSH) and oestradiol (E2) by radio-immunoassay.

Also, blood samples were taken from all the women participating. Total cholesterol (Roeschau P et al, 1974 ) triglycerides (Fossati P and Principle L, 1982) and glucose (Trinder P, 1969) were as-

sayed enzymatically on a Hitachi 737 analyzer.

High density lipoproteins(HDL) cholesterol was measured enzymatically (Fruchart J C et al, 1982).

Low density lipoprotein(LDL) cholesterol as computed with Friedewald formula (Friedewald W T et al, 1972).

Blood pressure and body mass index (BMI) were measured.

As regard to smoking, women who smoked at least one cigarette per day at the time of examination were considered as current smokers , the women who had stopped smoking at this time were considered as former smokers and those who never smoked as non-smokers. Smoking status was coded as 0 for former and non-smokers and one for current smokers.

The collected data were analyzed statistically by using the mean and standard deviation for calculating the student's t test

and SPSS for multivariate statistics.

**Results**

Table (1) : shows the comparison between the self-reports of menopausal status and the hormonal status. Women with FSH>20mUI/ml and E2<50pg were considered as being endocrinologically post menopausal and the women who did not meet these criteria as being premenopausal.

Table (2) : shows the main characteristics of the women according to their menopausal status. Postmenopausal women were significantly older and heavier than premenopausal women. Also, there were more

current smokers in premenopausal than in postmenopausal women.

Table (3) : shows the mean values and standard deviations of the cardiovascular risk factors according to the menopausal status. Postmenopausal women were associated with increase (p<0.05) in total cholesterol, LDL-cholesterol, triglycerides and systolic blood pressure in contrast to premenopausal women.

Table (4) : shows that the total cholesterol, LDL-cholesterol, triglycerides and systolic blood pressure remained significantly increased in postmenopausal women as compared with premenopausal women (p<0.05).

**Table(1):** No. and % distribution of the study according to the hormonal status in a sub-sample of 91 women not using hormones.

Hormonal status	Pre-menopausal (n=39)	Post-menopausal (n=52)
-FSH ≤ 20mUI/ml	34/39	7/52
Or E2 ≥ 50 pg / ml	87.2%	13.4%
-FSH > 20mUI/ml	5/39	42/52
Or E2 < 50 pg / ml	12.8%	86.6%

**Table(2):** Main characteristics of pre-menopausal and post-menopausal women.

	Pre-menopausal (n=170)	Post-menopausal (n=100)	P value
-Age	47.8±2.2	52.2±1.9	<0.001
-BMI	23.2±3.1	23.9±3.0	<0.05
-%current smokers	26.5%	16.9%	<0.05
-Post-menopausal time	-	4.0±3.3	-

**Table(3):** Blood levels of lipids, glucose and blood pressure in the study group.

	Pre-menopausal (n=170)	Post-menopausal (n=100)	P value
-Cholesterol	216.5±36.3	243.6±42.2	<0.001
- HDL-cholesterol	69.6±1.0	70.5±1.4	NS
- LDL-cholesterol	138.5±2.5	149.6±3.6	<0.05
-Triglycerides	64.1±29.5	77.3±30.1	<0.001
-Systolic B.P	129.8±12.1	134.1±14.1	<0.001
-Diastolic B.P	79.5±9.4	81.3±10.4	NS

**Table(4):** Adjusted means\*( standard errors) of lipids and other cardiovascular risk factors in women according to their menopausal status.

	Pre-menopausal	Post-menopausal	P value
<b>-Lipids:</b>			
Cholesterol	221.3±2.7	235±3.8	<0.01
HDL-cholesterol	69.6±1.0	70.5±1.4	NS
LDL-cholesterol	138.5±2.5	149.6±3.6	<0.05
Triglycerides	65.5±2.0	75.0±2.9	<0.01
-Systolic B.P	130.1±0.9	133±1.2	<0.05
-Diastolic B.P	80.1±0.7	80.1±0.9	NS
-Blood glucose	97.9±0.6	99.3±0.8	NS

\*Adjusted age (years), BMI and smoking status by SPSS program.

HDL=high density lipids

LDL=low density lipids

### **Discussion**

In this cross-sectional study the hypothesis was that the menopause is related to cardiovascular disease risk. Actually, the results showed a positive relation between menopause and the cardiovascular disease risks, especially lipids. This result is the same as that of two longitudinal studies (Haman RF et al, 1990) which found that menopause preceded an increase in cholesterol levels. Against this result, other two studies - on Indian (Castelli WP et al, 1986) and black American (Bush TL et al, 1987) women- failed to find a difference in total cholesterol between pre-menopausal and post-menopausal women.

Our study clearly establishes that the increase in cholesterol after menopause could not be explained by concomitant changes in body mass index or smoking habits. It also suggests, in accord with other reports (Levy RI et al, 1984), that changes in cholesterol and other lipids may occur after the first two years of menopause. In this study, there is no increase in the level of HDL-cholesterol and this coincides with

that published in other studies (Kane JP et al, 1990) and (Muldoon MF, 1990). LDL-cholesterol and triglycerides were significantly increased in post-menopausal women as showed in the tables of this study. Positive association between triglycerides and menopause is consistent with previous results of both cross-sectional (Bonithon-Kopp C et al, 1990), and longitudinal studies (Jensen J, 1991).

Blood glucose level, in our study, showed insignificant relationship to menopausal status and this was assisted by a previous study (Proudler AJ et al, 1992). Systolic blood pressure- in our study- showed a significant increase in the post-menopausal women, and this result agrees with another study (Staessen J et al, 1989) while the diastolic blood pressure did not show any difference between the pre-menopausal and post-menopausal women in both of the previous studies. The pre-menopausal and post-menopausal women who were taking hormone therapy, were excluded because of the known effects of exogenous estrogen and progester-

rone on lipid metabolism (Stampfer MJ et al,1991).

Misclassification of the menopausal status may have occurred in some cases resulting in an under-estimation of the differences between the pre-menopausal and the post-menopausal women. However, the use of more restrictive definition excluding the pre-menopausal who had not menstruated in the last two months and post-menopausal women with a post-menopausal time less than 12 months did not substantially modify the differences in lipids, blood pressure and blood glucose between pre-menopausal and post-menopausal women.

Although we have no convincing evidence that selection biases explain the observed differences in lipids according to the menopausal status, their significance remains questionable. Firstly, because of the nature of this cross-sectional study, we can not be certain that change in menopausal status precedes and causes the changes in lipids. Secondly, even if we assume that to be true, our study does not enable us to deter-

mine the influence of the observed menopausal effects on the development of CHD. The absence of menopausal effects on HDL-cholesterol, which is a strong negative predictor of CHD( Muldoon MF et al, 1990), raises some questions about the role of the menopause in the development of atherosclerosis.. Moreover, the importance of triglycerides as markers of the severity of CHD in women has been emphasized in several studies, (Fossati and Principe, L 1982) Therefore, the relatively well-documented menopausal effects on triglycerides need to be taken into account.

### **Conclusion**

This study indicates that menopause is associated with an adverse lipid profile in women, whereas it does not seem to consistently affect other cardiovascular risk factors. The menopausal effects on LDL-cholesterol reinforce the hypothesis that alterations in the lipid and lipoprotein metabolism lead post-menopausal women to an increased risk of CHD. Menopause is associated with enhanced- induced cardiovascular responses and elevated

blood pressure during workday. The effects may contribute to the risk of cardiovascular morbidity and mortality after menopause. Whether the deleterious influence of the menopause on lipids and lipoproteins can be attributed to the decline in endogenous estrogen cannot be ascertained. It is better to do more studies to clear up the role of endogenous estrogens on lipid metabolism and the atherosclerotic process in women.

**RECOMMENDATIONS :**

In postmenopausal women, treatment of hypertension and glucose intolerance should be priorities. Hormone replacement therapy (HRT) started soon after the menopause may confer cardiovascular benefit. Also, smoking cessation and keeping body weight within normal play a role in decreasing the risk of cardiovascular disease in menopause.

**References**

**Bonithon-Kopp C., Scarabin P. Y., Dame B., et al., (1990) :** Menopause- related changes in lipoprotein and some other cardiovascular risk factors. *Int J Epidemiol*; 19:42-8.

**Bush T. L., Criqui M. N., Cowan L. D., et al., (1987) :** Cardiovascular disease mortality in women ; results from the Lipid Research Clinics Follow Up Study. In Eker ED, Packard B, Wenger NK et al(Ed). *Coronary Heart Disease in Women Proceedings of NIH Workshop.* Haymarket Doyma, New York;106-11.

**Castelli W. P., Garrison R. J., Wilson P. W. F., et al., (1986) :** Incidence of coronary heart disease and lipoprotein cholesterol levels; Framingham study, *JAMM*; 256:2835-8.

**Collins P., Rosano G., Casey C., Daly C., et al., (2007) :** Management of cardiovascular risk in the menopausal women :a consensus statement of European cardiologists and gynecologists, *Climacteric*; 10: 508-26.

**Fossati P. and Principle L. (1982) :** Serum triglycerides calorimetrically with an enzyme that produces hydrogen peroxide. *Clin. Chem.*; 28:2077-80.

**Friedewald W. T., Leavy R. I., and Frederickson D. S. (1972) :**

Estimation of the concentration of low density lipoprotein cholesterol in plasma without use of centrifuge. *Clin. Chem.*; 18:599.

**Fruchart J. C., Beucler I., Blaton V., et al., (1982)** : Méthode sélectionnée pour le dosage du cholestérol des lipoprotéines non précipitables par le phosphotungstate de sodium en présence du chlorure de magnésium. *Information Scientifique du Biologiste*; 2:69-72.

**Hamman R. F., Bennett P. H. and Miller M. (1990)** : The effect of menopause on serum cholesterol in American (pima) & Indian women. *Am J.*, 102 : 164-9.

**Jensen J. (1991)** : Effects of sex steroids on serum lipids and lipoproteins. *Baillieres Clin Obstet Gynaecol*; 5:867-87.

**Kalsiwal R. R., Kulshreshtha A., Agrawal S., Bansal M. and Trehan N. (2006)** : Prevalence of cardiovascular risk factors in the Indian patients undergoing bypass surgery, *J Assoc. Physicians, India*; 54:371-75.

**Kane J. P., Malloy M. U., Ports T. A., et al., (1990)** : Regression of coronary atherosclerosis during treatment of familial hypercholesterolemia with combined drug regimens. *JAMM*; 264:3007-12.

**La Rosa J. C., Hunninghake D., Bush D., et al., (1990)** : The cholesterol fact, a summary of the evidence relating dietary fat, serum cholesterol and coronary artery disease ; joint statement by the American Heart Association and the National Heart, Lung and Blood Institute. *Circulation*; 81:1721-33.

**Levy R. I., Brensike J. F., Epstein S. E., et al., (1984)** : The influence of changes in lipid values induced by cholestyramine and diet on progression of coronary heart disease; results of the NHLBI Type II Coronary Intervention Study. *Circulation*; 69:325-37.

**Muldoon M. F., Manuck S. B. and Matthews K. A. (1990)** : Lowering cholesterol concentration and mortality; a quantitative review of primary prevention

trials. *Br Med J*; 301:309-14.

**Proudler A. J., Felton C. and Stevenson J. C. (1992)** : Aging and the plasma insulin, glucose and C-peptide response to I.V glucose in post-menopausal women. *Clin Sci*; 83:489-94.

**Roeschau P., Bernt E. and Gruber W. (1974)** : Enzymatic determination of total cholesterol in serum. *Z Klin Chem. Klin Biochemist.*; 12:226-27.

**Rosano G. M., Vitale C., Marazzi G. and Volterrani M. (2007)** : Menopause and cardiovascular disease: the evidence, *Climacteric*, 10 Suppl.; 1:19-24.

**Staessen J., Bulppit C. J., Fagard R., et al., (1989)** : The influence of menopause on blood pressure. *J Hum Hypertens*; 3: 427-33.

**Stampfer M. J. and Colditz G. A. (1991)** : Estrogen replacement therapy and coronary heart dis-

ease; a quantitative assessment of the epidemiologic evidence. *Prev Med*; 20:47-63.

**Stampfer M. J., Colditz G. A., Wellett W. C., et al., (1991)** : Post-menopausal estrogen therapy and cardiovascular disease, ten-year follow-up from the Nurses Health Study. *N Engl J Med*; 325:756-62.

**Trinder P. (1969)** : Determination of glucose in blood using glucose oxidase with an alternative oxygen acceptor. *Ann. Clin. Biochemist.*; 6:24.

**World Health Organization (1996)** : Research on the menopause in the 1990s. Technical report ser.866, Geneva, Switzerland.

**Zarate A., Saucedo R., Basest L. and Martinez C. (2007)** : Cardiovascular disease as a current heart threat of the older women. Relation to estrogens. *Gynecol. Obstet. Mex*; 75:286-92.



REPRINT

# BENHA MEDICAL JOURNAL

## UNCERTAIN ROLE OF MENOPAUSE IN CARDIOVASCULAR DISEASE RISK

**Abdalla M. El-Moslmani MD, Ashraf E. Belal MD  
and Abadalla E. Deiab MD**

**Published by  
Benha Faculty of Medicine**

*Volume 26 Number 3  
Sept. 2009*

## **A COMPARATIVE STUDY OF ADDING INTRATHECAL DEXMEDETOMIDINE VERSUS SUFENTANIL TO HEAVY BUPIVACAINE FOR POSTOPERATIVE ANALGESIA IN PATIENTS UNDERGOING INGUINAL HERNIAL REPAIR**

**Ibrahim F. A. Khalifa MD**

*From the department of anesthesia and surgical intensive care,  
Faculty of Medicine , Mansoura University, Egypt.*

### **Abstract**

*Fifty ASA Grade - I/II patients, scheduled for elective inguinal hernia repair. we have combined Inj. DEXM (5µg) and Inj. Sufentanil (5µg) with heavy Bupivacaine (0.5% 2 ml) using the intrathecal route for post operative analgesia. 25 patients in Group D (DEXM 0.5 ml) and Group S (Sufentanil - 0.1 ml + NS - 0.4 ml) added to 2 ml heavy Bupivacaine. Onset and duration of sensory and motor blockade, surgical condition and side effects were assessed. The duration of effective postoperative analgesia as assessed by Visual analogue scale (VAS) was not statistically significantly in between both groups. Cardiovascular and respiratory stability was maintained with no significant incidence of side effects in either group. No incidence of bradycardia, tachycardia or drowsiness in either group. The addition of DEXM (5 µg) and Sufentanil (5µg) intrathecally provide improved postoperative analgesia and hemodynamic stability. Dexm provide prolongs the postoperative analgesia as Sufentanil but with minimal side effects*

**Keywords :** *Intrathecal/dexmedetomidine/ Sufentanil/ postoperative analgesia*

### **Introduction**

Adequate postoperative pain control is essential to prevent adverse consequences of surgical insult. Spinal anesthesia has the

advantage of simplicity of technique, rapid onset of action and reliability in producing uniform sensory and motor blockade. Its main disadvantage relates to its

limited duration of action and hence lack of long lasting postoperative analgesia. To overcome these problems, administration of local anesthetics in combination with opioids intrathecally (Torda et al 1995 and Ping-Heng et al 2001) is an excellent technique for managing postoperative pain. Discovery of opioid receptors in spinal cord triggered the usage of intrathecal opioids (Saldman et al 1984).

Local anesthetics with opioids demonstrate significant synergy. They provide excellent analgesia with fewer drug requirements and decreased side effects. The use of intrathecal Fentanyl, a lipophilic opioid and recently Sufentanil, an even more lipophilic opioid improve intraoperative and postoperative analgesia with no adverse effects. DXM is a  $\alpha$  2-adrenoreceptor agonist that is approved as an intravenous sedative and coanalgesic drug. Its use is often associated with a decrease in heart rate and blood pressure (Venn and Grounds 2001).

Intrathecal and epidural characteristics of DXM were studied in

animals (Kalso et al 1991 and Savola et al 1990). Most of the clinical studies about intrathecal  $\alpha$  2-adrenoreceptor agonist are related to Clonidine. There is little in the literature about the use of intrathecal DXM with local anesthesia in humans. Kanazi et al 2006. found that 3  $\mu$ g DXM and 30  $\mu$ g Clonidine are equipotent intrathecally when added to Bupivacaine in patients undergoing urology procedures. The same author found that DXM and Clonidine produced significant short onset of sensory and motor block as well as significantly (longer duration of sensory and motor block than Bupivacaine alone without serious side effects. The aim of this study was to compare the effect of DXM 5 $\mu$ g versus Fentanyl 25  $\mu$ g on intraoperative analgesia and the duration of sensory & motor block when added to 10 mg intrathecal heavy Bupivacaine.

### **Material and Methods**

The present study was conducted in Mansoura University Hospital after obtaining institutional official committee clearance and written informed consent. fifty ASA Grade - I/II male aged 20-

60 years scheduled for elective inguinal hernia repair were selected. Exclusion criteria taken were, known contraindication to regional anesthesia, known sensitivity to study drugs and patients taking drugs that modified pain perception.

All patients were examined and investigated a day before surgery. Visual Analogue Scale (VAS) of 0-10 was shown to the patients and the procedure of postoperative measurement was explained in details, with (0) corresponding to no pain and (10) to the worst pain imaginable. All were kept fasting overnight and not received any premedication before surgery. I.V. line was secured and all were preloaded with Ringer Lactate 10 ml/kg. These patients were randomly assigned using sealed envelop technique to two groups in double blind manner. Group D (n= 25) received 2 ml of heavy Bupivacaine with 5  $\mu$ g (0.1 ml) DXM made up to 2.5 ml with NS (0.4 ml) and Group SF(n= 25) received 2 ml of heavy Bupivacaine with 5  $\mu$ g (0.1 ml) of Sufentanil made up to 2.5 ml with NS (0.4 ml). Subarachnoid block was performed at

L3-L4 interspace with 25 G Quincke spinal needle with patients in lateral position under all strict aseptic and antiseptic precaution after identification of clear free flowing CSF; study solution was injected. Patients were made supine and following were noted: The doctor anesthetist performing the block was blinded to the study drug and recorded the intraoperative data. Vital signs were recorded at 5 min interval intraoperatively until the end of surgery. In the Post Anesthesia Care Unit (PACU), vital signs were recorded every 15 min. Onset of spinal anesthesia (assessed by pinprick) The motor block was assessed according to the modified Bromage scale( Bromage 1965) Bromage 0, the patient is able to move the hip, knee and ankle; Bromage 1, the patient is unable to move the hip but is able to move the knee and ankle; Bromage 2, the patient is unable to move the hip and knee but able to move the ankle; Bromage 3, the patient is unable to move the hip, knee and ankle. The times to reach T10 dermatome sensory block, peak sensory level and Bromage 3 motor block were recorded before sur-

gery. The regression time for sensory and motor block were recorded in PACU. All durations were calculated considering the time of spinal injection as time zero. Patients were discharged from the PACU after sensory regression to S1 dermatome and Bromage 0. Assessment of pain intraoperatively and in PACU was done using visual analogue pain scale between 0-10 (0 = no pain, 10 = the most severe pain). Intraoperative nausea, vomiting, pruritus, shivering, additive analgesia drowsiness, hypoxemia (SpO<sub>2</sub> <90%) or respiratory depression (RR < 8/min). post operative rescue analgesia was provided by IM Diclofenac Sodium 1.5 mg/kg. sedation were recorded. The following sedation scale was used: 0 = no sedation, 1 = mild sedation, 2 = moderate sedation, 3 = deep sedation. Hypotension was defined as a decrease in systolic blood pressure > 30% of the baseline value or systolic blood pressure < 100 mm Hg, hypotension was treated with intravenous boluses of 3 mg Ephedrine and crystalloid fluids. Bradycardia was defined as a pulse rate of < 50 beat/ min and was treated with boluses of 0.3-

0.5 mg Atropine. Nausea & vomiting were assessed by nausea & vomiting score (0=no, 1=light, 2= moderate, and 3=severe.) and treated by 10 mg Metoclopramide. Quality of anesthesia (judged by surgeons), and the degree of intraoperative comfort (judged by patients) were recorded as excellent, satisfactory, or unsatisfactory.

#### **Statistical Methods**

Statistical analysis was done using Statgraphics centurion XV (Statpoint, Herdon, Virginia- USA). Data was expressed as either mean  $\pm$  standard deviation or numbers and percentages. The demographic data of patients were studied for each of the two groups. Continuous covariates (Age, BMI, and duration of surgery) were compared using analysis of variance ANOVA. For categorical covariates (sex, ASA class, nausea & vomiting, hypotension, bradycardia, use of Ephedrine, use of additive analgesia, the use of Atropine, and type of surgery). The comparison was studied using chi-squared test or the Fisher's exact test as appropriate, with the p value reported at the 95% confi-

dence interval. The level of significance used was  $p < 0.05$ .

### Results

All patients (n=50) completed the study; there was no statistical difference in patients' age, weight, height and duration of surgery between two groups as shown in (table 1).

The differences on mean pulse rate, mean arterial pressure between the groups were statistically insignificant ( $p > 0.05$ ) intraoperatively and postoperatively. None of the patients experienced respiratory depression, hypoxemia or sedation score  $> 2$ . All patients included in the study attained a T10 sensory level within 6 min. of intrathecal injection without any statistically significance differences in between both groups to allow surgery to proceed (table 2). The regression time to reach modified Bromage 0 in Group D was statistically significantly longer

than that for group SF,  $p < 0.05$ . The time reach S1 segment was statistically significantly longer in group D than in group S F  $p < 0.001$  (table 2). The mean duration of pain free period was not statistically significant in between both groups. Time to achieve peak sensory blockade, duration of sensory and motor blockade and duration of pain relief is shown in (table 2) in both the groups.

No patients in the two groups required additional analgesics intraoperatively. Overall Side effects was statistically significant lower in in patients of Group D compared to patients in Group SF ( $P < .001$ ) as shown in (table 3). Quality Of anesthesia (judged by surgeons), and the degree of intraoperative comfort (judged by patients) were statistically significantly better in DXM group in compared with SF group as shown in (table 4).

**Table 1:** Patients demographics. Values are median  $\pm$  SD

Variable	Group D (n = 25)	Group SF (n = 25)
Age	48.0 $\pm$ 9.9	45.6 $\pm$ 10.6
BMI (body mass index)	27.1 $\pm$ 6.1	33.3 $\pm$ 6.3
Duration of surgery (min)	57.0 $\pm$ 20.7	60.6 $\pm$ 18.8
Need for Ephedrine	5	9
Dose of Ephedrine (mg)	11.5 $\pm$ 1.95	15 .25 $\pm$ 9.6 )
Need for Atropine	1	3

**Table 2:** Characteristics of spinal block, data are shown as mean  $\pm$  SD. The maximal sensory block level is given as median (range).

Variable	Group D (N=25)	Group SF(N=25)	P VALUE
Time to reach T10 sensory block level (min)	5.5 $\pm$ 3.7	6.2 $\pm$ 1.3	.69
Time to reach peak sensory level	21.9 $\pm$ 3.6	19.9 $\pm$ 2.99	.21
Time to reach Bromage 3 motor block (min)	15.3 $\pm$ 5.3	14.9 $\pm$ 7.8	.96
Regression time to S1dermatome(min)	290.6 $\pm$ 55.2*	150.9 $\pm$ 42.6	.03
Time to regression to bromage0(min)	220 $\pm$ 43*	140 $\pm$ 86	<.001
Duration of pain relief	240 .2 $\pm$ 77.3	265.8 $\pm$ 112.3	.08

**Table 3:** Adverse effects of spinal block. Values are numbers (%)

Side effects	Group D (n=25)	Group SF (n=25)
Nausea/vomiting	1(4%)	3(10%)
Bradycardia	2(8%)	2(8%)
Hypotension	3(10%)	4(16%)
Pruritus	0	4(16%)
Respiratory depression	0	0
Shivering	0	5(20%)
Total	6(24%)	18(70%)

**Table 4 :** Quality of anesthesia assessed by patients and surgants. Data are expressed median(rang).

Variable	Group D (n=25)	Group SF (n=25)
Quality of anesthesia (by the patients)	4(2-4)*	2 (1-4)
Quality of anesthesia (by the surgants.)	4(3-4)*	3(1-4)



### Discussion

Present study reported that the supplementation of spinal Bupivacaine with 5  $\mu$ g DXM significantly prolonged both sensory and motor block compared with intrathecal 5 $\mu$ g Sufentanil and Bupivacaine in inguinal hernia surgery. Also DXM improves the quality of intraoperative analgesia and diminishes the risk of supplementation of GA.

Intrathecal injected Fentanyl/Sufentanil travel cephalad within the CSF, enter the spinal cord, where they bind to specific opioid receptors ( $\mu$ 1 and  $\mu$ 2) within the dorsal horn and non-specific sites within the white matter and traverse the dura matter to enter the epidural space where they bind to epidural fat. This results in rapid onset, limited and brief spread. Sufentanil (Octanol/water partition coefficient 1778) is considered 10 times as potent as Fentanyl (octanol/water portion coefficient 8130) when systemically administered.

Systemic opioid potencies correlate directly with opioid lipophilicity neglecting the need to cross

the blood brain barrier to gain access to the receptor site; but intrathecal drugs bypass the blood brain barrier and therefore their systemic potencies do not predict intrathecal potency, Sufentanil is nearly twice as potent as Fentanyl when administered intrathecally (Cohen and Cherry 1995).

Dahlgren 1997 compared the effects of intrathecal Fentanyl, Sufentanil and placebo when administered with hyperbaric Bupivacaine for caesarean delivery in 80 healthy patients. He concluded that addition of small doses of Fentanyl and Sufentanil to Bupivacaine intrathecally increased the duration of analgesia in the post operative period.

Roxane Fournier et al 2002 compared post operative analgesic effects of intrathecal Fentanyl and Sufentanil added to normal saline 2 ml given postoperatively intrathecally after elective total hip replacement surgery under continuous spinal anesthesia in geriatric patients as soon as they had a pain score more than 3. They concluded that both opioids provided satisfactory analgesia.

Interestingly, DXM is a highly selective  $\alpha$  2-adrenoreceptor agonist approved as intravenous sedative and adjuvant to anesthesia. DXM when used intravenously during anesthesia reduces opioid and inhalational anesthetics requirements (Fragen and Fitzgerald 1999, Martin et al 2002). The dose of DXM (5  $\mu$ g) used in present study was suitable and in compared with Clonidine a  $\alpha$  2-adrenoreceptor agonist, the affinity of DXM to  $\alpha$  2 receptors has been reported to be 10 times more than Clonidine (Eisanach et al 1996), moreover, Kalso et al 1991. and Post et al. 1992 reported a (1:10) dose ratio between intrathecal DXM and Clonidine in animals.

The clinical studies about the use of intrathecal DXM in surgical patients are scarce in the literature. Kanazi et al. 2006 found that 3 $\mu$ g DXM or 30  $\mu$ g Clonidine added to 13 mg spinal Bupivacaine produced the same duration of sensory and motor block with minimal side effects in urologic surgical patients. From Kanazi 2006 study and animal studies, we assumed that 3-5  $\mu$ g DXM

would be equipotent to 30-45  $\mu$ g Clonidine when used for supplementation of spinal Bupivacaine. Intrathecal DXM when combined with spinal Bupivacaine prolongs the sensory block by depressing the release of C-fibers transmitters and by hyperpolarization of pos-synaptic dorsal horn neurons. (Smith et al 1995 , Fairbanke and Wilcox 1999) Motor block prolongation by  $\alpha$  2- adrenoreceptor agonists may result from binding these agonists to motor neurons in the dorsal horn of the spinal cord.( Yaksh 1985 and Smith et al 1994)

Intrathecal 2-receptor agonists have been found to have antinociceptive action for both somatic and visceral pain. (Harada et al 1995 and Mark et al 1998). In this study, the intrathecal DXM and Bupivacaine block has resulted in significantly less side effects than intrathecal Fentanyl and Bupivacaine block. The most significant side effects reported about the use of intrathecal 2- adrenoreceptor agonists are bradycardia and hypotension, in present study, these side effects were not significant probably because we

used small dose of intrathecal DXM which was confirmed by the findings of Kanazi 2006 report. Mark et al 1998 confirmed that Both 5 and 10  $\mu$ g intrathecal Sufentanil provided adequate labor analgesia. Both doses were associated with measurable spinal (itching) and supraspinal (sedation, respiratory depression) side effects. The  $\alpha$ 2- receptor agonists are another important class of antishivering drugs that, unlike Meperidine, produce little respiratory toxicity. Intravenous Dexmedetomidine reduces both the vasoconstriction and shivering thresholds (Talke et al 1997).

### Conclusion

Intrathecal DXM supplementation of spinal block seems to be a good alternative to intrathecal Sufentanil since it produces prolonged sensory block, and it is evident that this type of block may be more suitable for major surgeries on the abdomen and lower extremities. Intrathecal dose of DXM use in present study needs further clinical studies to prove its efficacy and safety and to be considered the suitable dose of DXM for supplementation of spinal local

anesthetics. A drawback of DXM supplemented spinal block characteristics in this study is the increase in the duration of motor block which may not suit short term surgical procedures or ambulatory surgery.

In conclusion, 5  $\mu$ g DXM seems to be an attractive alternative as adjuvant to spinal Bupivacaine in surgical procedures especially in those that need quite long time with minimal side effects and excellent quality of spinal analgesia.

### References

**Bromage P. R. (1965)** : A comparison of the hydrochloride and carbon dioxide salts of Lidocaine and Prilocaine in epidural analgesia. *Acta Anesthesia Scand*; 16 : 55-69. (s)

**Cohen S. E. and Cherry C. M. (1993)** : Intrathecal Sufentanil for labor analgesia- sensory changes, side effects and fetal heart rate changes. *Anesthe Analg*; 77:1155-60. (s)

**Dahlgren G. (1997)** : Effects of intrathecal Sufentanil, Fentanyl and placebo with Bupivacaine for

elective caesarean section. Anesthe. Analgesia., Dec. (85): 1288-93. (s)

**Eisanach J. C. (1996)** : De Kock M, Klimscha W.  $\alpha$  2 adrenergic agonists for regional anesthesia. Anesthesiology : 85: 655-74.

**Fairbanke C. A. and Wilcox G. L. (1999)** : Spinal antinociceptive synergism between Morphine and Clonidine persists in mice made acutely or chronically tolerant to Morphine. J Pharmacol Exp Ther; 288: 1107-16.

**Fragen R. J. and Fitzgerald P. C. (1999)** : Effect of Dexmedetomidine on the minimum alveolar concentration (MAC) of Sevoflurane in adults age 55-70 years. J Clin Anesth; 11: 466-70.

**Harada Y., Nishioka K., Kitahata L. M., et al., (1995)** : Visceral antinociceptive effects of spinal Clonidine combined with morphine, enkephalin, or U50, 488H. Anesthesiology; 83:344-52

**Kalso E., Poyhia R. and Ro- semberg P. (1991)** : Spinal antinociceptive by Dexmedetomidine,

a highly selective  $\alpha$  2-adrenergic agonist. Pharmacol Toxicol; 68: 140-3

**Kanazi G. E., M. T. Aouad, S. I. Jabbour- Khoury, M. D. Al Jazzar, M. M. Alameddine, R. Al-Yaman, M. Bulbul and A. S. Baraka. (2006)** : Effect of low- dose Dexmedetomidine or Clonidine on the characteristics of Bupivacaine spinal block. Acta Anesthesiol Scand; 50: 222-117. DOI :

**Lawhead R. G., Blaxall H. S. and Bylund B. D. (1992)** : Alpha-2A is the predominant  $\alpha$  2 adrenergic receptor subtype in human spinal cord. Anesthesiology; 77: 983-91.

**Mark G. Norris M. D., Steven T. Fogel M. D. and Barbel Holtmann M. D. (1998)** : Intrathecal Sufentanil (5 vs. 10  $\mu$  g) for labor analgesia: Efficacy and side effects .Regional anesthesia and pain medicine;23;252-257.

**Martin E., Ramsay G. and Mantz J. (2000)** : Sum-Ping ST. the role of the alpha2-adrenreceptor agonist Dexmedetomidine in post-surgical sedation

in the intensive care unit. *J Intensive Care Med*; 18: 29-34.

**Roxane Fournier et al., (2002)** : Comparing postoperative analgesics effects of intrathecal Fentanyl and Sufentanil in patients posted for elective THR. *Anesth. Analgesia*. 918-922. (s)

**Saldman L. J., Cousins M. J. and Mather Le. (1984)** : Intrathecal and epidural administration of opioids. *Anesthesiology*.; 61: 276-310. (s).

**Savola M., Woodley J., Kending J. and Maze M. (1990)** : Alpha2B adrenoreceptor activation inhibits nociceptor response in the spinal cord of the neonatal rat. *Eur J Pharmacol*; 183: 740.

**Smith C., Birnbaum G., Carter J. L., Greenstein J. and Lublin F. D. (1994)** : Tizanidine treatment of spasticity caused by multiple sclerosis. *Neurology*; 44 (9):34-43.

**Smith M. S., Schumbra U. B., Wilson K. H., et al., (1995)** : Alpha 2 adrenergic receptor in human spinal cord: specific localized

expression of mRNA encoding alpha-2 adrenergic receptor subtypes at four distinct levels. *Brain Res*; 34 : 109-17

**Talke P., Tayefeh F., Sessler D. I., Jeffrey R., Noursalehi M. and Richardson C. (1997)** : Dexmedetomidine does not alter the sweating threshold, but comparably and linearly reduces the vasoconstriction and shivering thresholds. *Anesthesiology*.; 87 : 835-841.

**Tan Ping-Heng, Chia Yuan-Yi, Lo Yuan, Liu Kang, Yang Lin-Chang et al., (2001)** : Intrathecal Bupivacaine with Morphine or Neostigmine for postoperative analgesia after total knee replacement surgery. *Canadian Journal of Anesthesia*.; 48:551-56. (s)

**Torda T. A., Hann P., Mills G., Leon De et al., (1995)** : Comparison of extra-dural Fentanyl, Bupivacaine and two Fentanyl-Bupivacaine mixtures for pain relief after abdominal surgery. *British Journal of Anesthesia*; 74:35-40 (s)

**Venn R. M., Grounds R. M.**

**(2001)** : Comparison between nociceptive processing. *Pharmacol Biochem Behav*; 22:845-58  
Dexmedetomidine and Propofol  
for sedation in the Intensive  
care unit: patient and clinician  
perceptions. *Br J Anaesth* 87 :  
684.

**Yaksh T. L. (1985)** : Pharma-  
cology of spinal adrenergic sys-  
tems which modulate spinal

**Yaksh T. L. and Reddy S. V.  
R. (1981)** : Studies in primate on  
the analgesic effects associated  
with intrathecal actions of opi-  
ates,  $\alpha$ -adrenergic agonists, and  
Baclofen. *Anesthesiology*; 54:451-  
67.

REPRINT

# **BENHA MEDICAL JOURNAL**

**A COMPARATIVE STUDY OF ADDING  
INTRATHECAL DEXMEDETOMIDINE  
VERSUS SUFENTANIL TO HEAVY  
BUPIVACAINE FOR POSTOPERATIVE  
ANALGESIA IN PATIENTS  
UNDERGOING INGUINAL  
HERNIAL REPAIRE**

**Ibrahim F. A. Khalifa MD**

**Published by  
Benha Faculty of Medicine**

*Volume 26 Number 3  
Sept. 2009*

**EXERCISE INDUCED TRANSIENT  
ISCHEMIC LEFT VENTRICULAR  
DILATATION COULD BE A MARKER FOR  
SIGNIFICANT ISCHEMIA DURING  
MYOCARDIAL SCINTIGRAPHY**

**Ayman M. Kholify MD, Amany H. Mansour MD\*  
and Ihab. Y. Moursi MD\*\***

*Departments of Cardiology AL-Azher University, Clinical Pathology\*,  
Mansoura university Cardiothroracic, Zagazig university\*\*, Egypt*

**Abstract**

**Background:** *Transient ischemic dilatation of the left ventricle observed during single photon myocardial perfusion emission computed tomography is an important non-perfusion finding that may not only suggest underlying significant coronary artery disease but also an independent prognostic factor of adverse outcomes.*

**Aim of the work:** *To assess the correlation between transient ischemic dilation (TID) of the left ventricle and the amount of ischemia as detected by myocardial stress/rest Tc-99m Sestamibi Scintigraphy.*

**Patients and methods:** *The study retrospectively analyzed 460 patients who underwent myocardial perfusion imaging (MPI) with stress / rest sestamibi .Depending on the single photon emission computed tomography (SPECT) results, the patients were classified into two groups. Group 1 (N =231) with positive MPI, group 2 (N=229) with negative study. The severity of ischemia was graded as mild, moderate and severe. TID was visually assessed and correlated with SPECT result.*

**Results:** *The incidence of TID was significantly higher in patients with positive MPI than in patients with normal scan ( $p > 0.001$ ). Among patients with group 1 .TID was significantly higher in patients with significant ischemia ( moderate - large sized defects ) than patients with mild ischemia ( $p > 0.001$ ) . Also, patients with multiple perfusion defects had higher incidence of TID than patients with one perfusion defect ( $p > 0.001$ )*

**Conclusion:** *The study concluded that TID could be used as a marker for presence of significant myocardial ischemia during SPECT imaging.*



### **Introduction**

Myocardial perfusion SPECT (MPS) is a widely utilized non invasive imaging modality for the diagnosis of coronary artery disease. This modality permits quantitation of the perfused myocardium and functional assessment through gated SPECT (Poornima et al., 2004).

Patients with normal MPS have an excellent prognosis (Galassi et al., 2001). In contrast, the presence of high-risk findings, such as extensive ischemia, reversible ischemia in multiple segments, transient or persistent cavity dilatation, or a LVEF <45 percent, predict patients at high risk for hard cardiac events (HE) (cardiac death [CD] or myocardial infarction (MI) (Iskander et al., 1998) and may benefit from cardiac catheterization with possible revascularization (Gibbons et al., 1999). TID is considered when the image of the left ventricular cavity seems to be significantly greater after stress as compared with that at rest. TID has been classically described in myocardial perfusion examinations performed with the stress/redistribution thallium-201

protocol (Weiss et al ., 1987). In this protocol, the images following stress are obtained almost immediately after radiopharmaceutical injection, during the period when the myocardium is under the effects of physical stress. However, this signal has also been described in other myocardial perfusion scintigraphy protocols, such as the stress/rest sestamibi protocol Marcassa et al 1999. The tetrofosmin stress/rest protocol (Kinoshita et al., 2002) or the dual-isotope protocol (thallium rest/sestamibi stress) (Mazzanti et al .,1996). In these situations, the acquisition of images representative of perfusion under stress is performed some time after the exercise test (30 to 60 minutes), when the myocardium has already had time to recover from the mechanical dysfunction caused by stress. Transient ischemic dilation has also been described in situations in which the myocardium has not undergone a real stress situation, such as in the examination performed with the pharmaceutical stimulus of dipyridamole or adenosine (Takeishi et al., 1991) and (Iskandrian et al., 1990). Thus, some researchers

consider that the term dilation is imprecise and should represent, in most cases, an apparent dilation secondary to diffuse subendocardial ischemia.

Our study aimed to evaluate the significance of TID in patients with and without evidence of myocardial ischemia as detected by SPECT imaging.

### **Patients and Methods**

Four hundred and sixty patients (361 males, 99 females) were retrospectively studied. These patients had been referred to cardiology nuclear unit to undergo myocardial perfusion scintigraphy. Each patient was subjected to complete history taking, clinical examination and 2-day protocol with stress/rest sestamibi. Each patient had performed a symptom-limited exercise test on the standard Bruce protocol. At peak exercise 20-30mCi of sestamibi was injected intravenously. SPECT images were acquired thirty minutes after injection, cardiac SPECT imaging was performed. The images at rest were acquired sixty minutes after injection of 30 mCi of Tc-99m. Images were ob-

tained using double head scintillation camera (Toshiba) with a general all-purpose collimator interfaced to a dedicated computer system. All images were stored using a 64X64 matrix.

Qualitative and semiquantitative analyses of tomographic images were performed. Lung/Heart ratio was assessed. In the tomographic images, the short axis slices were analyzed from the apex to the base and long axis slices from septum to lateral wall. Short axis slices were divided into four segments (anterior, septal, inferior and lateral) at the apical, mid and basal ventricular level. In the vertical long axis, the apical portion midway between septum and lateral wall represent the apical segment resulting in a total 13 segments for each patient. Each segment of tomographic images were visually graded on 4 point scale 0=no uptake, 1=moderate to severe reduced uptake, 2=mild to moderate reduced uptake, 3=normal uptake. These semiquantitative scores have been shown to provide important prognostic information. Score of < 8 is small, 9-13 moderate, and > 13

large (Iskander et al., 1998)

TID was calculated visually, left ventricular dilatation was considered if left ventricle is noted to be larger following exercise than on the delayed images (Mazzanti et al., 1996).

#### **Statistical analysis**

All values were expressed as mean  $\pm$  standard deviation, paired t-test, ANOVA, chi-square were used in the analysis of the results in this study. For all statistical analysis, difference were considered significant for a P-value  $<0.05$ .

#### **Results**

Our patients had mean risk factors  $2.43 \pm 1.19$ . The highest risk factor was hypertension. Both groups I and II were compared in the aspects of age, gender, incidence of risk factors, chest pain, previous MI and other baseline data as shown in table 1. There is high incidence of DM and smoking in group I  $p < 0.05$ . Group I patients were older than group II (Mean age 53.85) and represented mainly in male gender (208/231). TID was present in one patient from

group II (0.004) while present in 107 patients (46.3%) in group I ( $p > 0.0001$ ) (fig 1)

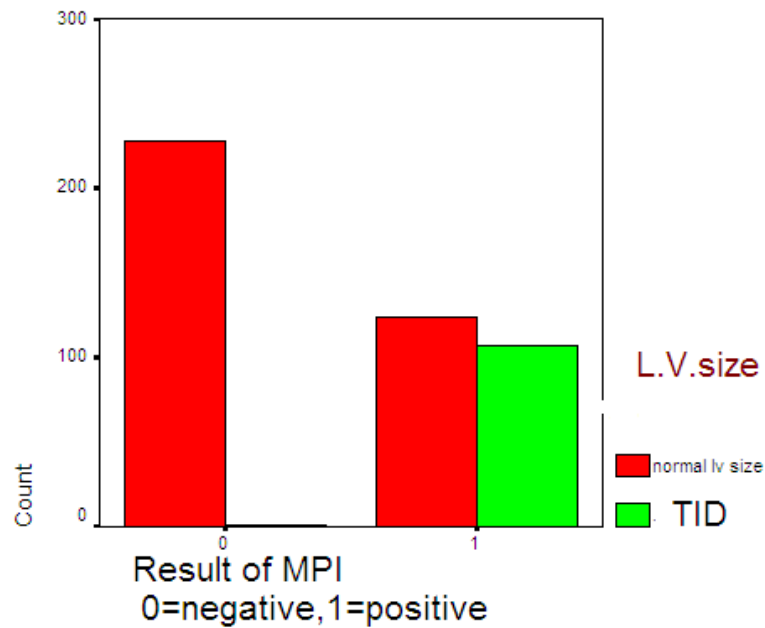
The incidence of TID in patients with significant ischemia (group Ib) was significantly higher than in patients with mild ischemia (group Ia) [102 pts (62%) Vs 5 pts (7%)  $p > 0.0001$ ] (fig. 2)

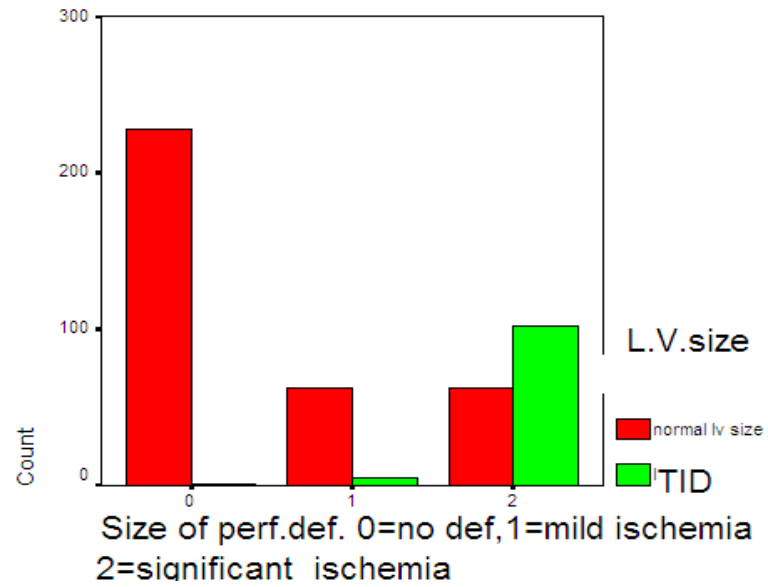
Forty of 59 patients (67.8%) with multiple perfusion defects (multi vessels disease) had higher incidence of TID than patients with only one perfusion defect (perf. def.) [67/172 (39%)  $p > 0.0001$ ]. Patients presented with TID had a higher incidence of increase lung uptake compared to patients with normal left ventricular size. Patients with TID were much more likely to have a history of prior MI, previous revascularization. pts with TID were more likely to have a positive ECG result. Figure (3) shows an example of a patient with TID

Stress/rest sestamibi MPS demonstrate total reversibility of apex, anterior, septum and lateral wall, also shows stress induced left ventricular dilatation

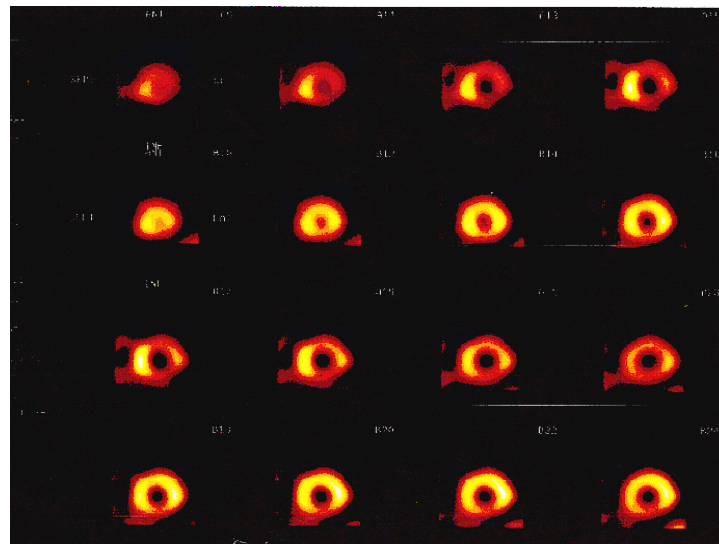
**Table 1:** Clinical correlates.

	<b>Group I</b>	<b>Group II</b>	<b>P value</b>
Age	53.65±8.7	50.47±8.8	<0.000
Male gender	90%	66.4%	<0.0001
Hypertension	55.8%	48.5%	<0.11
Diabetes mellitus	39.4%	25.3%	<0.001
Dyslipidaemia	48.5%	47.2%	<0.77
Smoking	64%	42%	<0.0001
Obesity	16%	22.3%	<0.89
Mean risk factors	2.57	2.28	<0.010
Previous MI	32.9%	0.4%	<0.0001
Previous revascularization	23.8%	3.9%	<0.0001
Resting chest pain	68%	74.2%	<0.13
Resting ECG changes	66.2%	35.4%	<0.0001

**Fig. 1 :** Incidence of TID according to result of MPI.



**Fig. 2 :** Incidence of TID according to result of size ischemia.



**Fig. 3 :** Stress/rest sestamibi MPS demonstrate total reversibility of apex, anterior, septum and lateral wall, also shows stress induced left ventricular dilatation

### Discussion

Patients with extensive perfusion defects on MPS are at high risk for hard cardiac events (CD or MI) (Iskander et al., 1998) and may benefit from cardiac catheterization with possible revascularization (Gibbons et al., 1999) While patients with normal MPS have an excellent prognosis (Galassi et al., 2001).

Transient ischemic dilatation of the left ventricle observed during MPS is an important non-perfusion finding that is often associated with severe and extensive coronary artery disease (CAD) (Romanens et al., 2001) as well as an increased risk of adverse outcomes (Abidov et al., 2005) An entirely normal stress MPS study does not always imply an excellent prognosis. In patients with otherwise normal MPS, TID is an independent and incremental prognostic marker of cardiac events even after significant clinical variables are accounted for. Evaluation of TID may be purely visual or based on calculation of TID ratio between stress and rest images .manual or automatic definition of the myocardial wall boundary is

possible in non gated images to calculate TID ratio (Kakhki et al., 2007). It was classically described using the protocol with stress/redistribution thallium. (Weiss et al.,1987) but may be present when other protocols, such as the stress/rest sestamibi - (Marcassa et al., 1996) or the dual-isotope protocols, are used (Mazzanti et al., 1996). The underlying mechanisms of TID include: 1- the presence of myocardial stunning as a possible cause of a true increase in LV size after exercise- or pharmacologically-induced ischemia, 2- a pseudo dilation effect due to diffuse sub endocardial ischemia (Kakhki et al., 2007).

This study analyzed whether the transient ischemic dilation value visually calculated is associated with moderate to extensive myocardial ischemia detected on the myocardial perfusion examinations performed using the 2-day protocol with stress/rest sestamibi.

The results obtained showed TID was significantly present in patients with ischemic heart disease. Furthermore, TID was signif-

icantly correlated with the extent (multiple perfusion defects) and severity of stress induced perfusion abnormality. Thus presence of TID suggesting greater ischemic burden .The patients with more severe and extensive ischemia, multi vessel-type of perfusion abnormality had more probability of having TID. Patients with TID were frequently diabetic, smoker, and had history of revascularization and prior MI, also they frequently associated with increase lung uptake and reduced duration of exercise time. The finding of TID was likely to represent extensive ischemia, because: 1) it was reversible; 2) the amount of ischemia had to be large enough to cause apparent transient ventricular enlargement even in a planar study; and 3) such ischemia was likely to be severe because it lasted for at least one-half hour after stress, a time at which usual exercise-induced ischemia would be expected to have been resolved.

Abidov et al., (2004) reported that an abnormal TID ratio had high sensitivity and specificity (71% and 87% respectively) for severe and extensive coronary artery

disease. In addition, multivariate logistic regression analysis showed that the presence of ischemia and LAD territory perfusion abnormalities were independent predictors of TID (Kakhki et al., 2007).

Some observers have reported a subgroup of patients with significant epicardial disease on angiography that shows TID in the absence of reversible defects (Kakhki et al., 2007) .Severe multi vessel disease producing global ischemia with uniform perfusion ("balanced ischemia") is the generally accepted explanation (Choong et al., 2004). In such cases, TID could be a very useful scan indicator of severe underlying CAD. However, cautious scan interpretation is required whenever. TID is associated with uniform perfusion because there is a high incidence of non coronary causes and technical artifacts .It is well documented that significant epicardial atherosclerotic disease could be present even if there is no angiographic evidence of disease. This has been convincingly shown by intravascular ultrasound in the presence of diffuse disease and arterial remodel-

eling. Several other causes of TID in the absence of significant epicardial stenoses have been reported. These include severe hypertension with myocardial hypertrophy; hypertrophic cardiomyopathy; and dilated cardiomyopathy (Robinson et al., 2007). Reduced coronary flow reserve has been reported in these patients (Kakhki et al., 2007). Also small left ventricles could be more prone to elevated TID ratios for technical reasons (Hung et al., 2007). TID occurring in the absence of perfusion defects was associated with a worse prognosis than otherwise attributed to patients with normal SPECT MPI and no TID (Abidov et al., 2007).

When TID is seen without perfusion defects, the interpreting physician should carefully scrutinize all of the available clinical and stress test data for other signs of ischemia to identify patients in whom it might be appropriate to test further for possible extensive CAD. For example if the TID in "normal" perfusion MPS is associated with post-stress stunning, as manifested by new regional wall motion abnormalities, it is more likely that the patient

has severe CAD as a cause of TID and catheterization may be appropriate (Abidov et al., 2005).

### **Conclusion**

Our data showed TID was significantly present in patients with ischemic heart disease. Furthermore, it was significantly correlated with the extent and severity of stress induced perfusion abnormality. Also it was associated with other higher risk MPS variables (presence of reversible perfusion defects, extent and severity of ischemia and increase lung uptake). Thus, presence of TID suggesting a greater ischemic burden and could be a marker for significant ischemia during Myocardial Tc-99m Sestamibi Scintigraphy

### **References**

**Abidov A., Bax J. J., Hayes S. W., Cohen I., Nishina H., Yoda S., et al., (2007)** : Integration of automatically measured transient ischemic dilation ratio into interpretation of adenosine stress myocardial perfusion SPECT for detection of severe and extensive CAD. *J Nucl Med.* 2004; 45:1999.

**Abidov A. and Berman D. S.**



(.2005) : Transient ischemic dilation associated with post-stress myocardial stunning of the left ventricle in vasodilator stress myocardial perfusion SPECT: True marker of severe ischemia? ;J Nucl Cardiol; 12 : 258-60.

**Abidov A., Germano G. and Berman D. S. (2007)** : Transient ischemic dilation ratio: A universal high-risk diagnostic marker in myocardial perfusion imaging. J Nucl Cardiol.; 14: 497-500.

**Choong K. K. L. and Russell P. A. (2004)** : Transient left ventricular dilatation in the absence of epicardial disease on angiography. Clin Nucl Med.; 29:348-51.

**Galassi A. R., Azzarelli S., Tomaselli A., et al., (2001)** : Incremental prognostic value of technetium-99m-tetrofosmin exercise myocardial perfusion imaging for predicting outcomes in patients with suspected or known coronary artery disease. Am J Cardiol.; 88:101-106.

**Gibbons R. J., Chatterjee K., Daley J., et al., (1999)** : ACC/AHA/ACP-ASIM guidelines for the

management of patients with chronic stable angina: J Am Coll Cardiol.; 33: 2092-2197 .

**Hung G. U., Lee K. W., Chen C. P., Lin W. Y. and Yang K. T. (2005)** : Relationship of transient ischemic dilation in dipyridamole myocardial perfusion imaging and stress-induced changes of functional parameters evaluated by TI-201 gated SPECT. J Nucl Cardiol.; 12:268-75.

**Iskander S. and Iskandrian A. E. (1998)** : Risk assessment using single-photon emission computed tomographic technetium-99m sestamibi imaging. J Am Coll Cardiol.; 32:57-62.

**Iskandrian A. S., Heo J., Nguyen T., Lyons E. and Paugh E. (1990)** : Left ventricular dilatation and pulmonary thallium uptake after single-photon emission computer tomography using thallium-201 during adenosine-induced coronary hyperemia. Am J Cardiol; 66 : 807-11.

**Kakhki V. R., Sadeghi R. and Zakavi S. R. (2007)** : Assessment of transient left ventricular dila-

tion ratio via 2-day dipyridamole Tc-99m sestamibi nongated myocardial perfusion imaging. *J Nucl Cardiol.*; 14:529-36.

**Kinoshita N., Sugihara H., Adachi Y., et al., (2002)** : Assessment of transient left ventricular dilatation on rest and exercise on Tc-99m tetrofosmin myocardial SPECT. *Clin Nucl Med*; 27: 34-9.

**Marcassa C., Galli M., Baroffio C., Campini R. and Giannuzzi P. (1999)** : Transient left ventricular dilation at quantitative stress-rest sestamibi tomography: clinical, electrocardiographic, and angiographic correlates. *J Nucl Cardiol*; 6: 397-405.

**Mazzanti M., Germano G., Kiat H., et al., (1996)** : Identification of severe and extensive coronary artery disease by automatic measurement of transient ischemic dilation of the left ventricle in dual-isotope myocardial perfusion SPECT. *J Am Coll Cardiol*; 27: 1612-20.

**Poornima I. G., Miller T. D., Christian T. F., Hodge D. O., Bailey K. R. and Gibbons R. J.**

**J. (2004)** : Utility of myocardial perfusion imaging in patients with low-risk treadmill scores. *Am Coll Cardiol*, 21; 43(2):194-9.

**Robinson V. J., Corley J. H., Marks D. S., Eberhardt L. W., Eubig C., Burke G. J., et al., (2000)** : Causes of transient dilatation of the left ventricle during myocardial perfusion imaging. *Am J Roentgenol.*; 174: 1349-52.

**Romanens M., Gradel C., Sanner H. and Pfisterer M. (2001)** : Comparison of 99mTc-sestamibi lung/heart ratio, transient ischaemic dilation and perfusion defect size for the identification of severe and extensive coronary artery disease. *Eur J Nucl Med*; 28:907-10.

**Takeishi Y., Tono-oka I., Ikeda K., Komatani A., Tsuiki K. and Yasui S. (1991)** : Dilatation of the left ventricular cavity on dipyridamole thallium-201 imaging: a new marker of triple-vessel disease. *Am Heart J.*; 121: 466-75.

**Weiss A. T., Berman D. S., Lew A. S., et al., (1987)** : Tran-

Ayman M. Kholify, et al...

---

sient ischemic dilation of the left ventricle on stress thallium-201 Scintigraphy : a marker of severe and extensive coronary artery disease. J Am Coll Cardiol; 9: 752-9.

REPRINT

# **BENHA MEDICAL JOURNAL**

**EXERCISE INDUCED TRANSIENT  
ISCHEMIC LEFT VENTRICULAR  
DILATATION COULD BE A MARKER  
FOR SIGNIFICANT ISCHEMIA DURING  
MYOCARDIAL SCINTIGRAPHY**

**Ayman M. Kholify MD, Amany H. Mansour MD  
and Ihab. Y. Moursi MD**

**Published by  
Benha Faculty of Medicine**

*Volume 26 Number 3  
Sept. 2009*

## **TREATMENT OF TIBIAL PLATEAU FRACTURES BY ILIZAROV EXTERNAL FIXATOR**

**Mohamed Abd El-Wahab MD**

*Department of Orthopedic Surgery, Mansoura Faculty of Medicine, Egypt.*

### **Abstract**

*This study was designed to assess results of Ilizarov wire external fixation using a ligamentotaxis technique for tibial plateau fractures.*

*Twenty two patients underwent Ilizarov external fixation for tibial plateau fractures. The mean patients age was 31 years (22-62 years). 19 were closed and 3 were open injuries. Fractures were classified according to Schatzker's staging system. After a minimal of 1 year follow-up each affected knee was evaluated using Rasmussen's 30-point clinical grading system and radiological evaluation.*

*There were 14 type-V and 8 type-VI Schatzker tibial plateau fractures. Complications consisted of: 2 superficial infections, 3 pin site infections, and 1 peroneal nerve palsies. No soft tissue necrosis or devitalisation occurred. The mean interval between surgery and full weight bearing was 3.2 months (rang 2.8 - 4.7 months). The mean range of knee movement was 130°. The mean Rasmussen radiological score was 13 (range, 10-17): excellent in 7, good in 12, and fair in 3. The mean Rasmussen functional score was 24 (range, 15-28): excellent in 8 patients, good in 10, and fair in 4.*

*Ilizarov external fixation allows anatomical reconstruction of the articular surface, stable fixation of fracture fragments, early movement of the joint, and care of associated soft tissue injuries, without a high rate of complications.*

### **Introduction**

Complex fractures of the tibial plateau, types V and VI according to the Schatzker classification, are difficult to treat and represent one

of the most challenging problems in orthopedic surgery. To achieve good results, the fractures should be anatomically reduced and adequately stabilized, but the optimal

treatment of complex proximal tibial fractures has remained controversial (Watson JT, 1994). Non-operative measures such as closed reduction and casting have yielded poor results and are not recommended for complex fractures of the tibial plateau (Cole et al 2004). Methods of acute open reduction and internal fixation with plates and screws of complex fractures of the tibial plateau have a high rate of complications, mainly infections, posttraumatic deformities, inability to obtain a reduction, wound breakdown, poor outcome despite articular reduction because of stiffness, pain, deformity, wound problems, instability, and soft tissue problems. The major concern is their invasiveness because of the additional trauma caused by operative soft tissue stripping and dissection (Mills and Nork 1998). Medial and lateral plate stabilization of comminuted bicondylar tibial plateau fractures with dual incisions is a useful treatment method; however, residual dysfunction is common (Sirkin et al 2000). External fixation has been gaining increasing interest and application during the past 20 years, to decrease

the rate of complications related with plating (Piper et al 2005). Minimally invasive techniques using periarticular fine wires allow rigid fixation of small pieces of cancellous bone and intra-articular fractures, easy wound surveillance, early joint mobilisation and weight bearing, and minimal soft tissue disruption (Schatzker et al 1979). We therefore evaluated the clinical results of patients with high-energy tibial plateau fractures treated with Ilizarov wire external fixator, using a ligamentotaxis technique and no additional stabilisation.

### **Materials and Methods**

Twenty two patients underwent Ilizarov wire external fixation for high-energy tibial plateau fractures. The mean patient age was 31 (range, 22-62) years. 12 injured the right and 10 the left knee. 19 were closed and 3 were open injuries. 7 patients had associated fibular head and neck fractures. Injury mechanism were: fall from motorcycle in 5 patients, motor vehicle accident in 7 patients and fall from a height in 10 patients.

No other major organ or skeletal injury.

Anteroposterior radiographs were used to determine the extent of medial and lateral plateau involvement, whereas lateral radiographs were used to gauge the extent of posterior displacement of condyles, degree of articular comminution, and joint depression. Fracture patterns were classified according to Schatzker's staging system (fig.1).

The extent of articular condylar depression was measured either from the remaining intact articular surface or from a line drawn as an extension of the other tibial condyle to the point of maximum depression.

Condylar widening (an indirect indicator of articular comminution) was measured in relation to the intact femoral condyle. Open fractures were immediately irrigated and debrided prior to definitive fixation. 8 of 19 closed fractures had severe soft tissue injuries, as : compartment syndrome, abrasion, contusion, crushing, or marked swelling. Prophylaxis with a cephalosporin an-

tibiotic was used routinely.

#### **Operative Technique:**

We used the the Technique of ligamentotaxis described by Kataria et al (2007) : -

The patient was positioned on a radiolucent operating table. Knowledge of neurovascular anatomy was a prerequisite for pin placement using the circular frame. Fine wires were placed through safe tissue corridor.

The principle of ligamentotaxis was used to achieve metaphyseal reduction.

Concomitant soft tissue injuries such as meniscal, cruciate, or collateral ligament injuries were left alone at this stage, and the knee was spanned by the fixator. Two to three 1.8-mm wires were inserted through the femoral condyles at the level of superior pole of patella and were tensioned to an adequately sized ring placed parallel to the knee joint axis. A second ring was placed in the tibia, just distal to the metaphyseal component of the fracture and the wires were tensioned on

it. Threaded rods were then used to connect these 2 rings (spanning the knee joint).

Closed reduction was performed using the principle of ligamentotaxis. If closed reduction failed indirect open reduction was done, through a 3- cm incision just lateral or medial to the tibial crest, the crushed metaphyseal component was lifted to restore the articular surface. The defect so created in the metaphyseal region was buttressed with bone grafts.

After achieving adequate reduction, 2 to 4 counteropposed olive wires (1.8-mm Kirschner wires with 4-mm beads located eccentrically in the wires) were placed in the juxta-articular bone supporting the soft cancellous bone fragments, parallel to the knee joint, each was tensioned to 30 kg and attached to the proximal fixation ring. The juxta-articular pins were placed at least 15 mm away from the joint surface to prevent synovial contact. Each wire was positioned centrally in the midportion of each condylar fragment and perpendicular to the major frac-

ture lines, so as to act in a lag fashion and provide maximal intercondylar compression.

This ring was placed at the level of fibular head, which was used as a buttress plate when intact. By placing an olive wire through fibular head obliquely into the lateral condyle and tensioning it, the fibular head was compressed into the lateral condyle. Wires were then attached and tensioned to this ring. The distal ring was placed just proximal and parallel to the ankle joint. Fixator rings should allow 1.5 cm of clearance over the anterior crest of the tibia and 3 to 4 cm of clearance around the posterior calf to accommodate postoperative swelling. Care was taken to restore the mechanical axis in relationship to the condyles. Isometric quadriceps exercise and hip raising exercises were started from postoperative day .

The femoral ring was removed at 3 weeks and knee mobilisation initiated. Weight bearing status was touch down initially, then advanced to partial when callus was noted on radiographs. Serial radiographs were taken at 2-week in-

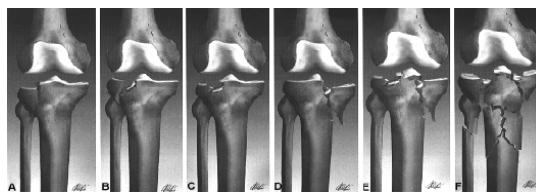


tervals to detect any deviation of the mechanical axis during external fixation.

Radiographic healing was defined as obliteration of the major fracture line in both views. Clinically, healing was defined as the ability to bear full weight with a varus and valgus stress to the injured tibia without pain.

After radiographic healing, frame dynamisation was performed by loosening proximal and distal rings to decrease pin bone stresses and to transmit weight-

bearing forces to the bone. Incomplete fracture healing was assumed when pain or subtle radiographic changes were present after frame dynamisation. The frame was retightened to allow further consolidation. Two patients required bone grafting to achieve union. Further procedures, adjustment of frames, time during fixation, time to union, and complications were recorded. At the final follow-up (minimum of 1 year), patients were evaluated using the Rasmussen 30-point clinical grading system and the Rasmussen radiological evaluation of the knee (Rasmussen 1973).



Schatzker's classification of Tibial Plateau Fracture. Courtesy : Rockwood and Green's Fractures in Adults. 4<sup>th</sup> Edition. Lippincott-Raven Publishers).

### Results

There were 14 type-V and 8 type-VI Schatzker tibial plateau fractures. The mean interval between injury and surgery was 7 (range, 2-21) days. Impending compartment syndrome (in 5 patients) was the most common cause of delay in surgery. No patient required blood transfusion. The mean hospital stay was 10 (range, 5-28) days. The mean interval between surgery and full weight bearing was 3.2 (range, 2.8-4.7) months.

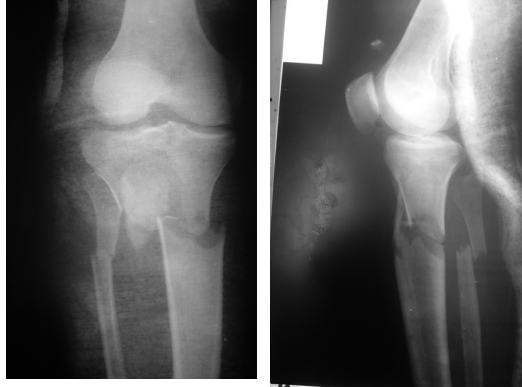
Ligamentotaxis technique alone was sufficient to reduce the fracture in 15 out of 19 closed injuries, while indirect open reduction was done in the remaining 4 patients. There was no non-union, septic arthritis, myositis ossificans, overt pulmonary embolism or deep venous thrombosis. Neither was there soft tissue necrosis or devitalisation. Complications included superficial infection in 1 patient, pin site infection in 3 patients, and peroneal nerve palsy in 1 patient.

The respective mean values for fracture depression and displace-

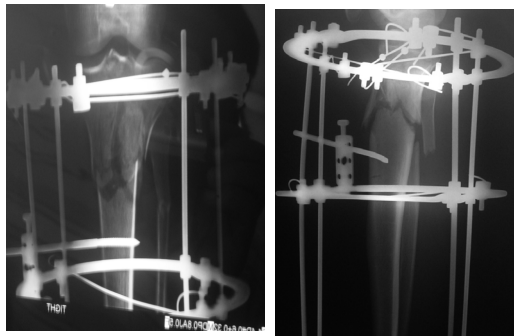
ment were 8.2 (range, 3-17) mm and 11.3 (range, 4-28) mm preoperatively and 1.6 (range, 0-7) mm and 2.2 (range, 0-5) mm postoperatively, as assessed by condylar widening.

The mean Rasmussen radiological score was 14 (range, 10-18): excellent in 7, good in 12, and fair in 3. Although varus or valgus instability was noted in 7 patients, none of them complained of functional instability. The mean range of knee movement was 2° (range, -4°-8°) of extension to 132° (range, 90° - 140°) of flexion. Knee movement was significantly more improved in patients starting mobilization within 3 weeks compared to those starting later. Four patients complained of an occasional ache on exertion. 20 of 22 patients could walk normally outdoors for at least one hour. The remaining 2 described decreased walking capacity (about half an hour), one of them needed to change his occupation.

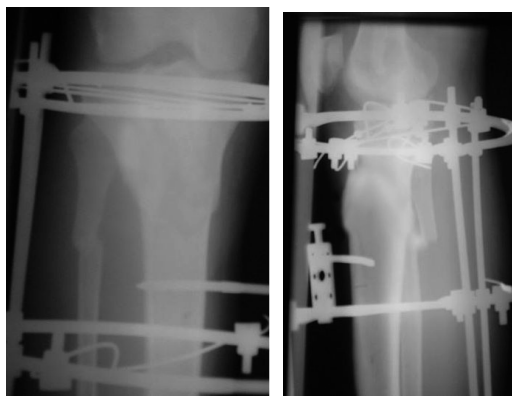
The mean Rasmussen functional score was 24 (range, 15-28): excellent in 8, good in 10, and fair in 4.



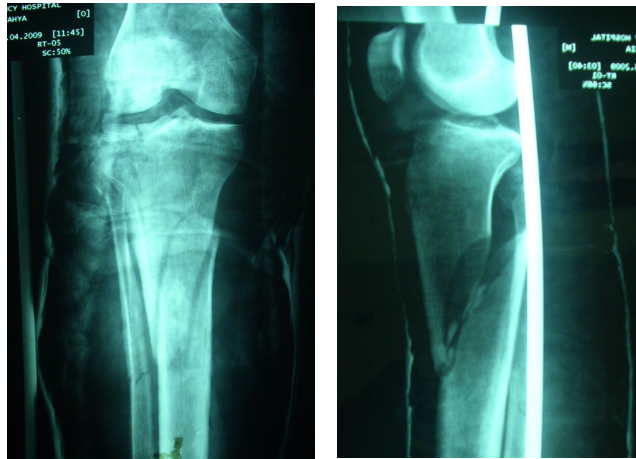
AP, Lat. X-ray of 40 years old man with tupe VI tibial plateau fr.



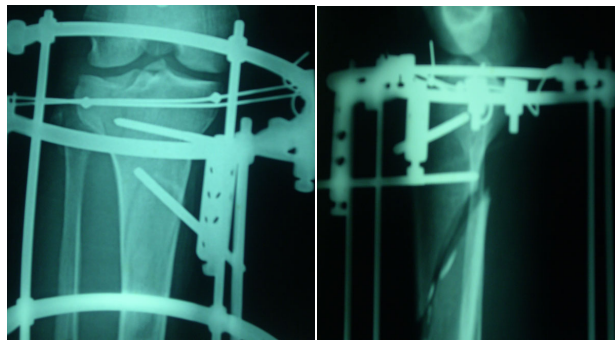
After one month



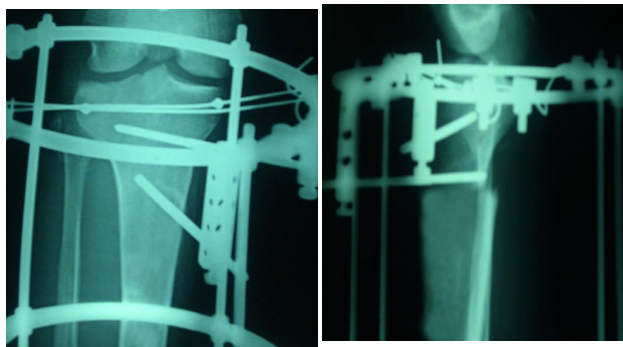
AP, Lat. X-ray 3 months after surgery with complete union of fr.



AP, Lat. X-ray of 32 years old man with tupe VI tibial plateau fr.



After one month



AP, Lat. X-ray 4 months after surgery with complete union of fr.

### **Discussion**

Treatment of high-energy tibial plateau fractures remains controversial. Traction and cast bracing provides poor results. (Decoster et al 1988) open reduction and internal fixation with double plating requires large amounts of soft tissue mobilisation and stripping to achieve satisfactory results. This devitalises soft tissue and hinders wound healing (Christnsen et al 1990). Moore and his associates 1987 reported infection rate 23% with dual plating of bicondylar fractures. Young and his associates (1994) reported high complication rate (87.5% deep infection rate) with dual plating for comminuted or bicondylar fractures. Hybrid fixation using lateral open reduction and internal fixation combined with unilateral external fixation does not address medial condylar comminution, because of the larger diameter of half pins and poor purchase in metaphyseal bone (Rangitsch et al 1993).

Limited internal fixation or lateral open reduction and internal fixation alone incompletely address the metadiaphyseal dissoci-

ation, resulting in collapse beneath the unsupported plateau (Stannard et al 2004).

Closed reduction or limited open reduction using small tensioned wires prevents further iatrogenic soft tissue injury and minimises additional devitalisation of the bone and periosteal and endosteal blood supply. It offers superior juxta-articular, metaphyseal purchase, fixes small cancellous osteoporotic fracture fragments, and allows for early range of movement and weight bearing. This reduces hospital stays and costs (Katsanis et al 2005). Maurio and his associates 2007 reported that the olive wire provides superior reduction and interfracture compression of metaphyseal fracture components and facilitates fine adjustment of rotational deformity. Early weight bearing stimulates fracture healing by axial micromotion without shear. Simultaneous distraction on both sides of the joint helps to achieve a ligamentous reduction. Small wire external fixation combines the benefit of traction, external fixation, and limited internal fixation, whilst allowing accessibil-

ity to the soft tissue for wound checks, pin care, dressing changes, measurement of compartment pressure, and monitoring of neurovascular status. Thus, it is indicated in periarticular fractures with metaphyseal / subchondral comminution that precludes routine plate and screw stabilisation. It is also indicated in plateau fractures that present with diaphyseal metaphyseal comminution and major extension into shaft region, as well as in complex fractures with soft tissue-associated compartment syndrome and loss.

In this study, we used Ilizarov external fixator in 22 patients with high energy tibial plateau fractures. The mean interval between injury and surgery was 7 (2:21 days). The mean hospital stay was 10 (rang 5-28 Days). The mean interval between surgery and full weight bearing was 3.2 Months. Complications included superficial infection in 2 patients, pintract infection in 3 Patients and peroneal nerve palsy in 1 patientn.

The mean functional score was excellent in 8 patients, good in 10 patients and fair in 4 patient.

These results correlate with that of kataria et al 2008 who used circular external fixator with the same principle of ligamentotaxis for reduction and fixation of tibial plateau fractures. They assumed that, a mechanically stable and adjustable ring fixator can span across a fracture gap in cases with comminuted or minimal bone loss. Compression can be directed across the site of bone loss or fracture gap without additional bone grafting. Rotational and translational deformities can be corrected as consolidation progresses.

When surgery is performed early, anatomical reduction and ligamentotaxis are more easily achieved, with the extent of open surgery minimised. Wire external fixation is the only viable option for early surgery, whenever severe soft tissue injuries are present.

Mourizio and his associate 2007 reported that full ring stabilisation is preferable to monolateral shaft stabilisation because the cantilever loading is accentuated when a proximal ring is attached to a solitary diaphyseal bar, and

the monolateral construct cannot easily dynamise the fixator. Adequacy of reduction is the most important factor to predict outcome. Intra-articular comminution with depression is difficult to treat; even if accurate anatomical reduction is obtained, late collapse and deformity on weight bearing precludes good functional results.

Range of knee movement was better in patients starting mobilisation at the third week postoperatively. Longer immobilisation attained a mean range of movement of 15° less than that achieved by earlier mobilisers. Results improved with experience, careful preoperative planning, and thorough knowledge of neurovascular anatomy.

Pin tract infection is a potential problem despite the use of small wires.

To avoid the disastrous complication of septic arthritis, we recommend placing wires at least 15 mm away from the joint surface.

### Conclusion

Ilizarov external fixation seems to offer a promising results in

treatment of high-energy tibial plateau fractures. It allows nearly anatomical reconstruction of the articular surface, stable fixation of fracture fragments, early rehabilitation of the joint, and care of associated soft tissue injuries, without a high rate of complications.

### References

**Christensen K., Powell J., Bucholz R. and Stills M. (1990) :** Early results of combined internal-external fixation for treatment of high-grade tibial plateau fractures. *J Orthop Trauma* ;4:226.

**Cole P. A., Zlowodzki M. and Kregor P. J. (2004) :** Treatment of proximal tibia fractures using the less invasive stabilization system: surgical experience and early clinical results in 77 fractures. *J Orthop Trauma*; 18:528-35.

**DeCoster T. A., Nepola J. V. and El-Khoury G. Y. (1988) :** Cast brace treatment of proximal tibia fractures. A ten-year follow-up study. *Clin Orthop Relat Res*; 231:196-204.

**Dimitris Katsenis, Athanasios Vasilis, Megas Panayiotis,**

Tillianakis Minos, and Elias Lambiris Minimal Internal Fixation Augmented by Small Wire Transfixion Frames for High-Energy Tibial Plateau Fractures. J Orthop Trauma Volume 19, Number 4, April 2005.

**Kataria H., Sharma N. and Kanojia R. K. (2007)** : Small wire external fixation for high-energy tibial plateau fractures. Journal of Orthopaedic Surgery;15(2):137-43.

**Maurizio A., Catagni M. D., Giulia Ottaviani M.D., PhD. and Massimiliano Maggioni MD. (2007)** : Treatment Strategies for Complex Fractures of the Tibial Plateau With External Circular Fixation and Limited Internal Fixation. J Trauma.; 63:1043-1053.

**Mills W. J. and Nork S. E. (2002)** : Open reduction and internal fixation of high-energy tibial plateau fractures. Orthop Clin North Am; 33:177-98.

**Moore T. M., Patzakis M. J. and Harvey J. P. (1987)** : Tibial plateau fractures: definition, demographics, treatment rationale,

and long-term results of closed traction management or operative reduction. J Orthop Trauma;1:97-119.

**Rasmussen PS. (1973)** : Tibial condylar fractures. Impairment of knee joint stability as an indication for surgical treatment. J Bone Joint Surg Am;55:1331-50.

**Rangitsch M. R., Duwelius P. J. and Colville M. R. (1993)** : Limited internal fixation of tibial plateau fractures: a prospective protocol. J Orthop Trauma ;7:168-9.

**Schatzker J., McBroom R. and Bruce D. (1979)** : The tibial plateau fracture. The Toronto experience 1968-1975. Clin Orthop Relat Res; 138:94-104.

**Sirkin M. S., Bono C. M., Reilly M. C. and Behrens F. F. (2000)** : Percutaneous methods of tibial plateau fixation. Clin Orthop Relat Res;375:60-8.

**Stannard J. P., Wilson T. C., Volgas D. A. and Alonso J. E. (2004)** : The less invasive stabilization system in the treatment of



complex fractures of the tibial plateau: short-term results. *J Orthop Trauma*;18:552-8.

**Piper K. J., Won H. Y. and Ellis A. M. (2005)** : Hybrid external fixation in complex tibial plateau and plafond fractures: an Australian audit of outcomes. *Injury*;36:178-84.

**Watson J. T. (1994)** : High-energy fractures of the tibial plateau. *Orthop Clin North Am*; 25:723-52.

**Young M. J. and Barrack R. L. (1994)** : Complications of internal fixation of tibial plateau fractures. *Orthop Rev*; 23 : 149-54.

REPRINT

# **BENHA MEDICAL JOURNAL**

**TREATMENT OF TIBIAL PLATEAU  
FRACTURES BY ILIZAROV  
EXTERNAL FIXATOR**

**Mohamed Abd El-Wahab MD**

**Published by  
Benha Faculty of Medicine**

*Volume 26 Number 3  
Sept. 2009*

## **RESULTS OF TREATMENT OF UNUNITED FRACTURES OF SCAPHOID BONE BY ILIAC BONE GRAFT AND KIRSCHENER WIRE FIXATION**

**Mohamed Abd El-Wahab MD**

*Department of Orthopedic Surgery, Mansoura Faculty of Medicine, Egypt.*

### **Abstract**

*Fractures of the scaphoid comprise 70% to 80% of injuries to carpal bone. Studies suggest that only 5% to 10% of these fractures proceed to non-union. This risk of delayed healing or non-union have been attributed to delay in beginning treatment, inadequate immobilization, displacement of the fragments, instability due to ligamentous injury or inadequate blood supply of the proximal fragment.*

*Non-union of the scaphoid usually causes pain and weakness, which interfere with work and sport, also non-union would most probably result in carpal osteoarthritis.*

*Sixteen patients with symptomatic non-union of the scaphoid had been treated by iliac bone graft and Kirschener wire fixation in Mansoura University Hospital. The patients presented with pain, limited range of wrist motion and weak grip strength. The average age was 27.6 years. The average time of delay before the operation was 32 months (3 months - 60 months). The average duration of follow up period was 9 months.*

*Union was achieved in 15 patients (93.75%) at an average period of 20 weeks (16-28 weeks). According to Weightington wrist scoring system: 13 patients (81.25%) had excellent results, 2 patients (12.5%) had good results, one patient (6.25%) had poor results, and no fair results.*

*Iliac bone graft and Kirschner wire fixation is an effective procedure for management of scaphoid non-union. It is simple, economic procedure that does not need special equipments and fixation does not add much to the operative time.*

### **Introduction**

Fracture of the scaphoid bone is the most common fracture involving the wrist. It comprises 70% to 80% of injuries to carpal bone. (Roolker et al, 1996). Failure to recognize the original injury, inappropriate or incomplete treatment, displacement of fragments or instability due to ligamentous injury or inadequate blood supply of the proximal fragments are reasons, for the prevalence of scaphoid nonunion. (Stark and Richard, 1988).

Studies suggest that only 5% to 10% of fractures of scaphoid bone proceed to nonunion (Cooney and Linschaid, 1988). Although not symptomatic initially most (if not all) scaphoid nonunions progress to produce a painful wrist with impaired function, clinically significant loss of motion, increased weakness and degenerative arthritis (Daly and Gill, 1996). (Ruly and Stinson 1985).

The objective of treatment non-united scaphoid are to decrease carpal instability by realigning and lengthening the foreshortened scaphoid and maintaining the re-

duction by internal fixation and bone graft technique (Freedman et al, 2001). Fernandes (1990), reported that cancellous inlay graft must be considered the treatment of choice for stable scaphoid nonunion.

Displaced scaphoid nonunions are more difficult to treat which requires specific treatment directed at fracture reduction, bone apposition, internal fixation and bone graft technique. The aim of this study is to evaluate the results of treatment of ununited fractures of the scaphoid by iliac bone graft and Kirschner wire fixation.

### **Patients and Methods**

This prospective study included sixteen patients with nonunited fracture scaphoid treated at Mansoura University hospital. The patients average age was 27.6 years, with a range of twenty to fifty five years. Fifteen were males and only one female. The dominant wrist was involved in 10 cases, and the non dominant wrist was involved in 6 cases. The mean delay from the recalled time of injury to start of management was 27.18 months with range from 3 to 60 months.

Any case with severe osteoarthritis, avascular necrosis, associated with wrist injuries or carpal instability was excluded.

A history was taken covering details of initial injury and treatment, current problem and functional level of activity. All patients were evaluated clinically using wrightingon Hospital wrist scoring system (Mass, 2001) with regards to pain, function, wrist motion and grip strength (table 1).

**Wrist motion:**

For measurement purpose, wrist motion was documented in four directions: flexion, extension, radial deviation and ulnar deviation.

Wrist range of motion was evaluated with the elbow flexed to 90o and the forearm pronated. (Smith and Cooney, 1989).

**Gripe strength test:**

Gripe strength measurement performed for every patient using a sphygmomanometer. The cuff was inflated up to 20mm Hg and the patient was asked to squeeze it as hard as he can. A reading of

200 mm Hg or over should be achievable with normal hand compared with the other hand. (Babozkurt and Gur, 2001).

**Radiological evaluation:**

Plain x-ray including PA with 10 angulations of the table, dead lateral and PA with ulnar deviation was done for all patients to verify our clinical diagnosis.

All patients were subjected to surgical treatment in the form of iliac bone graft and kirs-chener wire fixation according to stark and Richard technique (1988).

**Operative technique:**

Under general anesthesia, a pneumatic tourniquet was applied on the arm. The patient lies supine with the upper limb abducted and supinated on a side table. The limb was prepared and draped.

A vertical skin incision measuring 2-3 cm on the volar aspect of the wrist was made starting from the scaphoid tubercle distally and extended proximally between the tendon of the flexor carpi radialis muscle and the radial artery. Deep fascia was incised

in line with the skin incision. The radial artery was identified and retracted with the lateral skin flap to the lateral side. On the other hand, tendon of the flexor carpi radialis muscle was identified and freed from its tunnel in the flexor retinaculum. Its tendon sheath was incised and the tendon was retracted medially to expose the volar aspect of the radial side of the wrist joint. The capsule of the wrist joint over the scaphoid was incised longitudinal to expose the scaphoid bone.

Both parts of the scaphoid as well as the articular surface of the radius can be seen readily. A small, rectangular window of bone was removed from the volar aspect of the distal fragment immediately adjacent to the fracture. Through this opening, both fragments were cleared of fibrous tissue and dead bone, using a low-speed power burr or curette.

A large cavity was fashioned in both the proximal and distal parts of the scaphoid. The volar of the cortex of the scaphoid was often deficient, and this deficiency permits an exaggerated volar tilt of

the distal fragment. Realignment, reduction of the fracture, and restoration of the bone to the proper length were done. The scaphoid was transfixed with two kirschner wires sized 0.5-1 mm, which were inserted through the distal fragment into the proximal one. Correct placement of the wires was ensured by observing them through the volar window.

Cancellous bone from the ileum was packed into the cavity and cortical bone graft fashioned to fit into the volar window, and then the wires be inserted through the graft to the proximal part of the scaphoid. Scaphoid reduction, alignment and position of the wires were checked with image intensifier.

The Kirschener wires were cut off beneath the skin. The capsule was approximated with absorbable sutures, the skin was closed by absorbable subcuticular suture and the extremity was immobilized in thumb-spica plaster splint.

With postoperative elevation of the limb, allow free range of mo-

tion of the fingers and postoperative x-ray was done. Patient was discharged from the hospital one or two days after surgery.

**Postoperative follow-up:**

All patients were followed monthly for nine months. In the first three months, the patients were subjected to anteroposterior and lateral view x-rays monthly without removing the cast to observe the advance of union and position of the wires.

In the second three months, the cast was removed and patients allowed to do light exercises to re-gain the range of motion of the wrist when the union was observed. X-ray was done monthly. At the end of this period, the Kirschner wires were removed usually under local anesthesia after the fracture had united.

In the last three months, the patients were allowed to do their original wrist function and motion, and final assessment was done according to the same score at the end of this period.

**Results**

**Overall final results:**

**A) clinical:** According to wrist hospital scoring system (Mass, 2001), thirteen patients (81.25%) had excellent results, two patients (12.5%) had good results, one patients (6.25%) had poor result and no patients had fair results.

**B) Radiological:** only one fracture (6.25%) was non united, otherwise all other Fractures (93.75%) united.

**Postoperative clinical results:**

**1- Pain**

Postoperative, seven cases (43.75%) had no pain, eight cases (50%) had occasional pain and one case (6.25%) still had severe pain and serious limitation of activities. Improvement in wrist pain after surgery is shown in (table 2).

**2- wrist motion**

The mean postoperative range of dorsiflexion, palmar flexion, ulnar deviation and radial deviation of affected hand was 53.65, 57.18°, 33.75°, 15.370 respectively compared to 64.75°, 72.06°,

**Table 1 : Wrist Hospital Wrist Scoring System.**

<b>Subjective Parameters</b>	
<b>Pain</b>	
Excellent:	Negligible or no pain.
Good:	Occasional pain & /or no compromise in activities & /or mild discomfort with strenuous use.
Fair:	Moderate pain, tolerable but some limitation of activities.
Poor:	Sever pain &/or serious limitation of activities (VAS < 4).
<b>Function</b>	
Excellent:	Back to preinjury activity level.
Good:	Back to usual sports I activities with some limitations or discomfort.
Fair:	Can perform activities of daily living (ADL) but can not return to high demand wrist activities.
Poor:	Can perform ADL with some limitation / discomfort.
<b>Motion</b>	
Excellent:	Equal to the opposite side
Good:	Less movements than the opposite side but more than functional range of movements (FRM)'. FRMonly.
Fair:	FRMonly.
Poor:	Stiff and less than FRM,
<b>Objective Measurements</b>	
<b>Grip strength</b>	
Excellent:	D** > 90% of the opposite side. ND***: > 75% of opposite side.
Good:	D: 76% to 89% of the opposite side. ND: 51% to 75% of the opposite side.
Fair:	D: 51% to 75% of the opposite side. ND: 25% to 50% of the opposite side.-
Poor:	D: < % of the opposite side. ND: < 25% of the opposite side
<b>Subjective rating (Total subjective scores)</b>	
15-35	Dissatisfied (DS)
36-55	Partially satisfied (PS)
55-80	Very satisfied (VS)
<b>Overall rating (Total o(subjective and objective scores)</b>	
20 – 40	Poor (P)
41 – 60	Fair (F)
61 – 80	Good (G)
81 – 100	Excellent (E)

FRM: 5 of flexion, 30 of extension, 10 of radial deviation, 15 of ulnar deviation. D: Dominant side.



39.43, 18.25° of dorsiflexion, palmar flexion, ulnar deviation and radial deviation respectively of the non affected hand. Yet, the difference was still statistically significant ( $P < 0.001$ ). Improvement in wrist motion after surgery is shown in (table 3).

### 3- Hand Grip Strength:

The mean postoperative grip strength of the affected hand was 203.12 mm Hg compared to 233 mm Hg of the non affected hand.

The difference was statically significant ( $P < 0.01$ ). Improvement in grip strength after surgery is shown in (table 4).

### Postoperative radiological results:

At the end of the follow up period which was 9 months fifteen patients (93.75%) achieved sound union in a time ranged from 16-28 weeks with mean of 20 weeks and only one case (6.25%) had failed to unite.

**Table (2):** Improvement in wrist pain after surgery.

Pain	Preoperative	Postoperative
Fair (V.A.S 4-5.9) &	11	1
Poor (V.A.S < 4)	(68.75%)	(6.25%)
Excellent (V.A.S 9-10) &	5	15
Good (V.A.S 6-8.9)	(31.25%)	(93.75%)
Total	16 (100%)	100%

$P = 0.0003$

**Table (3) :** Improvement in wrist motion after surgery.

Wrist motion	Preoperative (Mean)	Postoperative (Mean)
Dorsiflexion	39.56	53.56
Palmer flexion	39.93	57.18
Ulnar deviation	23.43	33.75
Radial deviation	10.31	15.37

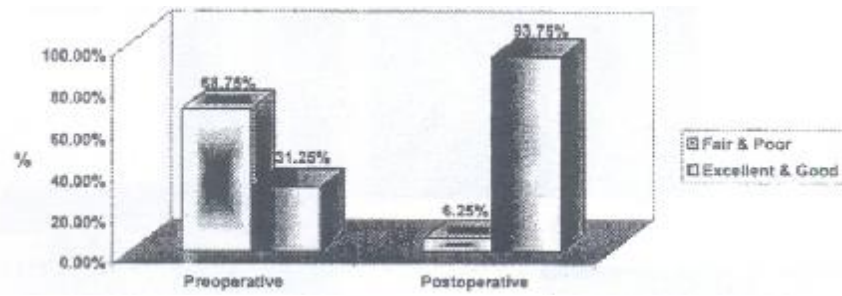
$P = 0.001$

**Table (4):** Improvement in Grip Strength after surgery.

	Preoperative Mean	Postoperative Mean
Grip strength	109.68	203.12

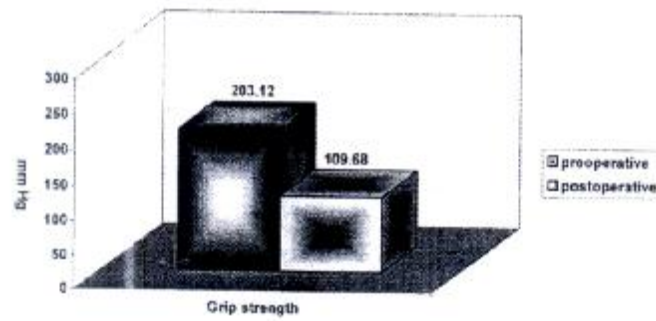
$P = 0.001$

M<sub>0</sub>



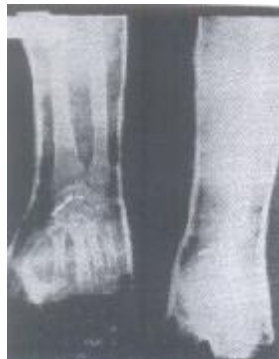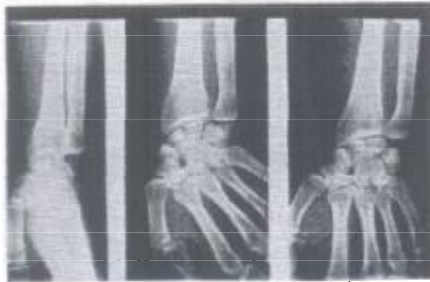
**Chart (1):** Preoperative versus postoperative pain distribution.

**Chart (2):** Preoperative versus postoperative wrist motion ranges in the affected hand.

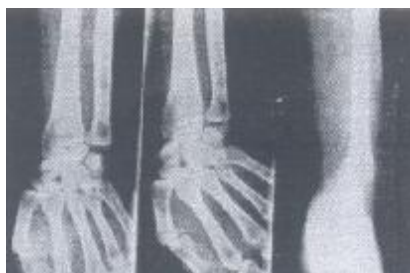

**Chart (3):** Preoperative versus postoperative grip strength ranges in affected hand.

**Case I :** male patient, 22 year, time since injury 22 months.

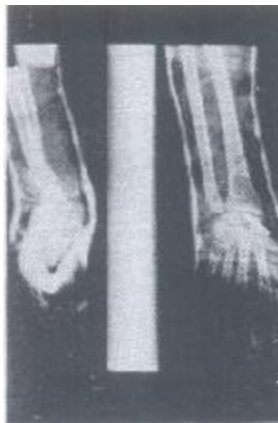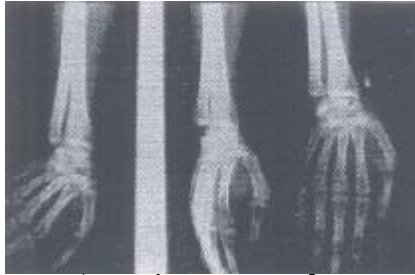


B) Immediate postoperative x-ray.

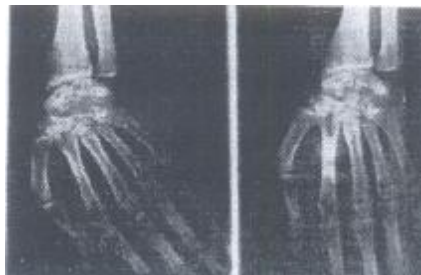


C) Final Postoperative x-ray (Excellent result, score 100).

**Case II** : male patient, 32 year, time since injury 32 months.

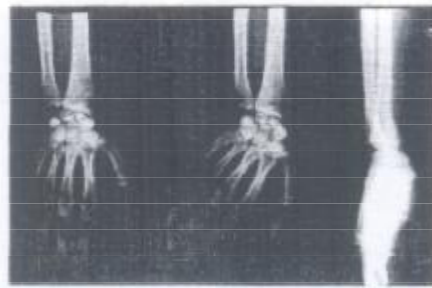


B) Immediate postoperative x-ray.

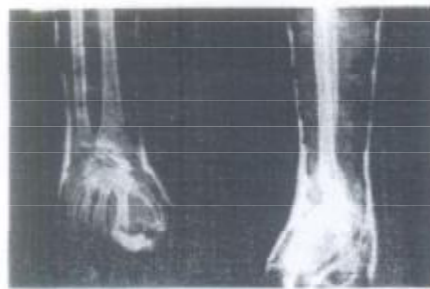


C) Final Postoperative x-ray (Excellent result, score 90).

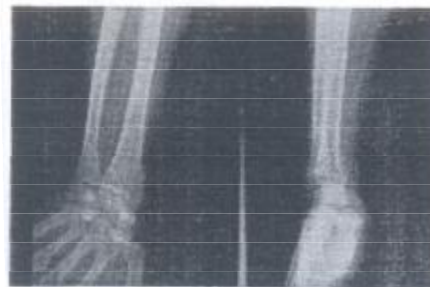**Case III:** male patient, 25 year, time since injury 30 months



A) Preoperative X-ray



B) Immediate postoperative x-ray.



C) Final Postoperative x-ray (Excellent result, score 90).

### Discussion

The scaphoid serves as a mechanical tie-rod connecting the proximal and distal carpal rows and maintains carpal length while transmitting the driving force for wrist motion from the distal row to the intercalated proximal row (Smith and Cooney, 1989).

Scaphoid fracture is a challenge for hand surgeons. There is a risk of delayed healing or nonunion not only because of the compromised blood supply, but also, because of the persistent forces applied to the scaphoid as a result of its critical position between the proximal and distal carpal rows (Toby et al, 1997).

The scaphoid bone is primarily an intra-articular bone, which implies that fracture healing can only occur via endosteal vessels. The disruption of which by bony fracture may produce avascular necrosis and prolonged fracture healing and it is seen more often with proximal scaphoid injuries (Mathoulin and Haerly, 1998).

Failure to recognize the original injury, inappropriate or incom-

plete treatment and inadequate methods to assess fracture union also add to the difficulty in management of scaphoid fractures. (Cooney et al, 1988).

Most nonunions progress to produce a painful wrist with impaired function, clinically significant loss of motion, increased weakness and degenerative arthritis. (Fernandez 1990).

The ideal treatment of scaphoid nonunion remains obscure and controversial. Treatment for scaphoid nonunion should aim not only to heal the osseous defect but also:

- (1) To decrease carpal instability by realigning and lengthening of foreshortened scaphoid and
- (2) To maintain the reduction by internal fixation and bone graft technique. (Film and Herbert, 1996).

Internal fixation of the scaphoid is a difficult task regarding its small size, unique geometry and predominance of articular surface area.

Internal fixation without bone graft has been used for scaphoid nonunion but reported union rate varies from 0 to 80%. (Frenandez, 1990). Maudsley and Chen, 1972, reported low union rate of 32.3% only with screw fixation alone. Leyshon and his colleagues 1984, reported that 80% of their patients healed following internal fixation with A-O scaphoid lag screw.

#### **Bone grafting**

Bone grafting has been the most popular surgical treatment and remains the procedure of choice for scaphoid nonunion.

Russe 1960, described technique of inlay graft using a volar approach in which corticocancellous graft was set in a cavity made in proximal and distal fragments to serve as osteogenic material and stabilize the fracture. Russe reported 90% bony union after an average of 4.6 month. Stark and his colleagues., (1987), reported 81 % union rate using Russe technique.

#### **Bone grafting and internal fixation:**

In view of the fact that inlay

grafting procedure of Russe provides a high union rate in stable scaphoid nonunion, its indication should be carefully weighted against interpositional bone grafting and internal fixation, which is the current method of treatment for unstable nonunion with flexion deformity and associated carpal instability.

Linscheid and his colleagues (1992), reported on six cases of palmar wedge grafting that used a similar technique in which a bicortical iliac graft was impacted between the fragments of the scaphoid. Internal fixation was done with Kirschener wires.

Fixation with kirschner wire is easy to accomplish and add little to the operating time. Coony and Liensield (1988), demonstrated that there was a trend toward a greater rate of union when Kirschener wires were incorporated with bone grafting than when bone grafting was used alone.

In this series, we treated 16 patients with scaphoid nonunion by iliac bone graft and kirschener wire fixation. Follow up period was

nine months. Fifteen patients (93.75%) had union at an average time of 20 weeks (range 16-28 weeks), while one case failed to achieve union. Stark et al., (1988), reported union rate of 128 patients (97%) in an average of 17 weeks with range 8-33 weeks using iliac bone graft and Kirschener wire fixation.

In this series, seven cases (43.75%) had no pain, and eight cases (50%) had occasional pain. In Stark's series, 98 patients (67.34%) had no pain, and 34 patients (23.12%) had occasional pain.

In this series, the average wrist movement postoperative was dorsiflexion (53°), palmar flexion (57°). The average postoperative loss of grip strength was 13%, and postoperative impairment of function was 17%. Basbozkurt (2001) reported 58° of postoperative dorsiflexion, 53° of palmar flexion, postoperative loss grip strength of 15% and postoperative impairment of function of 21%.

We supplemented the wire fixation by a cast average duration of

about fourteen weeks with minimum duration of twelve weeks and maximum duration of twenty weeks. Coony et al., reported an average duration of immobilization of seventeen weeks after treatment with bone grafting with or without Kirschener wires. Stark et al., reported an average of seventeen weeks (maximum 33 weeks) of immobilization after bone grafting and insertion of Kirschener wires.

In this series, there was statistically significant delay in the union time when the sclerosis was affecting the proximal fragment. This fact was established by Cooney et al., (1980) as they reported that osteosynthesis of proximal third nonunion take longer to heal and may be technically difficult to perform and grafted nonunion of the proximal third of the scaphoid take longer to heal than grafted nonunion of the middle or distal thirds, this is probably due to the fact that a small proximal fragment is more likely to be avascular and is more difficult to stabilize.

Internal fixation using Herbert screw results in rapid symptomat



is relief and functional recovery. The screw provides sufficient stability to allow normal use of the wrist. Also screw fixation provide more rigid fixation than Kirschner wire. The main disadvantage of Herbert screw fixation is its technical difficulty that requires skill and practice. If the screw direction is inappropriate it can damage the articular cartilage. Some scaphoids particularly in female patients are too small for the successful application of the jig. (Herbert and Filam, 1996).

The treatment of non-united scaphoid fracture, which is complicated by avascular necrosis of the proximal fragment, remains a challenge. The unfavorable results reported by a number of investigators, who have used conventional autogenous nonvascularized bone grafting procedures made some authors recommend other operations as excision of the proximal fragment, replacement with a prosthesis, allograft, as well as salvage procedures such as resection arthroplasty, partial or total arthrodesis of the wrist.

## Conclusions

### Our conclusions from this study include the following:

- i- Iliac bone graft and Kirschner wire fixation is an effective procedure for management of scaphoid non union as it gives a high rate of union in reasonable time.
- ii- This procedure is simple, economic, Kirschner wire fixation does not add much to the operative time and does not need special equipments.
- iii- There are marked improvements in pain, wrist motion, wrist function and handgrip strength with this method of treatment.
- iv- Time of delay since injury until the operation does not affect union rate.
- v- This type of fixation does not need a second operation for removal of wires after union as this can be done in out patients clinic under local anesthesia.

So, we recommend the use of this method in treatment of sca-

phoid fracture non-union with careful selection of indicated cases and precise surgical procedure.

### References

**Roolker W., Tiel-van M. M., Bossuyt P., et al., (1996)** : Carpal box radiography in suspected scaphoid fracture. J. Bone and Joint surgery (Br) 78-B-535-539.

**Cooney W. P., Linscheid R. L., et al., (1988)** : Scaphoid non-union, role of anterior interposition bone graft. J. Hand Surgery Vol. 13 A. No. 5-635-649.

**Stark H. H., Richard T. A., et al., (1988)** : Treatment of ununited fractures of the scaphoid by iliac bone graft and Kirschner wire fixation. J. Bone and joint surgery Aug. 70A: 982-991.

**Szabo R. M. and Manske D. (1988)** : Displaced fractures of the scaphoid. Clinical orthopedic and related research May No. 230:30-38.

**Daly K., Gill P., et al., (1996)** : Established nonunion of the scaphoid treated by volar wedge grafting and Herbert screw fixation. J.

Bone and Joint sur-gery (Br) 78B: 530-534.

**Ruby L. K., Stinson J., et al., (1985)** : The natural history of scaphoid nonunion. J. Bone and Joint surgery March Vol. 67A, No. 3:428-432.

**Freedman D. M., Botte M. J. and Gelberman R. H. (2001)** : Vascularity of the carpus. Clinical orthopaedics, February No. 388 P. 47-59.

**Mass D. P. (2001)** : Hand and Wrist in Reider B. editor; the orthopaedic physical examination; W.B. Saunders company, Philadelphia.

**Smith D. K., Cooney III W. P., et al., (1989)** : The effects of simulated unstable scaphoid fractures on carpal motion. J. Hand Surgery Marc Vol. 14 A, No. 2, Part 1 P 283-91.

**Toby E. B., Butler T. E., et al., (1997)** : A comparison of fixation screws for the scaphoid during application of cyclical bending loads. J. Bone and joint surgey August Vol. 79A, No. 8.

- Cooney W. P., Linscheid R. L., et al., (1988)** : Scaphoid non-union role of anterior interpositional bone grafts. J. Hand Surgery September Vol. 13 A. No. 5.
- Kim W. C., Shaffer J. W., et al., (1983)** : Failure of treatment of ununited fractures of the carpal scaphoid. J. Bone and Joint Surgery September Vol. 65 A, No 7.
- Fernandez D. L., (1990)** : Anterior bone grafting and conventional lag screw Fixation to treat scaphoid non-unions. J. Hand Surgery January Vol. 15 A. No.1.
- Maudsley R. H. and Chen S. C. (1972)** : Screw fixation in the management of the fractured carpal scaphoid. J. Bone and Joint Surgery 54 B: 432-477.
- Filam S. L. and Herbert T. J. (1996)** : Herbert screw fixation of scaphoid fractures J. Bone and Joint Surgery July Vol. 78B, No 4.
- Fisk G. R. (1994)** : Non-union of the carpal scaphoid treatment by wedge grafting. In proceedings of the British orthopaedic association. J. Bone and Joint Surgery 66 B Vol. 2: 277.
- Russe O. (1960)** : Fracture of the carpal navicular. Diagnosis, non - operative treatment, and operative treatment. J. Bone and Joint Surgery 42A: 759 - 768.
- Green D. P. (1985)** : The effect of avascular necrosis on Russe bone grafting for scaphoid nonunion. J. Hand Surgery 10 A: 597-605.
- Leyshon A., Ireland J. and Trickey E. L. (1984)** : The treatment of delayed union and non-union of the carpal scaphoid by screw fixation. J. Bone and Joint Surgery, 66B: 124-127.

REPRINT

# **BENHA MEDICAL JOURNAL**

**RESULTS OF TREATMENT OF  
UNUNITED FRACTURES OF SCAPHOID  
BONE BY ILIAC BONE GRAFT AND  
KIRSCHENER WIRE FIXATION**

**Mohamed Abd El-Wahab MD**

**Published by  
Benha Faculty of Medicine**

*Volume 26 Number 3  
Sept. 2009*

---

---

## LEVEL OF SENSORINEURAL HEARING LOSS AMONG CHILDREN

**Khayria A. Al-Abduljawad, Ph.D.**

*College of Applied Medical Sciences, King Saud University, KSA*

### **Abstract**

*Hearing loss in children, especially the very young is a health problem that leads to hearing handicapness and inability to acquire speech. In older children it leads to backwardness and poor academic performance in classroom. One thousand one hundred and forty (1140) children in a primary school , aged 6-12 years (50% girls) and (50% boys), were investigated. Medical history was obtained and otoscopic examination was carried out. Pure tone audiometry and tympanometry were used to detect hearing loss (HL) greater than 20 decibels (dB) HL in the frequency 500 hertz (Hz), 1000Hz 2000Hz and 4000Hz. The objective of this study was to screen children for hearing impairment and its etiology and comparing the result between children. Results indicate high prevalence of hearing loss found in this population. Conductive hearing loss was significant high in the boys comparing to the girls in this study. Hearing impairment was found in 41 children giving prevalence rate of (3.6 %). 9 children out of the 41 had sensorineural hearing loss and mixed hearing loss, with a prevalence rate of (.79 %) of the total surveyed. Consanguinity of parents of the children was found to be 19% first cousins and 22% second cousins.*

**Key words:** *Sensorineural , Hearing impairment, , Otoloscope, Audiometer Tympanometry.*

### **Introduction**

The prevention of hearing impairment can be very effective, but it needs to be clear in scope, strategy and implementation. This study examined the aetiology of sensorineural hearing loss which is defined as "a permanent hear-

ing threshold shift of >20 decibels (dB) or more, at 500, 1000, 2000 or 4000 hertz (Hz) due to a defect in the cochlea or the auditory nerve whereby nervous impulses from the cochlea to the brain are attenuated" (Alexander Graham Bell 20007, Occupational Safety

and Health 1991). Sensorineural hearing loss (SNHL) in children, especially the very young is a health problem with immense psychosocial and economic impact. A mixed hearing loss is the result of damage to both conductive pathways of the middle ear and to the nerves or sensory hair cells of the inner ear. Conductive hearing loss, which is defined as "hearing loss due to a disorder of the pinna, external ear canal, the tympanic membrane, the ossicles or their attachments, including the oval and round windows" (Davidson et al 1988). The study of epidemiology of childhood hearing impairment is essential for the planning of preventive and rehabilitative services including appropriate audiological care. A previous study of the Saudi population from the four main provinces of the country showed the prevalence of SNHL to be 1.5% (Al-Abduljawad and Zakzouk, 2003).

### **Materials and Methods**

A sample of 1140 children in a primary school, aged 6-12 years 50% girls and 50% boys, have been screened from 2005 - 2008. Each child was assigned a code

number and a questionnaire was filled with the help of a social worker who obtained information about the child health, vaccination or any problem relating to ear or hearing from the parents.

Clinical examinations of the ear by otoscope were performed. Children with wax or foreign bodies in their ears underwent an ear cleaning to remove the wax before screening, and those with active discharge were excluded. Tympanometry using Grason Stadler Incorporation (GSI 33) was performed. The tympanograms were divided into type A (0-99 mm H<sub>2</sub>O pressure), type C1 (-100 to -199 mm H<sub>2</sub>O), type C2 (-200 to -350 mm H<sub>2</sub>O), and type B (flat curve without an impedance minimum). Tympanograms were performed on all children except those with acute or chronic suppurative otitis media. Pure tone examination of children was carried out using an screening audiometer (Madsen 118). The degree of hearing loss is generally expressed as an average in decibels Hearing Loss (dBHL). It is classified into 6 categories. Slight (16-25dBHL), mild (26-40 dBHL), moderate (41-55 dBHL),

moderately severe (56-70 dBHL), severe (71-90) and profound (90+ dBHL) (Gelfand, 1977) .

A questionnaire modified from (World Health organization PD/HI 1993) was used which include the name, age, birth weight, sex, parental relationship, family history of deafness, complaints of hearing and speech problems- and immunization history.

The main objective was to screen these children for hearing impairment and its etiology especially sensorineural hearing loss type.

### **Results**

The number of children surveyed was 1140. The age range between 6 to 12 years. 570 were boys (50 %) and 570 were girls (50%) Table (1). Hearing impairment was found in 41 children giving prevalence rate of (3.596%) 3 of these had sensorineural hear-

ing loss, with a prevalence rate of (0.263 %) of the total surveyed, 6 (0. 526%), with mixed hearing loss and 32 (2.81 %) with conductive hearing loss due to otitis media.

This study indicates that high prevalence of middle-ear pathology is found 57 (10 %) in young boys children while in young girls was 39 (6.82 %) Table (2).

In this paper we report children with SNHL in this survey where mixed hearing loss were counted because its result by damage to both conductive pathways of the middle ear and to the nerves or sensory hair cells of the inner ear. Three of the children with SNHL of mild to moderate type (>40dB loss), the rest suffered MHL diseases. The various causes of SNHL are shown in (Table 3). Consanguinity of parents of the children was found to be 19% first cousins and 22% second cousins.

**Table 1 :** Details of subjects with respect to Type and degree (N= 570 girls and 570 boys) (prevalence rate of hearing impairment was found in 41 children).

Type and degree of HL	N. of girls	Proportional prevalence %	Overall Prevalence %	N. of boys	Proportional prevalence %	Overall Prevalence %	Overall Prevalence % girls/ boys
Cond. HL Mild	570	12	2.11	570	20	3.50877	2.81
Mixed mild to mod. HL	570	2	0.351	570	4	0.70175	0.525
Mild to mod. SNHL	570	1	0.175	570	2	0.35	0.263
Total	570	15	2.46*	570	26	4.5614*	3.599

**Table 2 :** Details of subjects with respect to age category of middle-ear pathology for three groups' percentage (N= 570 girls and 570 boys).

Age of children	Total N. of Girls	Proportional prevalence %	Overall Prevalence %	Total N. of Boys	Proportional prevalence %	Overall Prevalence %
6 -8 years	190	24	12.6315	190	31	16.315789
8 -10 years	190	11	5.78	190	17	8.947368
10 -12 years	190	4	2.1	190	9	4.736842
total	570	39	6.84*	570	57	10*

**Table 3 :** Causes of SNHL among 1140 Saudi Children (N= 570 girls and 570 boys)(3+6=9 SNHL).

Cause	Number	Proportional Prevalence %	Overall Prevalence %
Consanguinity	2	22.22	0.175
Hyperbilirubinaemia	1	11.11	0.08
Prematurity + Low birth Weight (LBW)	2	22.22	0.175
Family history with hearing loss	2	22.22	0.175
Fever of unknown etiology	1	11.11	0.08
Unknown cause	1	11.11	0.08
Total	9	100%	0.766 %



### **Discussion**

Sensorineural hearing loss occurs when there is damage to the inner ear (cochlea) or to the nerve pathways from the inner ear (retrocochlear) to the brain. Sensorineural hearing loss cannot be medically or surgically corrected. It is a permanent loss that does not only involve a reduction in sound level, or ability to hear faint sounds, but also affect speech understanding, or ability to hear clearly (ASHA's Web site).

It is well recognized that hearing is critical to speech and language development, communication, and learning. The earlier hearing loss occurs in a child's life, the more serious the effects will be on the child's development. Similarly, the earlier the problem is identified and intervention begun, the less serious the ultimate impact will be. Hearing impairment in Saudi Arabia in Previous study was found in 13% of the children surveyed. 1.27% of the children had hearing impairment in the left ear and 2.26% in the right ear whereas 9.47% had hearing impairment in both ears. Sensorineural hearing loss (SNHL)

was found among 1.5% of all children surveyed (Al-Abduljawad and Zakzouk, 2003). This is high in our country compared to other developed countries.

One of the major causes of SNHL was found to be the hereditary factor. This could be attributed, in part at least, to consanguinity which increases the risk of transmission of both the autosomal recessive and the polygenetic (multifactorial) inheritance (Ferber-Viart et al., 1996). Perinatal factors such as prematurity and low birth weight are considered risk factors for hearing impairment (Darin et al., 1997).

This study was applied on children school (girls and boys) in Riyadh Saudi Arabia, age 6 - 12 years the result showed significant increasing children having Sensorineural hearing loss in boys was 6 (1.1%) whereas in girls was 3 (0.525%) and conductive hearing loss in boys was 57 (10%) and in girls 39 (6.84%). These findings agree with a longitudinal study in Sweden, 2325 children were hearing tested at age 7, 10 and 13 with screening audiometry. The screen-

ing level was 20 dB HL. Approximately 75% of the children passed the screening level at all ages. Hearing loss was more frequent in boys than in girls at age 13 (16%:9%). The left ear was more commonly affected than the right ear. High frequency dips increased for boys with age, but not for girls (Axelsson et al., 1987). Middle ear disease is common in Saudi children, studies show prevalence rates of otitis media with effusion (OME) was 7.5 % from a total of 9540 Saudi children (Zakzouk and Abduljawad, 2002) . In a study of the epidemiology of hearing impairment in childhood, (Davidson et al 1988) reviewed ten studies from fourteen countries and found a prevalence range of 0.56 to 2.3/1000 for hearing loss greater than 40dB bilaterally in the western world. They also reported that the prevalence for the less developed countries tends to be slightly higher, with figures between 2.0 and 4.2/1000.

One of the surveys carried out by researchers at the Center for Disease Control and Prevention in Atlanta, USA, estimated that 2 per cent of all children in the USA are

born with hearing loss and nearly 15 per cent of all children and young people between 6 and 19 years of age are suffering from temporary or permanent hearing loss for reasons ranging from illness to noise exposure. While the figures for European children who are suffering from hearing loss are expected to be at the same levels. In the UK, the Royal National Institute for Deaf People, RNID, estimates that about 25,000 British children aged 0 to 15 are 'deaf or hard of hearing'. Of these, 8,000 are severely or profoundly deaf (World Health Organization, 1993 and Marazita, 1993).

### **Conclusion**

Our findings indicate high prevalence of hearing loss found in this population. The study of hearing impairment in children is extremely important because it affects his or her ability to learn, socialize and communicate. It is also important to correct any hearing problem found and allow the children to progress in their academic development without delay or backwardness (Yoschinaga-Itano et al., 1998). We recommend early detection and treatment of chronic

otitis media. Centers are essential to effective audiological care appropriate progression training of personnel, better parent's education to increase public awareness and decreasing family intermarriage (consanguinity) is more practiced as a custom in Saudi Arabia.

### References

- Al-Abduljawad K. A. and Zakzouk S. M. (2003)** : The prevalence of Sensorineural hearing loss among Saudi children. International Federation of Otorhinolaryngological Societies (IFOS). International Congress Series 1240 : p.199-204.
- Alexander Graham Bell Association for the Deaf (2007)** : 3417 Volta Place NW, Washington, DC. ASHA's Web site : <http://www.asha.org/public/hearing/disorders/types.htm>.
- Axelsson A., Aniansson G. and Costa O. (1987)** : Hearing loss in school children. A longitudinal study of sensorineural hearing impairment. *Scand Audiol.*; 16(3):137-43.
- Darin M., Hanner P. and Thiringer K. (1997)** : Changes in prevalence, aetiology, age at detection and associated disabilities in preschool children with hearing impairment born in Goteborg. *Dev. Med. Child Neurol.*, 39 (12), 797-802.
- Davidson J., Hyde M. L. and Alberti P. W. (1988)** : Epidemiology of hearing impairment in childhood. *Scand Audiol.*; Suppl. 30:13-20.
- Ferber-Viart C., Morlet T., Maison S., Duclaux R., Putet G. and Dubreuio C. (1996)** : Type of initial brainstem auditory evoked potentials (BAEP) impairment and risk factors in premature infants. *Brain Dev.*, 18 (4),287-293.
- Gelfand S. A. (1997)** : Essentials of Audiology. 1st ed. New York, NY 10016.
- Marazita M. L. (1993)** : Genetic epidemiological studies of early-onset deafness in the U.S. school-age population. *American Journal of Medical Genetics.*; 46(5): 486-491.
- Occupational Safety and**

**Health (1991)** : Scientific American Medicine. CTM. Chapter VII. p. 18.

**World Health organization regional office for the eastern mediterranean (1993)** : January, 1993. EM / PED / 35- Page 12.

**Yoschinaga-Itano C., Sedey A.**

**L., Coulter D. K. and Mehl A. L. (1998)**: The language of early-and later-identified children with hearing loss. *Pediat*; 102: 1161-1171.

**Zakzouk S. M. and Abduljawad K. A. (2002)** : Point prevalence of type B tympanogram in Saudi children, *Saudi medical journal*. 2002 vol. 23 (6):708-710.

REPRINT

# BENHA MEDICAL JOURNAL

**LEVEL OF SENSORINEURAL  
HEARING LOSS AMONG  
CHILDREN**

**Khayria A. Al-Abduljawad Ph.D.**

**Published by  
Benha Faculty of Medicine**

*Volume 26 Number 3  
Sept. 2009*

## **EFFECT OF EPIDERMAL GROWTH FACTOR ON ADRENALINE INDUCED EFFECTS IN VARIOUS TISSUES IN VITRO**

**Fayza R. El Menabawy MD., Farida M. El-Bana MD\*,  
Soheir F. El-Bassiony MD, Hanaa A. Abd El-Moneim MD  
and Shereen M. S. El-Sherbeiny M.Sc.**

*Department of physiology and pharmacology\*,  
Faculty of medicine Mansoura University, Egypt*

### **Abstract**

*Acute and intense psychological stressors induce cell damage in several organs, including the heart and the liver. Catecholamines appear to be responsible for the effect of acute stress. It was observed that adrenaline, through 1-adrenergic receptors; stimulates the release of EGF to the blood stream. Because catecholamine concentration in plasma remains high during the stress experience and for some time afterwards, tissues are exposed to combined effects of both catecholamines and EGF. So, the present research was devoted to study the effect of EGF on adrenaline induced effects in liver, skeletal muscle and adipose tissue in vitro. Experiments were done on 48 male white New Zealand rabbits, they were classified into 8 groups each group consists of 6 experiments. The liver, diaphragm muscle and epididymal fat pads were excised and Glucose uptake, net glucose output from liver and glycerol release were measured. Results revealed insulin like action of EGF in glucose uptake and in spite of increasing glucose output from liver, EGF has an antagonizing effect to the adrenaline induced lipolytic and glycogenolytic effects. This interference with adrenaline was through beta signaling. So, EGF which is secreted in large amount in response to adrenaline stimulation may have a protective effect against adrenaline induced functional disturbances such as excessive hyperglycemia and lipolysis which ends in ketogenesis.*

### **Introduction**

Acute and intense psychological stressors induce cell damage in several organs, including the

heart and the liver. Catecholamines appear to be responsible for the effect of acute stress (Sánchez et al. 2007). The rise in circulating

catecholamines plays an important role in stimulating liver glucose output by direct and indirect actions through stimulation of glycogenolysis and gluconeogenesis (Grau et al. 1997).

Catecholamines through  $\alpha$  1-adrenergic receptors; stimulates the release of EGF from SMG in mice. Accordingly, EGF levels are elevated in plasma of stressed animals. Because catecholamine concentration in plasma remains high during the stress experience and for some time afterwards, tissues are exposed to combined effects of both catecholamines and EGF (Sgoifo et al. 1997). EGF may protect the heart against the harmful effects of epinephrine (Pareja et al. 2003). EGF has also been reported to protect kidney and gastrointestinal tract from ischemia reperfusion injury and injury caused by noxious agents (Caballero et al. 2001). The mechanism by which EGF exerted these effects is unclear.

In newborn rats, EGF stimulates proliferation and blocks differentiation of adipocyte precursors and decreases fat pad weight. However, in mature adipocytes

EGF has opposed effects to those in their precursors: it stimulates adipogenesis and Surgical removal of the major production site of EGF in mice [submandibular salivary glands] impaired adipose tissue weight gain (Hamm-Alvarez 2002). On the contrary, administration of EGF reduced fat mass in rats. It also decreases body weight in obese mice. It was noticed also that obese rodents have either reduced levels of EGF or EGF receptors (Tebar et al. 2000).

#### **Aim of the work**

So, the present research was devoted to study the effect of EGF on adrenaline induced effects in liver, skeletal muscle and adipose tissue in vitro.

#### **Materials and Methods**

Experiments were done on 48 Male white New Zealand rabbits of the same weight. All animals were sacrificed; and the liver, diaphragm muscle and epididymal fat pads were excised and each of them was incubated in kreb's ringer bicarbonate buffered solution. Glucose uptake, net glucose output from liver and glycerol release were measured.

The experiments were classified into 8 groups each group consists of 6 experiments:

**Group 1:** It represents the control group.

**Group 2:** To study the effect of adrenaline (10  $\mu$ M) on liver, diaphragm muscle and epididymal fat pads (Lorita et al. 2002).

**Group 3:** To study the effect of EGF (10 nM) on the tested tissues (Lorita et al. 2002).

**Group 4:** To study the effect of EGF (10 nM) and adrenaline (10  $\mu$ M) on the tested tissues.

**Group 5:** To study the effect of adrenaline (10  $\mu$ M) on the tested tissues with blocking its  $\alpha$ -receptors by phentolamine (100  $\mu$ M) (Horn et al. 2005).

**Group 6:** To study the effect of adrenaline (10  $\mu$ M) on the tested tissues with blocking its  $\beta$ -receptors by propranolol (100  $\mu$ M) (Horn et al., 2005).

**Group 7:** To study the effect of EGF (10 nM) with adrenaline (10  $\mu$ M) on the tested tissues with blocking its  $\alpha$ -receptors by phentolamine (100  $\mu$ M).

**Group 8:** To study the effect of (10 nM) EGF with adrenaline (10  $\mu$ M) on the tested tissues with blocking its  $\beta$ -receptors by propranolol (100  $\mu$ M).

**Procedure:** 3 ml of the incubation medium was gassed with carbogen for 5 minutes and placed in each dry and clean bottle and the weight of each was determined. Different tissues (epididymal fat, liver slices and muscle strips) were placed in the weighed bottles and reweighed to determine the weight of the tissues. For each set of experiments, incubation flask without added tissue is considered as control for changes in level of glucose and glycerol in the medium. Chemicals were added to the incubation medium according to the corresponding group.

The incubation flasks were gassed again with carbogen for 30 seconds each. Then they were shut off and placed for one hour in the metabolic shaker at 37°C with a shaking rate of 100 r.p.m. After incubation was off, the flasks were cooled and kept inverted while still closed to include the condensed vapour on the upper wall of the flasks into the medium. Then the solution was taken from medium for assay of glucose by using glucose enzymatic kit and glycerol by using EnzyChrom Glycerol Assay Kit.



### Statistical Analysis

Statistical analysis was done by using SPSS (statistical package for social science) program version 10, 1999. Student test was done to compare between each two groups. P-values were considered insignificant if they were higher than 0.05.

### Results

Table (1) and figure (1) show significant decrease in glucose uptake by epididymal fat and diaphragm muscle, extremely significant increase in net glucose output from liver ( $P < 0.001$ ). Also, significant increase in glycerol release from epididymal fat, diaphragm muscle and liver by adrenaline.

Table (2) and figure (2) show significant increase in glucose uptake by epididymal fat, diaphragm muscle and extremely significant increase in net glucose output by liver ( $P < 0.001$ ). Also, there is non significant change in glycerol release from all tested tissues by EGF.

When comparing effect of EGF with adrenaline, table (3) and fig-

ure (3) and by comparing effect of EGF on adrenaline induced effects with adrenaline group, table (4) and figure (4): results show extremely significant increase in glucose uptake by epididymal fat and diaphragm muscle ( $P < 0.001$ ). However, net glucose output from liver was extremely significantly decreased. Also, there is significant decrease in glycerol release by epididymal fat, diaphragm muscle and liver.

EGF combined with adrenaline and  $\alpha$  blocker (group 7) as compared with adrenaline and  $\alpha$  blocker (group 5), table (5) and figure (5) show significant increase in glucose uptake, significant decrease in net glucose output from liver and significant decrease in glycerol release from tested tissues. But by comparing effect of EGF combined with adrenaline and beta blocker (group 8) with adrenaline and beta blocker (group 6), table (6) and figure (6) show significant increase in glucose uptake and net glucose output from liver, however, non significant change in glycerol release is detected.

**Table 1 :** Effect of adrenaline (10 $\mu$ M) on glucose uptake [by epididymal fat, diaphragm muscle], on net glucose output from liver, and on glycerol release [from epididymal fat, diaphragm muscle and liver] in rabbit in vitro.

Group(n=6)	Glucose (mg/gm wet)		Uptake (mg/gm wet tissue/h)	net glucose output (mg/gm wet tissue/h)	Glycerol (mg/gm)	Release (mg/gm wet tissue/h)	
	Epididymal fat	Diaphragm muscle		liver	Epididymal fat	Diaphragm muscle	
Control (gp.1) mean $\pm$ SD	2.2 $\pm$ 0.4	2.3 $\pm$ 0.8	2.3 $\pm$ 0.8	2.3 $\pm$ 0.8	0.4 $\pm$ 0.1	0.8 $\pm$ 0.1	0.2 $\pm$ 0.02
Adrenaline(gp.2) mean $\pm$ SD	0.7 $\pm$ 0.3	0.6 $\pm$ 0.2	8.8 $\pm$ 0.5	8.8 $\pm$ 0.5	1.6 $\pm$ 0.6	2.01 $\pm$ 0.2	0.7 $\pm$ 0.07
P	<0.001	0.001	<0.001	<0.001	0.001	<0.001	<0.001

n: number of experiments in each group on any tissue  $\pm$ SD: standard deviation  
P: values were compared with the corresponding values in control group

**Table 2 :** Effect of Epidermal growth factor (EGF) (10nM) on glucose uptake [by epididymal fat, diaphragm muscle], on net glucose output from liver, and on glycerol release [from epididymal fat, diaphragm muscle and liver] in rabbit in vitro.

Group(n=6)	Glucose (mg/gm wet)		Uptake (mg/gm wet tissue/h)	net glucose output (mg/gm wet tissue/h)	Glycerol (mg/gm)	Release (mg/gm wet tissue/h)	
	Epididymal fat	Diaphragm muscle		liver	Epididymal fat	Diaphragm muscle	
Control(gp.1) mean $\pm$ SD	2.2 $\pm$ 0.4	2.3 $\pm$ 0.8	2.3 $\pm$ 0.8	2.3 $\pm$ 0.8	0.4 $\pm$ 0.1	0.8 $\pm$ 0.1	0.2 $\pm$ 0.02
EGF (gp.3) mean $\pm$ SD	4.4 $\pm$ 0.7	4.4 $\pm$ 0.7	5.1 $\pm$ 0.8	5.1 $\pm$ 0.8	0.3 $\pm$ 0.06	0.64 $\pm$ 0.1	0.2 $\pm$ 0.02
P	<0.001	0.001	<0.001	<0.001	NS	NS	NS

n: number of experiments in each group on any tissue  $\pm$ SD: standard deviation  
P: values were compared with the corresponding values in control group NS: non significant

**Table 3 :** Comparison between effect of EGF (10nM) and effect of adrenaline (10 $\mu$ M) on glucose uptake [by epididymal fat, diaphragm muscle], on net glucose output from liver, and on glycerol release [from epididymal fat, diaphragm muscle and liver] in rabbit in vitro.

Group(n=6)	Glucose (mg/gm wet)		Uptake (mg/gm wet tissue/h)	net glucose output (mg/gm wet tissue/h)	Glycerol (mg/gm)	Release (mg/gm wet tissue/h)	
	Epididymal fat	Diaphragm muscle		liver	Epididymal fat	Diaphragm muscle	
Adrenaline(gp.2) mean $\pm$ SD	0.7 $\pm$ 0.3	0.6 $\pm$ 0.2	8.8 $\pm$ 0.5	8.8 $\pm$ 0.5	1.6 $\pm$ 0.6	2.01 $\pm$ 0.2	0.7 $\pm$ 0.07
EGF (gp.3) mean $\pm$ SD	4.4 $\pm$ 0.7	4.4 $\pm$ 0.7	5.1 $\pm$ 0.8	5.1 $\pm$ 0.8	0.3 $\pm$ 0.06	0.64 $\pm$ 0.1	0.2 $\pm$ 0.02
P	<0.001	<0.001	<0.001	<0.001	<0.001	<0.001	<0.001

n: number of experiments in each group on any tissue  $\pm$ SD: standard deviation  
P: values were compared with the corresponding values in control group

**Table 4:** Comparison between effect of adrenaline (10µM) with EGF (10nM) and effect of adrenaline (10µM) on glucose uptake [by epididymal fat, diaphragm muscle], on net glucose output from liver, and on glycerol release [from epididymal fat, diaphragm muscle and liver] in rabbit in vitro.

Group(n=6)	Glucose Uptake (mg/gm wet tissue/h)		net glucose output (mg/gm wet tissue/h)	Glycerol Release (mg/gm wet tissue/h)		
	Epididymal fat	Diaphragm muscle		Epididymal fat	Diaphragm muscle	liver
Adrenaline(gp.2) mean ±SD	0.7 ±0.3	0.6 ±0.2	8.8 ±0.5	1.6 ±0.64	2.01 ±0.23	0.7 ±0.07
EGF&Adr. (gp.4) mean ±SD	2.5 ±0.5	2 ±0.5	3.2 ±0.4	0.6 ±0.1	0.9 ±0.08	0.3 ±0.04
P	<0.001	<0.001	<0.001	0.002	<0.001	<0.001

n: number of experiments in each group on any tissue ±SD: standard deviation  
P: values were compared with the corresponding values in control group

**Table 5 :** Comparison between effect of EGF (10nM) with adrenaline (10µM) and alpha blocker (Phentolamine) (100µM) and effect of adrenaline (10µM) with alpha blocker (Phentolamine) (100µM) on glucose uptake [by epididymal fat, diaphragm muscle], on net glucose output from liver, and on glycerol release [from epididymal fat, diaphragm muscle and liver] in rabbit in vitro.

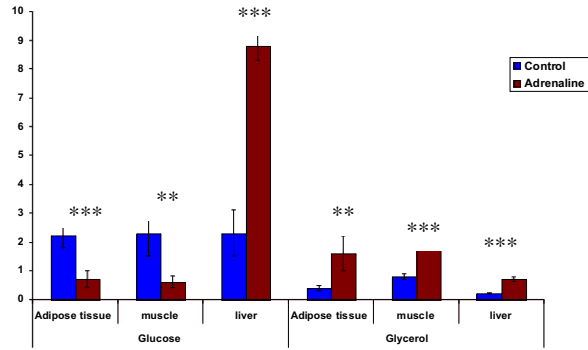
Group(n=6)	Glucose Uptake (mg/gm wet tissue/h)		net glucose output (mg/gm wet tissue/h)	Glycerol Release (mg/gm wet tissue/h)		
	Epididymal fat	Diaphragm muscle		Epididymal fat	Diaphragm muscle	liver
Adr. & µ Blocker (gp.5) mean ±SD	0.9 ±0.2	0.7 ±0.3	8.1 ±0.9	1.7 ±0.7	2 ±0.4	0.7 ±0.08
EGF & Adr. & µblocker (gp.7) mean ±SD	2.6 ±0.4	2.2 ±0.4	3.4 ±0.5	0.6 ±0.1	0.9 ±0.1	0.3 ±0.05
P	<0.001	<0.001	<0.001	0.003	<0.001	<0.001

n: number of experiments in each group on any tissue ±SD: standard deviation  
P: values were compared with the corresponding values in control group

**Table 6 :** Comparison between effect of EGF (10nM) with adrenaline (10µM) and Beta blocker (Propranolol) (100µM) and effect of adrenaline (10µM) with Beta blocker (Propranolol) (100µM) on glucose uptake [by epididymal fat, diaphragm muscle], on net glucose output from liver, and on glycerol release [from epididymal fat, diaphragm muscle and liver] in rabbit in vitro.

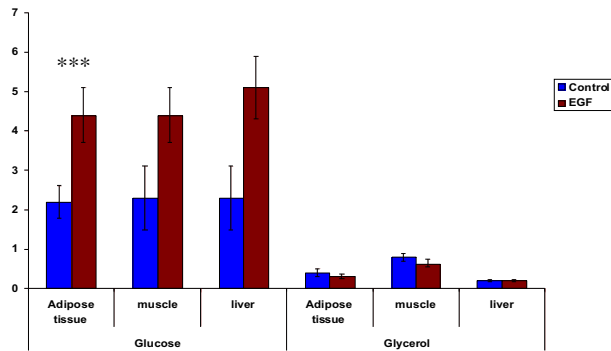
Group(n=6)	Glucose Uptake (mg/gm wet tissue/h)		net glucose output (mg/gm wet tissue/h)	Glycerol Release (mg/gm wet tissue/h)		
	Epididymal fat	Diaphragm muscle		Epididymal fat	Diaphragm muscle	liver
Adr. & µ Blocker (gp.6) mean ±SD	2 ±0.4	2.4 ±0.9	2.5 ±0.8	0.4 ±0.09	0.8 ±0.1	0.2 ±0.03
EGF & Adr. & µ Blocker (gp.8) mean ±SD	4.6 ±0.5	4.1 ±0.3	5 ±0.8	0.4 ±0.1	0.7 ±0.1	0.2 ±0.02
P	<0.001	0.001	<0.001	NS	NS	NS

n: number of experiments in each group on any tissue ±SD: standard deviation  
P: values were compared with the corresponding values in control group NS: non significant



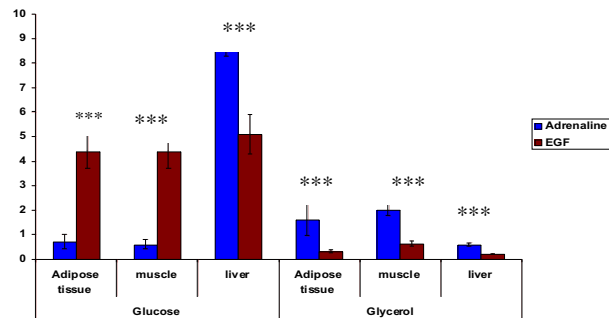
\*\*\* P<0.001 and \*\* P<0.01

Fig. 1 :



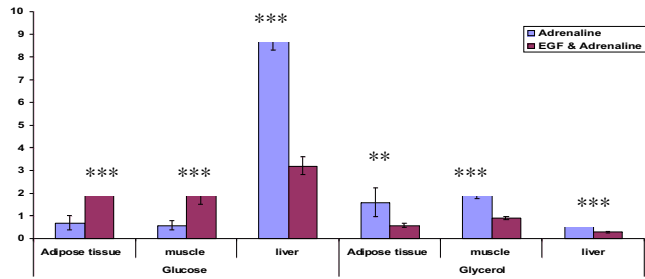
\*\*\* P<0.001 and \*\* P<0.1

Fig. 2 :



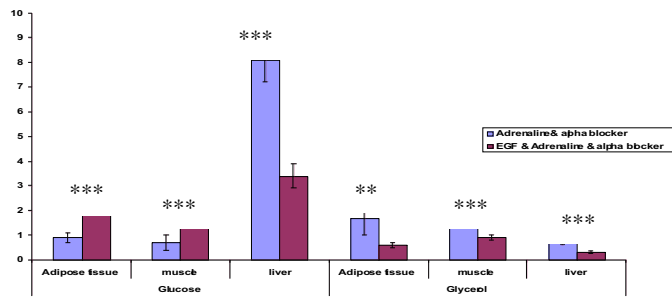
\*\*\* P<0.001

Fig. 3



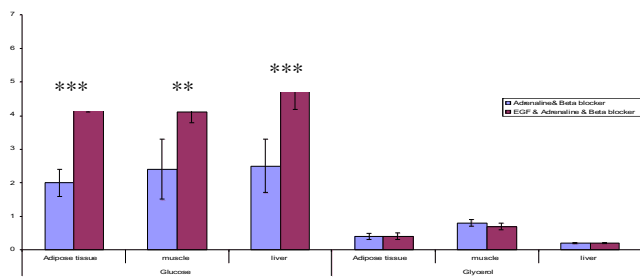
\*\*\* P<0.001 and \*\* P<0.01

Fig. 4



\*\*\* P<0.001 and \*\* P<0.01

Fig. 5



\*\*\* P<0.001 and \*\* P<0.01

Fig. 6

### Discussion

The present work (table & figure 1) showed extremely significant increase in net glucose output from liver after incubation with adrenaline in comparison with the control. This was markedly inhibited by beta blocker ( $P < 0.001$ ), but not significantly changed after alpha blocker. These results suggested that adrenaline acts on liver glucose output predominantly via beta receptors. This is in agreement with (Chu, et al. 2000) who found that the direct effect of adrenaline on hepatic glucose production was markedly inhibited by propranolol or butoxamine.

The direct hepatic effects of the catecholamines are attributable to their stimulation of glycogenolysis and indirect effects of the catecholamines on the liver relate to their gluconeogenic actions. Erraji-Benchekroun et al. (2005) proved that adrenaline stimulated hepatic glycogen degradation through both an alpha1-adrenergic mediated  $Ca^{2+}$  increase and a beta2-adrenergic-mediated cAMP increase, but mainly through beta receptors.

EGF results showed extremely significant increase in net glucose output by liver as compared with the control (table & figure 2). Thus, EGF stimulates glycogenolysis in liver. This agrees with Grau et al. (1997), who proved that adrenaline administration to anesthetized mice stimulated both the secretion of EGF and the degradation of glycogen in the liver. The EGF stimulation of glycogen degradation is mediated by the rise in cytosolic  $Ca^{2+}$  concentration (Zhou et al. 2005). Other studies report that EGF inhibits glycogen deposition in cultured hepatocytes and counteracts the glycogenic effect of insulin. EGF increases glycogen phosphorylase a in isolated hepatocytes (Jorissen et al. 2003). In addition to the effect on glycogen metabolism, it has been reported that EGF stimulates glycolysis and the pentose phosphate pathway in isolated hepatocytes (Erraji-Benchekroun et al. 2005).

Table & figure (3) showed also that the stimulatory effect of adrenaline on net glucose output was greater than that of EGF. Phosphorylase kinase is sensitive

to cAMP and Ca<sup>2+</sup>. Because EGF increased Ca<sup>2+</sup> but not cAMP, and adrenaline increased both messengers, it is understandable that the effect of EGF on phosphorylase kinase, and hence on the increase in phosphorylase activity, was lower when the cells were exposed to EGF than when exposed to adrenaline (Grau et al. 1997).

Table & figure (4) revealed that EGF significantly decreased the stimulating effect of adrenaline on net glucose output by the liver. In addition, EGF significantly decreased the beta effect of adrenaline on liver (table & figure 5). But, EGF significantly increased alpha effect of adrenaline (table & figure 6). Since beta effect of adrenaline predominates, EGF antagonizes adrenaline effect mainly by interference with beta signalling. Results of the present work agree with Sanchez et al. (2007) who suggested that the basis of the interaction between adrenaline and EGF in glycogen metabolism is the ability of EGF to interfere with the rise of cAMP induced by adrenaline. Because EGF also interfered with the cAMP signal prompted by

glucagon or forskolin, it can be concluded that this effect is not the consequence of any direct action of the EGF-signaling system on  $\beta$ -adrenergic receptors. Rather, it seems to be the consequence of an action on some phosphodiesterase, because the effect of EGF on cAMP was blocked by 3-isobutyl-1-methylxanthine.

The present results showed significant decrease in glucose uptake by epididymal fat and diaphragm muscle after incubation with adrenaline in comparison with the control (table & figure 1). This is mediated by beta receptors not alpha receptors, as proved by non significant change in glucose uptake on incubation with adrenaline and alpha blocker compared with adrenaline group, but there was significant increase in uptake in adrenaline combined with beta blocker as compared with adrenaline group ( $P < 0.001$ ).

Glucose disposal is reduced because of inhibition of glucose phosphorylation by elevated glucose 6-phosphate (G-6-P), secondary to greater flux through glycogenolysis (Wadley et al.

2006). Another possibility is that adrenaline directly affects GLUT4-mediated glucose transport across the sarcolemma, although this is equivocal. GLUT4 is phosphorylated via  $\beta$ -adrenergic pathways, and this may inhibit GLUT4 transporter activity, as demonstrated in rat adipocytes and skeletal muscle with adrenaline administration (Kreisman et al. 2003).

The present work also showed significant increase in glucose uptake by epididymal fat and diaphragm muscle after incubation with EGF in comparison with the control (table & figure 2). This is in agreement with (Yuasa et al. 2004) results which reported that epidermal growth factor (EGF) as well as insulin facilitates GLUT4 translocation and consequently glucose uptake through the activation of phosphatidylinositol PI 3-kinase and a serine-threonine protein kinase Akt in cultured cells. However, several investigators have reported opposite results (Yaoi et al. 2006).

By studying the effect of EGF on adrenaline decline of glucose

uptake in muscle and adipose tissue (table & figure4), the results revealed that EGF antagonized this effect significantly through beta signalling but increased the alpha effect. This is in agreement with Yuasa et al. (2004) who found that EGF stimulates non-IRS-associated PI3K which stimulates Akt-1 and leads to production of PI-3,4,5-trisphosphate which augments alpha signaling and also, it interferes with the rise of cAMP induced by adrenaline.

The present study revealed that adrenaline causes significant increase in lipolysis as indicated by increase in the level of glycerol release from liver, diaphragm muscle and adipose tissue as compared with the control group (table & figure1). Also, results showed that the lipolytic effect of adrenaline was through beta signalling due to the significant decrease ( $P < 0.001$ ) in glycerol release after incubation with combined beta blocker and adrenaline, also, non significant change in adrenaline lipolytic effect after incubation with alpha blocker as compared with adrenaline group.



Regarding adipose tissue lipolysis, it is likely that adrenaline increased cyclic AMP, resulting in activation of protein kinase A (PKA) and phosphorylation of HSL resulting in the hydrolysis of stored triacylglycerol to monoacylglycerol and FFA (Duncan et al. 2007). There is also the possibility that HSL activity was increased by ERK (extracellular regulated kinase) activity. Activation of the ERK pathway in adipocytes phosphorylates HSL and increases its activity; this is consistent with a cyclic AMP-dependent mechanism observed in adipocytes. Also, ERK1/2 phosphorylation was increased concomitantly with HSL activity during adrenaline infusion in skeletal muscle at rest. Besides these lipolytic agents elicit lipolysis in fat cells by stimulating HSL translocation from the cytosol to the lipid droplets in fat cells as a result of cAMP-protein kinase phosphorylation which causes a conformational change (Kumon et al. 2008).

Regarding hepatic lipolysis, in addition to adrenaline effect on hepatic lipases and increasing FFA release by stimulating beta

adrenoceptors, Van Heeswijk et al. (2005) demonstrated that Hepatic glycerol kinase is inhibited by both ADP and AMP. The physiological significance of these inhibitions may be the regulation of glycerol kinase activity in concert with the regulation of gluconeogenesis by adrenaline release in stress on the liver. The most important function of plasma glycerol is to provide precursor for glucose formation in these tissues.

In the present search, although there was non significant change in lipolysis after incubation with EGF in comparison with the control group (table & figure 2), results showed significant inhibition of adrenaline lipolytic effect by EGF (table & figure4). This antagonism has been expected to be through beta signalling, as proved by significant decrease in adrenaline induced lipolysis after addition of EGF with alpha blocker (table & figure5) and non significant change in adrenaline induced lipolysis after addition of EGF with beta blocker (table & figure6). These results agree with Tebar et al. (2000) who demonstrated that EGF did not affect basal glycerol

release. But, in the presence of the  $\beta$ -adrenergic agonist, EGF interfered with its lipolytic effect. It was the result of the interference with the cAMP signal induced by catecholamines in these cells. (Fu et al. 2008) found that EGF stimulates lipogenesis in differentiated adipocytes. Stimulation of glucose transport by EGF could account for some of the stimulation of lipogenesis in adipocytes. EGF also stimulates fatty acid synthesis in hepatocytes. So, EGF stimulates acetyl-CoA carboxylase activity and increases conversion of glucose into fatty acids, it also inhibits adrenaline-stimulated lipolysis. Thus EGF would reduce the intensity of one of the major lipolytic stimulus affecting thus, the balance between lipogenesis and lipolysis.

Wang et al. (2008) found that both EGF and insulin modulate the cAMP signal generated by lipolytic hormones like catecholamines. While the target of insulin action is the cyclic GMP-inhibited phosphodiesterase (cGI-PDE), the target of EGF action is the interaction between Gs and Gi proteins in the control of adenylate cyclase.

**In Conclusion :** EGF which is secreted in large amount in response to adrenaline stimulation that increased during stress has many metabolic effects. It significantly antagonized adrenaline effect on hepatic glucose output, glucose uptake and lipolysis by adipose tissue, skeletal muscle and liver. This interference was through beta signalling.

### References

**Akira Kumon, Tomoko Hara, and Akira Takahashi (2008) :** Effects of catecholamines on the lipolysis of two kinds of fat cells from adult rabbit Department of Neurochemistry, Psychiatric Research Institute of Tokyo, Setagaya-Ku, Tokyo, Japan . jlr.org by on October 20.

**Caballero M. E., J. Berlangaa, D. Ramirezb, P. Lopez-Sauraa, R. Gozalezb, D. N. Floydc, T. Marchbankd and R. J. Playfordd (2001) :** Epidermal growth factor reduces multiorgan failure induced by thioacetamide Gut; 48 : 34-40.

**Chang An Chu, Dana K. Sindelar, Kayano Igawa, Stephanie**

**Sherck, Doss W. Neal (2000) :** Maya Emshwiller, and Alan D. Cherrington. The direct effects of catecholamines on hepatic glucose production occur via alpha1- and Beta2-receptors in the dog. *Am J Physiol Endocrinol Metab* 279: E463-E473.

**Fu L., Isobe K., Zeng Q., Suzuki K., Takekoshi K. and Kawakami Y. (2008) :** The effects of beta(3)-adrenoceptor agonist CL-316,243 on adiponectin, adiponectin receptors and tumor necrosis factor-alpha expressions in adipose tissues of obese diabetic KKAY mice. *European Journal of Pharmacology*. Apr 14; 584 (1) : 202-6.

**Jorissen R. N., Walker F., Pouliot N., Garrett T. P., Ward C. W. and Burgess A. W. (2003) :** Epidermal growth factor receptor: mechanisms of activation and signalling. *Exp Cell Res* 284: 31-53.

**Kreisman S. H., J. B. Halter, M. Vranic and E. B. Marliss (2003) :** Combined Infusion of Epinephrine and Norepinephrine During Intense Exercise. *Diabetes*, June 1; 52(6): 1347-1354.

**Lorita J., N. Escalona, S. Faraudo, M. Soley and I. Ramirez (2002) :** Effects of epidermal growth factor on epinephrine-stimulated heart function in rodents. *Am J Physiol Heart Circ Physiol*, November 1; 283(5): H1887 - H1895.

**Loubna Erraji-Benchekroun, Dominique Couton, Catherine Postic, Isabelle Borde, Jesintha Gaston, Jean-Gérard Guillet, and Claudine André. (2005) :** Overexpression of B2-adrenergic receptors in mouse liver alters the expression of gluconeogenic and glycolytic enzymes. *Am J Physiol Endocrinol Metab* 288 : E715-E722.

**Matthew J. Watt\*, Trent Stellingwerff†, George J. F. Heigenhauser‡ and Lawrence L. Spriet (2003) :** Effects of plasma adrenaline on hormone-sensitive lipase at rest and during moderate exercise in human skeletal muscle. *J Physiol* Volume 550, Number 1, 325-332, July 1.

**Montserrat Grau, Maria Soley and Ignasi Ramirez (1997) :** Interaction between adrenaline and

epidermal growth factor in the control of liver glycogenolysis in mouse. *Endocrinology*; 138 (6) : 2601-9.

**Nicola A. Horn, Denisa M. Anastase, Klaus E. Hecker, Jan H. Baumert, Tilo Robitzsch, and Rolf Rossaint 8-Epinephrine (2005)** : Enhances Platelet-Neutrophil Adhesion in Whole Blood In Vitro. *Anesth Analg* 2005;100:520-526.

**Pareja M., O. Sanchez, J. Lorita, M. Soley, and I. Ramirez (2003)** : Activated epidermal growth factor receptor (ErbB1) protects the heart against stress-induced injury in mice *Am J Physiol Regulatory Integrative Comp Physiol*, August 1, 285(2): R455 - R462.

**Sanchez O., M. Viladrich, I. Ramirez and M. Soley (2007)** : Liver injury after an aggressive encounter in male mice *Am J Physiol Regulatory Integrative Comp Physiol*, November 1, 293(5): R1908 - R1916.

**Sarah F. Hamm-Alvarez (2002)** : Focus on "EGF receptor downregulation depends on a traf-

ficking motif in the distal tyrosine kinase domain" *Am J Physiol Cell Physiol* 282: C417-C419.

**Sgoifo A., De Boer S. F., West- enbroek C., Maes F. W., Beldhuis H., Suzuki T. and Koolhaas J. M. (1997)** : Incidence of arrhythmias and heart rate variability in wild-type rats exposed to social stress. *Am J Physiol Heart Circ Physiol* 273: H1754-H1760.

**Tebar F., Grau M., Mena M. P., Arnau A., Soley M. and Ramirez I. (2000)** : Epidermal growth factor secreted from submandibular salivary glands interferes with the lipolytic effect of adrenaline in mice. *Endocrinology* 141: 876-882.

**Tomoyuki Yuasa, Rei Kaku- hata, Kazuhiro Kishi, Toshiyuki Obata, Yasuo Shinohara, Yoshi- mi Bando, Keisuke Izumi, Fumi- ko Kajiura, Mitsuru Matsumoto and Yousuke Ebina (2004)** : Platelet-Derived Growth Factor Stimulates Glucose Transport in Skeletal Muscles of Transgenic Mice Specifically Expressing Platelet-Derived Growth Factor Receptor in the Muscle, but It Does Not

Affect Blood Glucose Levels.

**Van Heeswijk J. C. F., G. J. Vianen and G. E. E. J. M. Van den THillart (2005)** : The adrenergic control of hepatic glucose and FFA metabolism in rainbow trout (*Oncorhynchus mykiss*): Increased sensitivity to adrenergic stimulation with fasting. 15 august.

**Wadley G. D., R. S. Lee-Young, B. J. Canny, C. Wasuntarawat, Z. P. Chen, M. Hargreaves B. E. Kemp and G. K. McConell (2006)** : Effect of exercise intensity and hypoxia on skeletal muscle AMPK signalling and substrate metabolism in humans. *Am J Physiol Endocrinol Metab*, April 1; 290(4): E694- E702.

**Wang Y. C., S. K. Kulp, D. Wang, C. C. Yang, A. M. Sargeant, J. H. Hung, Y. Kashida, M. Yamaguchi, G. D. Chang and C. S. (2008)** : Chen Targeting Endoplasmic Reticulum Stress and Akt with OSU-03012 and Gefitinib or Erlotinib to Overcome Resistance to Epidermal Growth Factor Receptor Inhibitors *Cancer Res.*, April 15,68(8): 2820 - 2830.

**Zhou J., Deo B. K., Hosoya K., Terasaki T., Obrosova I. G., Brosius F. C. 3rd, and Kumagai A. K. (2005)** : Increased JNK phosphorylation and oxidative stress in response to increased glucose flux through increased GLUT1 expression in rat retinal endothelial cells. *Invest Ophthalmol Vis Sci* 46: 3403–3410.

REPRINT

# BENHA MEDICAL JOURNAL

**EFFECT OF EPIDERMAL GROWTH  
FACTOR ON ADRENALINE  
INDUCED EFFECTS IN  
VARIOUS TISSUES  
IN VITRO**

**Fayza R. El Menabawy MD., Farida M. El-Bana MD,  
Soheir F. El-Bassiony MD, Hanaa A. Abd El-Moneim MD  
and Shereen M. S. El-Sherbeiny M.Sc.**

**Published by  
Benha Faculty of Medicine**

*Volume 26 Number 3  
Sept. 2009*

## **REPAIR OF NASOSEPTAL PERFORATION BY AN EXTERNAL APPROACH USING DIFFERENT GRAFT MATERIALS**

**Adel Helmy MD, Ahmed S. El-Kady MD  
and Ahmed Hussein MD**

*Department of Otorhinolaryngology,  
Faculty of Medicine, Benha University, Egypt*

### **Abstract**

**Objectives:** *The current study aimed to compare among different graft materials (tragus perichondrium, human acellular dermal graft and inferior turbinate flap) used for the repair of the nasoseptal perforation by an external approach.*

**Patients and Methods:** *The study included 30 patients with traumatic nasal septal perforation located in the anterior cartilaginous part of the nasal septum. All patients underwent full history taking, complete clinical otorhinolaryngological examination including nasal examination by anterior rhinoscopy and rigid 0° endoscope to detect the actual size, extent of the septal perforation and to exclude the associated pathological lesions. The patients were divided into 3 groups: I, II and III according to the graft material used in the repair of the nasal septal perforation. Group I: included 10 patients in whom the repairs of the nasal septal perforation were performed by the use of tragus perichondrium graft, group II: Included 10 patients in whom the repairs of the nasal septal perforation were performed by the use of human acellular dermal graft (Alloderm) and group III: included 10 patients in whom the repairs of the nasal septal perforation were performed by the use of the inferior turbinate flap. One surgical approach, the external transcolumellar approach, was performed in all patients for repair of the nasoseptal perforation. Patients were examined twice weekly in the first month then twice monthly for the next 5 months, for the success of closure of the septal perforation and for the occurrence of any complication.*

**Results:** *The study included 30 patients, 19 males and 11 females with age ranged from 19 to 35 years. The size of the perforation ranged from 0.5x0.5cm to 2x2cm in each group. Small perforations (<1.5x1.5cm)*

were reported in 21 patients (70%), while the large perforations ( $\geq 1.5 \times 1.5$  cm) were reported in 9 patients (30%). The Success rate in group I was 70%, 7 out of 10 patients, while in group II was 90%, 9 out of 10 patients and in group III was 80%, 8 out of 10 patients. Failure reported in 6 out of 30 patients, one patient out of the 6 failed had a perforation less than  $1.5 \times 1.5$  cm and the remaining 5 patients had a large perforation. Stenosis of nasal vestibule was reported in 2 patients of group I, one patient in group II while not recorded in group III. Bleeding, unilateral nasal obstruction and synachia were reported in 2, 3 and 2 patients, respectively of group III. Marked crustations were also reported in few patients of group III.

**Conclusion:** The external transcolumellar approach has many advantages, as it is easy, allows direct access and good exposure of the perforation and surroundings and permits a precise placement and stabilization of the grafts. The highest perforation closure rates were with human acellular dermal graft with the advantage of absence of donor site morbidity. The inferior turbinate flap and tragus cartilage graft also had a good closure rates but not superior to the human acellular dermal graft.

**Key words:** Nasoseptal perforation - External approach - Different graft.

### Introduction

A nasal septal perforation is a through and through defect in any portion of the cartilaginous or bony septum with no overlying mucoperichondrium or mucoperiosteum bilaterally (Romo, et al., 2003). These defects in the cartilaginous areas of the septum, with direct communication between the two nasal cavities, leads to impairment of air flow and pressure which are often accompanied by a wide variety of symptoms. Patients seek medical advice when they de-

velop symptoms which may be very troublesome (crusting, nose bleeding, cacosmia) and may, in some cases, even impair nasal respiration (RE et al., 2006). Symptoms tend to be related to size and location; most symptomatic perforations are large and anterior. Posterior perforations tend to be less symptomatic secondary to humidification from nasal mucosa and turbinates (Romo and Toffel, 1998). The otolaryngologist has to identify the causes, which, in most cases, are iatrogenic or idio-



pathic (Teichgraeber and Russo, 1993).

Many surgical techniques are available for surgical repair of nasal septal perforations. The variety of techniques is evidence that no single technique is recognized as being uniformly reliable in closing all perforations (Friedman et al., 2003). Septal perforation repair surgery can be performed using either the "closed technique" or "open technique". The advantages of the former consist in the fact that it does not leave any external scar. Albeit, many Surgeons prefer the "open" technique, as it offers a wider operating field, thus allowing better access to the superior and posterior margins of the perforation (RE et al., 2006).

A number of different materials both autografts and allografts have been used as interpositional grafts for repairing of septal perforation (Ambro et al., 2003). The inferior turbinate flap for repair of nasal septal perforations of moderate size is a relatively simple technique that offers a success rate comparable to or better than most techniques. The major disad-

vantage is the requirement for a second-stage procedure to release the pedicle (Friedman et al., 2003). Temporalis muscle fascia or auricular conchal cartilage also requires a second-stage procedure. The acellular dermal graft is processed from human donor skin obtained from approved tissue banks. In processing, the epidermis is removed, and the remaining dermal layer is washed in detergent solutions to remove cellular components. After the tissue has been decellulaized, the acellular collagen matrix is then cryoprotected and rapidly freeze-dried by a patented process to preserve biochemical and structural integrity. This packaged acellular dermis can be stored under refrigeration for at least 2 years. Alloderm graft should be soaked for a minimum of 10 minutes in physiologic saline using a normal sterile procedure yields a pliable collagen template for cell repopulation (Lee et al., 2000).

The current study aimed to compare among different graft materials (tragus perichondrium, human acellular dermal graft and inferior turbinate flap) used for the

repair of the nasoseptal perforation by an external (open) approach.

### **Patients and Methods**

This study was conducted on 30 patients with nasal septal perforation attending Benha University Hospital outpatient clinic in the period from July 2004 to December 2006. The patients were divided into 3 groups: I, II and III according to the graft material used in the repair of the nasal septal perforation. Group I: included 10 patients in whom the repairs of the nasal septal perforation were performed by the use of tragus perichondrium graft, group II: Included 10 patients in whom the repair of the nasal septal perforation were performed by the use of human acellular dermal graft (AlloDerm) and group III: included 10 patients in whom the repairs of the nasal septal perforation were performed by the use of the inferior turbinate flap. The patients were selected with traumatic nasal septal perforation located in the anterior cartilaginous part of the nasal septum (Fig. 1). Cases with previously operated turbinate were excluded.

All patients underwent full history taking, complete clinical otorhinolaryngological examination including nasal examination by anterior rhinoscopy and rigid 0° endoscope to detect the actual size of the septal perforation and to exclude the associated pathological lesions.

After obtaining fully-informed written consent, all patients were operated upon under general anesthesia using the external transcolumellar approach adopted by Aiach (2003) in all groups.

Xylocain 1% with 1/200000 epinephrine was infiltrated into the labio-columellar junction, membranous septum, the floor of the nose for homeostasis. An inverted V shaped incision was made at the columellar- philtrum junction (Fig.2).It was then extended posteriorly around the feet of the medial crura on both sides. Complete transfixion incision was made through the membranous septum just caudal to the remnant of the quadrilateral cartilage and extended along its whole length. The base of the columella was dissected free of the underlying labial

soft tissue. A 3/0 silk stay suture was secured through the soft tissue of the columellar flap and secured to the towel for retraction (Fig. 3). The caudal margin of the quadrilateral cartilage and the whole septum on both sides became well exposed. The margins of the perforation were trimmed all around. The mucosal flaps were carefully dissected and elevated starting anteriorly through the perforation on either side of nasal septum to expose the skeletal remnants superiorly, posteriorly, inferiorly and anteriorly.

**In group I and II :** The transfixion incision was extended on both sides along the floor of the nasal fossa as far laterally as possible to underneath of the inferior turbinate, then an anterior to posterior longitudinal incision was made paralleling the attachment of the inferior turbinate beneath it caudally as far as behind the level of the posterior edge of the septal perforation. The next step was elevation of bilateral septal mucoperichondrial-mucoperiosteal flaps starting from the transfixion incision at the caudal border of the remnants of the quadrilateral car-

tilage. Dissection was achieved on both sides, widely elevating the mucosa from the floor of the nasal cavities; so bilateral inferior advancement mucosal flaps were obtained from the floor of the nose that can be advanced superiorly and medially to cover the perforation. The flap must be totally mobilized to achieve maximum tension free for closure.

**In group I :** After dissection and removal of tragal cartilage with its attached perichondrium on both sides, (Fig. 4), the graft was placed as an interpositional graft in-between the free bipedicle mobilized mucosal flaps on both sides of nasoseptal perforation, (Fig. 5). Simple interrupted sutures were secured on both sides using 4/0 or 5/0 chromic sutures to close the flaps with sharp needle which pass in the flap only not the cartilage graft.

**In group II :** The graft material used in this group was an acellular human dermal graft (Alloderm), (Fig. 6). The appropriate sized Alloderm graft which must be larger than the perforation was rehydrated for 10 minutes in

physiologic saline and placed in between the previously described freely mobilized bipediced flaps to close the perforation on its both sides (Fig.7). A continuous suture 4/0 or 5/0 chromic cat gut suture passes through not only the flaps, but also the graft.

**In group III :** In this group we used the inferior turbinate graft from one side, the technique used was that adopted by Friedman et al., (2003).The turbinate is harvested with the use of 0° and 30° endoscopes. The superior medial mucosa incision is made with a knife from the posterior margin to the pedicle (anteriorly) (Fig. 8). The flap is then completed with a scissor, going through the turbinate bone and lateral mucosa to a point just cephalic to the pedicle and extending to the posterior border (Fig. 9). The flap includes mucosa, submucosa, and a variable amount of bone. Any exposed bone from the flap or donor site is removed. The flap is rotated anteriorly and adjusted to fill the perforation. It was sutured with the edge of septal perforation in the same side (Fig. 10). The contralateral side was closed by unilateral

freely mobilized bipediced mucosal flaps. The incision site and the remaining upper half of the turbinate were visualized with an endoscope to control any bleeding points with cautery.

Silastic splint were placed in both sides and light Vaseline nasal pack were placed bilaterally in group I and II and unilaterally in group III. The packs were removed after 48 hours and the splint after one week. Postoperatively, the patients were examined twice weekly in the first month then twice monthly for the next 5 months. In group III, the pedicle was taken down under local anesthesia 3 weeks postoperatively.

### **Results**

The study included 30 patients, 19 males and 11 females with age ranged from 19 to 35 years. The size of the perforation ranged from 0.5x0.5 cm to 2x2 cm in each group. Small perforations (< 1.5x1.5 cm) were reported in 21 patients (70%), while the large perforations ( $\geq 1.5 \times 1.5$  cm) were reported in 9 patients (30%). The success rate with small perforations was 95.2% (20/21 of cases)

while those with large one succeeded by 44.4% (4/9 of cases). This difference in the success is of highly significant value as  $P < 0.01$  (Table 1).

The Success rate in group I was 70%, 7 out of 10 patients, while in group II was 90%, 9 out of 10 patients, and in group III was 80%, 8 out of 10 patients. The difference in the success rate among the 3 groups is of no statistical significant value as  $P > 0.05$ (Table 2).

Failure reported in 6(20%) out of 30 patients; one patient out of the 6 failed had a small perforation less than 1.5x1.5 cm, while the remainder 5 patients had a large perforation. Figure (11) shows healed septal perforation with the use of tragus perichondrium graft, Fig. (12) shows healed septal perforation with the

use of Alloderm and Fig.(13) shows healed septal perforation with the use of inferior turbinate flap.

Stenosis of nasal vestibule was recorded in 2 patients (20%) group I (Fig. 14), one patient (10%) in group II while in group III no cases were reported. Bleeding was reported in 2 patients of group III during excision of the pedicle, which was controlled by diathermy. Crusts in group I and II were minimal and washed out easily with normal saline while in group III crusts were marked and were in need for removal in every visit. Two patients of group III had unilateral synachia after release of the pedicle of the inferior turbinate. Nasal obstruction was reported 2 weeks postoperatively in 3 patients of group III which was unilateral (Fig 15).

**Table (1): shows the success rate according to the size of the septal perforation.**

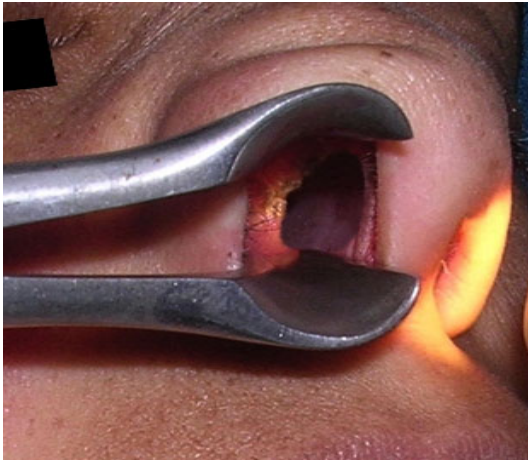Perforation size	Succeeded		Failed		Total		X2	P
	No	%	No	%	No	%		
Small (< 1.5_1.5 cm)	20	95.2.0	1	4.8.0	21	100.0	6.37	P< 0.01
Large (≥ 1.5_1.5 cm)	4	44.4.0	5	55.6.0	9	100.0		
<b>Total</b>	<b>24</b>	<b>80.0</b>	<b>6</b>	<b>20.0</b>	<b>30</b>	<b>100.0</b>		
<b>Test of Significance</b>	<b>Z = 3.51</b>				<b>P &lt; 0.01</b>			

**Table (2): Shows the success rate among the 3 groups according to the graft material used in repair.**

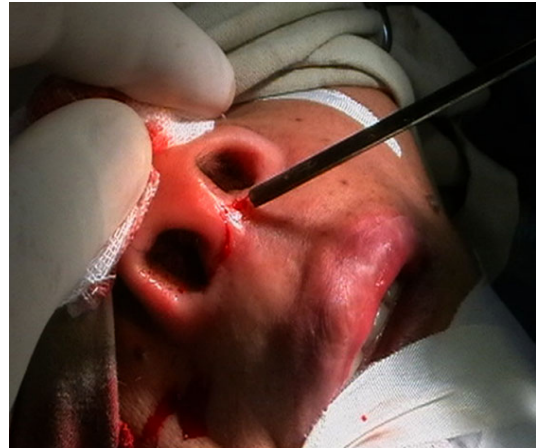Groups	Succeeded		Failed		Total	
	No	%	No	%	No	%
I	7	70.0	3	30.0	10	100.0
II	9	90.0	1	10.0	10	100.0
III	8	80.0	2	20.0	10	100.0
<b>Total</b>	<b>24</b>	<b>80.0</b>	<b>6</b>	<b>20.0</b>	<b>30</b>	<b>100.0</b>

Chi-square:-  $X^2 = 1.25$

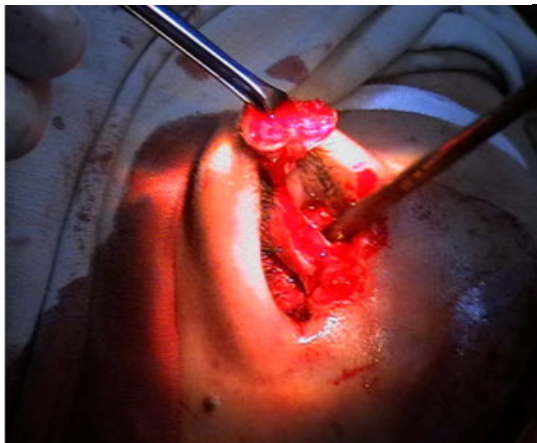$P > 0.05$



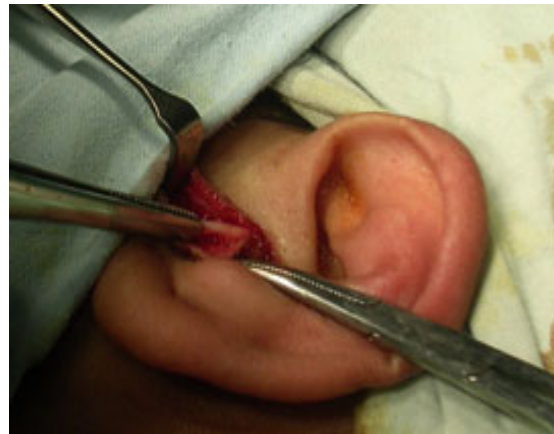**Fig. (1): Shows anterior large nasal septal perforation.**



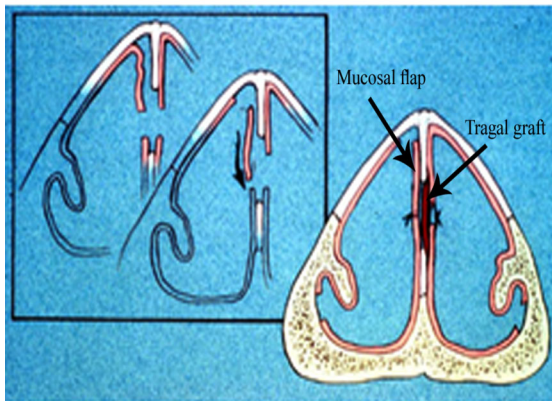
**Fig. (2): Shows inverted v shaped incision at the columellar-philtrum**




**Fig. (3): Shows complete transfixing incision through the membranous septum freeing it from its attachment till the tip of the nose.**



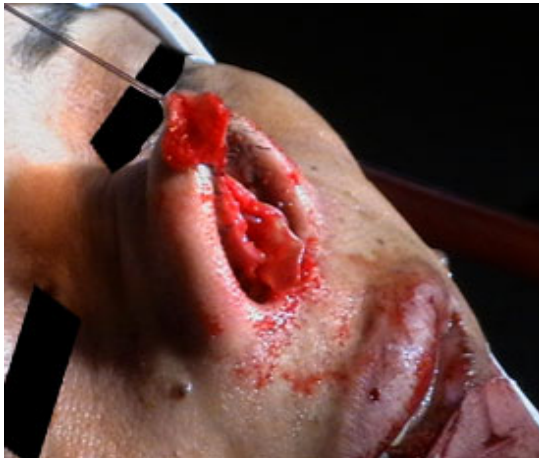**Fig. (4): Shows the dissection of a tragus cartilage graft.**



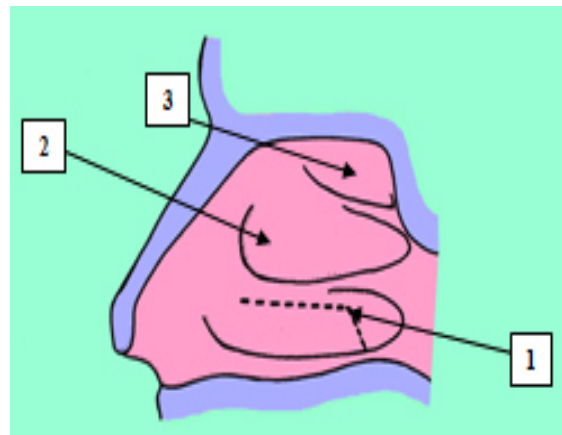
**Fig. (5):** Diagram shows the graft is placed as an Interpositional graft in-between the freely bipediced mucosal flaps .



**Fig. (6):** Shows the packaged human acellular dermal graft.

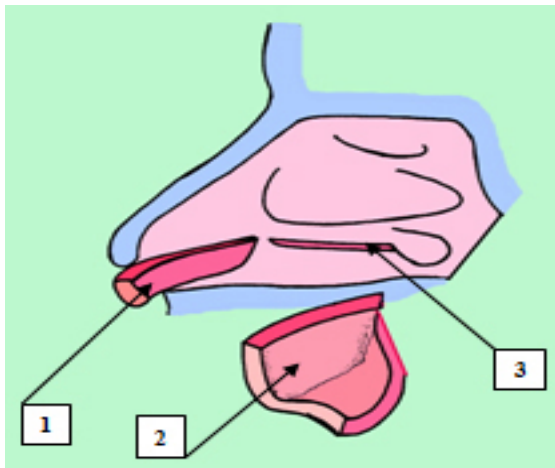


**Fig. (7):** Shows Alloderm graft is placed in-between the freely mobilized bipediced mucosal flaps.

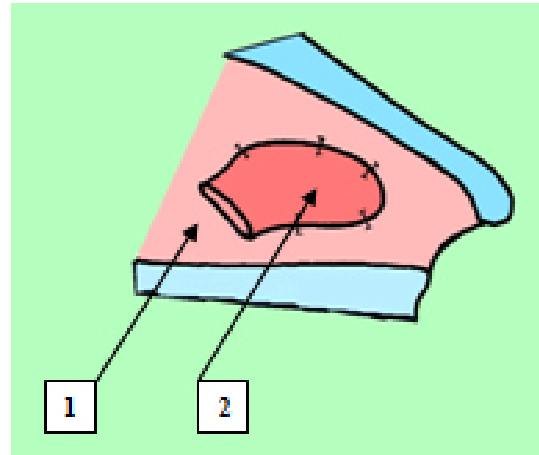


**Fig. (8):** Diagram shows the incision of inferior turbinate done with a scissor going through the turbinate, (1) Line of incision, (2) middle turbinate, (3) superior turbinate.

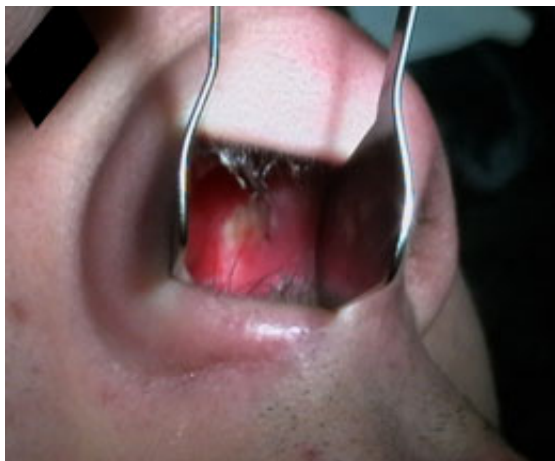



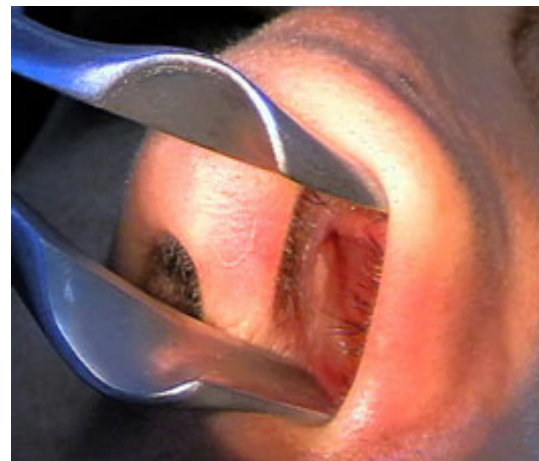**Fig. (9):** Diagram shows, (1) The inferior turbinate flap rotated anteriorly, (2) the flap is opened to create a mucosal surface, (3) line of cleavage of the inferior binate from the lateral nasal wall.



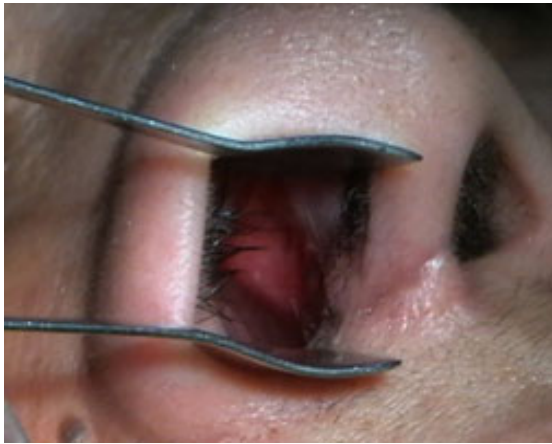
**Fig. (10):** Diagram shows the inferior turbinate flap is sutured to the surrounded tissue. (1) The septum, (2) inferior turbinate flap closing the septal perforation after excision of its pedicle.



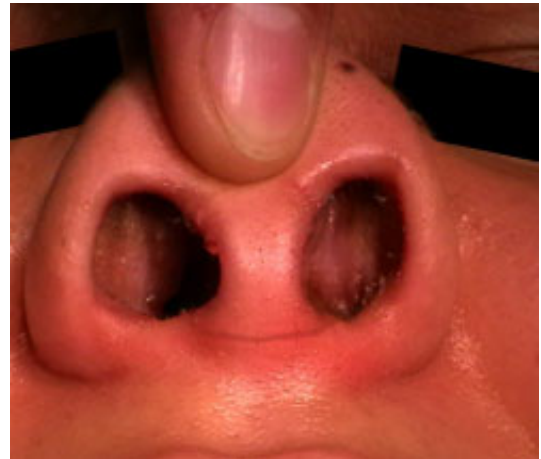**Fig. (11):** Shows healed septal perforation with the use of tragus perichondrium graft.



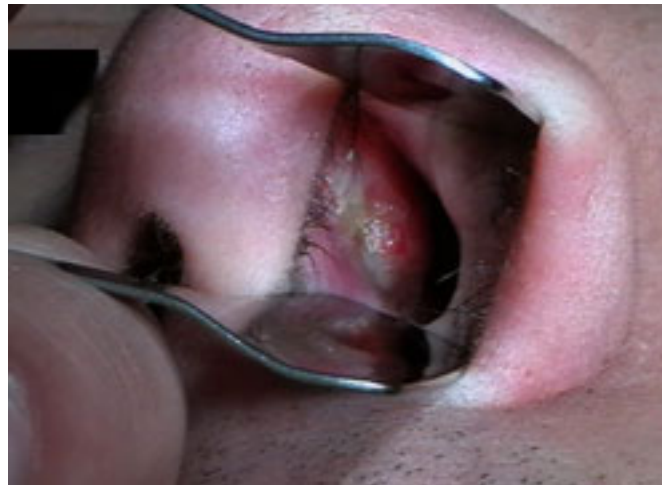**Fig. (12):** Shows healed septal perforation with the use of human acellular dermal graft.



**Fig. (13): Shows healed septal perforation with the use of inferior turbinate flap.**



**Fig. (14): Shows a case of repaired septal perforation complicated by unilateral vestibular stenosis.**



**Fig. (15): Shows a case of repaired septal perforation complicated by nasal obstruction due to bulky tissue graft used in repair (inferior turbinate).**

### **Discussion**

Surgical repair of nasal septal perforations is made difficult by the paucity of nasal mucosa available for use; this mucosa is often friable and damaged by vasculitis. Because it is based on mucoperichondrium and mucoperiosteum, the mucosa is not amenable to acute distention or expansion. Traditional methods for closure of septal perforations can be variably successful for small and anterior perforations or unreliable and unrealistic for large and more posterior perforations (Romo et al., 1999).

In our study we selected one approach which is the external transcolumellar approach which has many advantages: easy, allows direct access to usually undisturbed dorsal septum, allows for better exposure to the surrounding portions of the perforation and all parts of the septum, permits a precise placement and stabilization of the grafts and affords binocular vision with two free hands for surgeon. This external transcolumellar approach has been described by (Raman, 1990), (Kridel et al., 1998), (Aiach, 2003),

and also by (Romo et al., 2003) each has used a different graft material for repair of the nasal septal perforation.

In our study regarding to the results of group I, seven patients out of ten have shown complete closure of nasal septal perforation with success rate of (70%). Failure reported in three patients, two had large size perforation and other one had small perforation and they were associated with infection and cartilage necrosis. Our results agreed with that reported by (Woolford and Jones, 2001).

In group II, the repair of the nasal septal perforation was performed by the use of human acellular dermal graft (Alloderm). The Alloderm has been in use for several years for skin grafting for the treatment of patients with acute burns and has been shown to increase dermal matrix (Wainwright, et al., 1996). Also used in the repair of Frey syndrome by (Uttam et al., 2003). The use of Alloderm to resolve different medical problems confirm that this material has many advantages: absence of donor site morbidity, thick, easy

to be placed and sutured and gave more substance to the repaired defect. Its dermal matrix is incorporated into the surrounding tissues and because the graft is acellular it doesn't elicit an immune response.

The success rate in group II was 90%, nine patients of ten showed complete closure of the perforation, one case only failed due to the size of the perforation which was large (2 x 2 Cm). Our results agreed with (Russel et al., 1998), they showed eleven patients of twelve had successful outcomes with complete closure of their perforation the remaining patient had an acceptable result but incomplete closure; his initial perforation of 3 cm was reduced to 0.5 cm, making him asymptomatic after surgery. Our results also coincide with that reported by (Romo et al., 2003), (Ayshford et al., 2003) and (Kyung et al., 2008).

The success rate in group III was 80%, eight patients of ten had complete closure with subsequent disappearance of their previous symptoms. Failure reported in two

patients with a large size perforation. Our results granted with (Kilty et al., 2007), they reported that 80% of the perforations treated in their series were completely closed. Also our results nearly agreed with that reported by (Friedman et al., 2003).

Although, of the good healing results, we faced more than a complication in this group; Bleeding on release of the pedicle of the inferior turbinate, excessive crustations, and nasal obstruction which attributed to the bulky graft material and adhesions occurred between the inferior turbinate graft and its raw base on the lateral wall of the nose. However this technique has many advantages; the key advantages of the inferior turbinate flap are abundant vascularity, wide arc of rotation, combined skeletal and epithelial support and ease of development and insertion.

Another important advantage is that it uses respiratory tract mucosa, which allows the repaired septum to achieve physiological normalcy. Other methods that use skin grafts or buccal mucosa

grafts may be effective in closing the perforations but leave the patient with a dry nose that continue to crust because skin normally sheds and normal respiratory tract mucosa is not present (Kridel, 1998). The major disadvantage is the requirement for a second stage procedure to release the pedicle and the subsequent possible bleeding. The abundance of tissue that makes it a reliable flap is also a disadvantage because the flap may have enough bulk to cause partial obstruction of the airway. Another disadvantage is that one surface is not epithelialized and must heal by secondary intention (Friedman et al., 2003). But in our study to avoid this disadvantage we covered this contralateral side by a unilateral free mucosal flap.

### Conclusion

The external transcolumellar approach has many advantages, as it is easy, allows direct access and good exposure of the perforation and surroundings and permits a precise placement and stabilization of the grafts. The highest perforation closure rates were with human acellular dermal graft

with the advantage of absence of donor site morbidity. The inferior turbinate flap and tragus cartilage graft also had a good closure rates but not superior to the human acellular dermal graft.

### References

**Aiach G. (2003)** : External transcolumellar approach and cartilage grafting: a very complementary association: Rev stomatol Chir Maxillofac. Sep; 104(4): P. 215 - 222.

**Ambro B. T., Zimmerman J., Rosenthal M. and Pribitkin E. A. (2003)** : Nasal septal perforation repair with porcine small intestinal submucosa. Arch Facial Plast Surg. Nov-Dec; 7(6): P. 528-529.

**Ayshford C. A., Shykhon M., Uppal H. S. and Wake M. (2003)** : Endoscopic repair of nasal septal perforation with a cellular human dermal allograft and an inferior turbinate flap. Clinical Otolaryngology & Allied Sciences Vol 28 February: P. 29.

**Friedman M., Ibrahim H. and Ramakrishnan V. (2003)** : Inferior turbinate flap for repair of na-

sal septal perforation. *Laryngoscope*; 113:1425-8.

**Kilty S. J., Brownrigg P. J. and Safar A. (2007)** : Nasal septal perforation repair using an inferior turbinate flap. *J Otolaryngol.*; 36(1):38-42.

**Kridel RWH, Foda H, Lunde K C, (1998)**: Septal perforation repair with acellular human dermal allograft. *Arch Otolaryngol ,Head Neck Surg*; 124:73-8.

**Kyung Chul Lee, No Hee Lee, Jae Ho Ban and Sung Min Jin (2008)** : Surgical treatment using an allograft dermal matrix for nasal septal perforation. *Yonsei Med J* 49(2):244- 248.

**Lee H. M., Kim S. T., Cho J. H., Lee J. H., Choi C. S., Hwang S. J., et al. (2000)** : Reconstruction of septal perforation with aloderm. *Korean J Otolaryngol*; 43:1323-7.

**Raman R. (1990)** : Closure of large septal perforations. *Laryngoscope*; 100:789-90.

**RE. M., Paolucci. L., Romeo.**

**R. and Mallardi. V. (2006)** : Surgical treatment of nasal septal perforations. Our experience. *Acta Otolaryngol; ITAL* 26, 102-109.

**Romo T. and Toffel P. H. (1998)** : Nasal septal perforation. In: Gates GA, editor. *Current therapy in Otolaryngology Head and Neck Surgery*. St. Louis: Mosby; p. 339-44.

**Romo T. III., Carig A. Foster, Gwen S.Korovin, Michael E. Sachs. (1999)** : Repair of Nasal septal perforation Utilizing the Midface Degloving Technique. *Archives of Otolaryngology- Head and neck surgery*. July, Vol 114 : P.432-437.

**Romo T. III, Daniel G Becker, Francisco Talavera, Pharmd, Dean Toriumi, Christopher L slack, and Arlen D Meyers, MBA (2003)** : Septal perforation: surgical Aspects e medicine. Last updated: August 15, 2003.

**Russell W. H. Kridel, Hossam Foda, Kevin C. Lunde. (1998)** : Septal perforation Repair with acellular human dermal allograft.

Arch Otolaryngol head neck surg,  
Vol 124: P. 73- 78.

**Teichgraeber J. F. and Russo  
R. C. (1993) :** The management of  
septal perforations. Plast Reconstr  
Surg, 91:229-35.

**Uttam K. Sinha, Daryoush  
Saadat, Carolyn M. Doherty,  
Dale H. Rice. (2003) :** Use of Allo-  
derm Implant to prevent Frey syn-  
drome after parotidectomy. Arch  
Facial plast surg Vol 5, Jan: P.  
109-112.

**Wainwright D., Madden M.  
and Luterman A. (1996) :**  
Clinical evaluation of an acellu-  
lar allograft dermal matrix in  
full - thickness burns. J Burn  
Care Rehabil, 17 : P. 124 -  
136.

**Woolford T. J. and Jones N.  
S. (2001) :** Repair of nasal septal  
perforations using local mucosal  
flaps and a composite cartilage  
graft. The Journal of Laryngology  
& Otology January, Vol. 115 : P.  
22-25.

REPRINT

# BENHA MEDICAL JOURNAL

## REPAIR OF NASOSEPTAL PERFORATION BY AN EXTERNAL APPROACH USING DIFFERENT GRAFT MATERIALS

Adel Helmy MD, Ahmed S. El-Kady MD  
and Ahmed Hussein MD

Published by  
Benha Faculty of Medicine

*Volume 26 Number 3*  
*Sept. 2009*



**SURGICAL FEASIBILITY AND OUTCOME OF  
SUPERFICIAL MUSCULOAPONEUROTIC SYSTEM  
(SMAS) ADVANCEMENT FLAP FOR PAROTID  
BED COVERAGE AFTER SUPERFICIAL  
PAROTIDECTOMY**

**Mahmoud M. Algamal MD, Emad Abdel Hafez MD,  
Kassem M Kassem MD\* and Abou-Bakr E. Ras MD\***

*Departments of General Surgery & Otorhinolaryngology\*,  
Faculty of Medicine- Benha University, Egypt*

**Abstract**

**Objectives:** *This study aimed to evaluate surgical feasibility and the aesthetic outcome and frequency of development of Frey's syndrome after superficial parotidectomy with superficial musculoaponeurotic system (SMAS) advancement.*

*The study included 23 patients assigned for superficial parotidectomy; 15 men and 8 females with mean age of  $36.7 \pm 9.7$ . Surgery was conducted through a modified Blair incision and the skin flap was raised under the periparotid fascia. Facial nerve and its branches and the great auricular nerve were dissected and preserved. The parotid swelling was dissected and excised with preservation of the parotid duct. The SMAS flap was dissected sharply from the skin and superficial fascia and then stretched and advanced so as to cover the dissected raw area and fixed to the anterior edge of the sternomastoid. Patients were observed and followed-up for the development of Frey's syndrome and the aesthetic outcome depending on subjective satisfaction with the incision scar and depth of the retromandibular dimple as assessed on a visual analogue scale ranged between 0=unsatisfied and 10=highly satisfied.*

**Results:** *The application of SMAS flap allowed disappearance of retromandibular defect and wound dimpling in 21 patients with mean patients' satisfaction score about the aesthetic appearance was  $7.4 \pm 1.8$ ; range: 2-9. Moreover, throughout the follow-up period only one patient had gustatory complaints (Frey's syndrome).*

**Conclusion:** *The use of SMAS advancement flap fixed to the anterior*

*margin of sternomastoid to cover the surgical raw area after parotidectomy is surgically feasible and effective surgical policy for minimizing the frequency of the development of Frey's syndrome and postoperative retromandibular dimpling and with high patients' satisfaction score and is advocated for surgical treatment of benign parotid lesions requiring superficial parotidectomy*

### **Introduction**

Frey's syndrome is an unpleasant phenomenon characterized by recurrent episodes of facial gustatory flushing and sweating limited to the cutaneous distribution of the auriculotemporal nerve which, when injured, shows abnormal regeneration. The condition is relatively common in adults following nerve injury in parotid surgery, (Carpintero et al., 2006).

Frey's syndrome is thought to be due to aberrant reinnervation of sympathetic fibres supplying sweat glands by postganglionic parasympathetic fibres normally supplying the parotid gland. These sympathetic fibres have the peculiarity of being cholinergic, which is an exception in the physiology of the sympathetic system; so two different kinds of fibres use the same neuromediator allowing misdirected parasympathetic regeneration, (Luna-Ortiz et al., 2004).

Considering such etiology of Frey's syndrome could explain the late presentation of such complication to occur within a range of 20 days to 22 months, (Henney et al., 2009).

Baek et al., (2009) conducted questionnaire survey for quality of life issues after parotidectomy and found Frey's syndrome was identified as the most serious self-perceived sequela, and resulting discomfort worsened with time, while scores for other sequelae were similar and concluded that additional measures which prevent or ameliorate Frey's syndrome are likely to improve long-term quality of life after parotidectomy.

The second, but less distressing sequela of majority of parotidectomy was the visible hollow in the retromandibular region, which can extend onto the cheek (Post-

partodiectomy dimple) and some patients desiring aesthetic improvement in their facial appearance, (Boynton et al., 2006). Advanced age, long operation time and large specimen volume were significant risk factors for such complications, (Guntinas-Lichius et al., 2006).

Superficial fascia of the face and neck overlying the parotid and cheek area is referred to as the superficial musculoaponeurotic system (SMAS). This system has an extensive domain; with the galea is its superior extension and the intermingling with the platysma its lower-most extension, as the SMAS courses over the deep temporal fascia, it commonly is labeled the temporoparietal fascia or superficial temporalis fascia. At the level of the zygomatic arch, the attachments of the SMAS vary and tend not to be contiguous. As the SMAS moves inferiorly it overpasses the parotid gland. The SMAS is attached to the deep fascia and skin via parotid-cutaneous ligament-like tissue projections. The SMAS courses anterior to the masseter muscle and then dives down to envelop

the muscles of facial expression. A thinner layer of the SMAS invests the undersurface of the skin of the face, (Ghassemi et al., 2003).

Macchi et al., (2009) reported that SMAS, in all specimens, consisted of two different fibroadipose connective layers; a layer of vertically oriented fibrous septa, connecting the dermis with the superficial aspect of the SMAS and a deep obliquely oriented fibrous septa connecting the deep aspect of the SMAS to the parotid-masseteric fascia. There was progressive thinning of the SMAS from the preauricular district to the nasolabial fold to be unrecognizable. The connective subcutaneous tissue of the face forms a three-dimensional network connecting the SMAS to the dermis and deep muscles. These connective laminae connect adipose lobules of various sizes within the superficial and deep fibroadipose tissues.

The SMAS was used in facial rejuvenation; Mowlavi & Wilhelmi (2004) advocated the extended SMAS rhytidectomy for improving nasolabial fold prominence, Bisac-

cia et al., (2004), used an incision in the preauricular area and then minor undermining to lift the SMAS, followed by SMAS plication and removal of skin laxity in the midface and reported excellent superolateral reversal of inferomedial displacement of the aging vector. Khawaja & Hernandez-Perez (2005), found pulling up and fixation of the superficial SMAS to the periosteum of the temporal bone through needle transcutaneous approach a simple, quick, and mini-invasive ambulatory approach in patients requiring mild to moderate lift. Wang et al., (2006), reported that the application of pedicle SMAS flap and platysma flap in face lifting is simple and safe.

This prospective study was designed to evaluate the feasibility and outcome of SMAS advancement after superficial parotidectomy as regards the frequency of development of Frey's syndrome and the aesthetic appearance.

### **Patients & Methods**

This study was conducted at Departments of General Surgery and Otorhinolaryngology, Benha

University Hospital since Sep 2007 till June 2009 and included 23 patients assigned for superficial parotidectomy. All tumors were benign; there was no palpable lymph node and MRI had shown no evidence of spread.

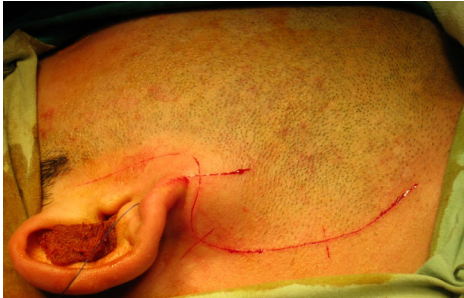### **Operative Technique :**

All surgeries were performed under general endotracheal anesthesia, patients received prophylactic antibiotic in the form of 3rd generation cephalosporins. Patient's head was positioned to rest on a pillow on the healthy side and the external auditory meatus was plugged and ear lobule was folded and retracted for complete exposure of the swelling.

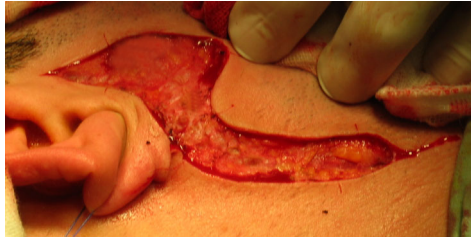
A modified Blair incision was used (Figure 1a) with the preauricular limb of the incision was made in the preauricular crease. Skin incision was deepened, (Figure 1b) and the flaps were raised under the periparotid fascia, using cutting diathermy, to the superior, anterior and inferior borders of the gland and the gland tissues are exposed, (Figure 1c). Blunt dissection with a haemostat was used while exposing the anterior

border of the gland where the distal branches of the facial nerve emanate from the gland on to the masseter muscle. The great auricular nerve was identified and its posterior branch was preserved before the dissection of the facial nerve was commenced so as to diminish the loss of sensation to the earlobe. Dissection was continued till exposure of the tendon of the posterior belly of diagastric muscle, (Fig. 1d) and anterior margin of the tendon of the sternomastoid muscle, (Fig. 1e). The facial nerve was found emerging at the postero-superior margin of the posterior belly of diagastric (used as landmark for nerve identification) and lying across the Stensen's duct in most cases, the duct was used as a landmark for the identification of the buccal branches of the facial nerve; the skin flap is pulled by a retractor to expose the protrusion of the anterior border of the gland, where Stensen's duct emanates from the gland onto the masseter muscle. The retromandibular vein is used as a landmark for the identification of the marginal mandibular branch, and the zygomatic arch for the zygomatic branch of the facial nerve.

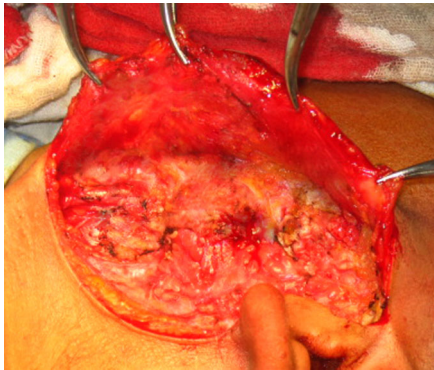
The duct was preserved. As the bifurcation, (Fig. 1f) and main trunk, (Fig. 1g) of the facial nerve were exposed, the gland was resected at the posterior border. Interlobular ducts, encountered during the dissection were ligated carefully to prevent the establishment of a salivary fistula. The wound is irrigated with saline and the integrity of the facial nerve is checked. The SMAS flap was dissected sharply from the skin and superficial fascia (Fig. 1h) and then was stretched and advanced so as to cover the dissected raw area and fixed using vicryl 2/0 sutures to the anterior edge of the sternomastoid, (Fig. 1i). Closed suction drainage was used, the suction drain tube was inserted through a separate stab into the sub-SMAS space, (Fig. 1j) away from the dissected facial nerve to prevent damage to the nerve and wound was closed using subcuticular proline 4/0 suture. Closed suction drainage with external pressure by gauge was maintained for 48 or 72 hours and, thereafter, a thin layer of gauze is placed on the wound. The sutures were removed one week after operation.



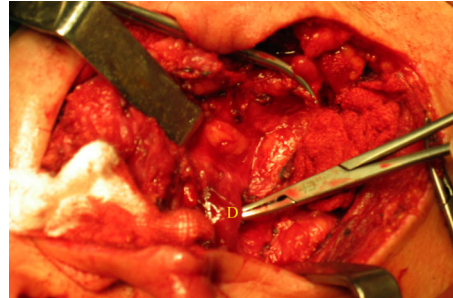
**Fig. (1a):** Modified Blair incision; the preauricular incision was made in the preauricular crease.



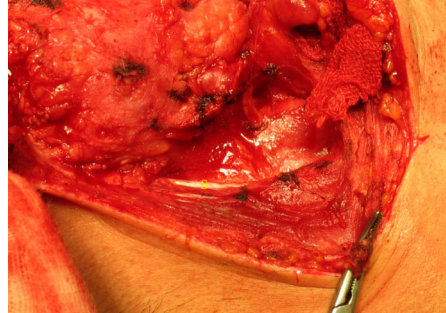
**Fig. (1b):** Skin incision was deepened down to the parotid fascia.



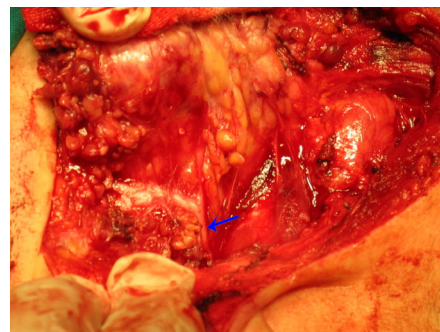
**Fig. (1c):** Skin flap was raised under the periparotid fascia to the superior, anterior and inferior borders of the gland and the gland tissues were exposed.



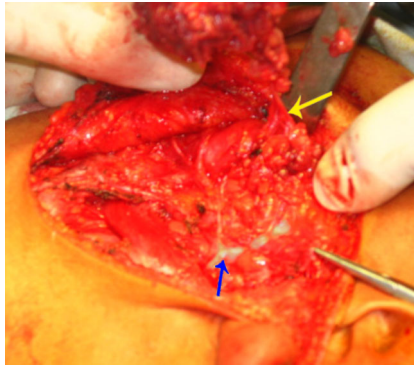
**Fig. (1d):** Dissection was continued till exposure of the tendon of the posterior belly of diagastric muscle (D).



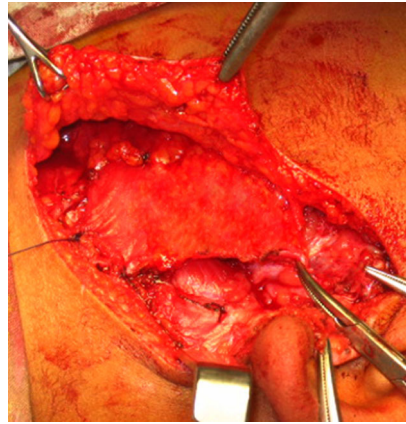
**Fig. (1e):** Dissection was continued till exposure of the anterior margin of the tendon of the sternomastoid muscle (S).



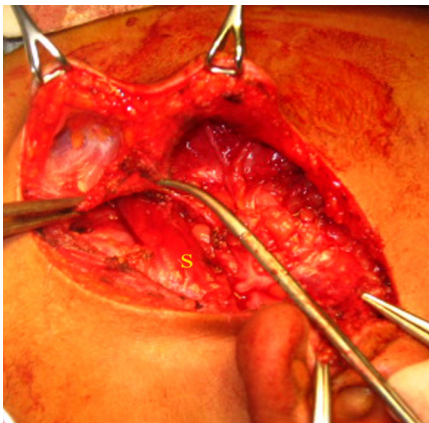
**Fig. (1f):** Main trunk of facial nerve exposed (arrowed).



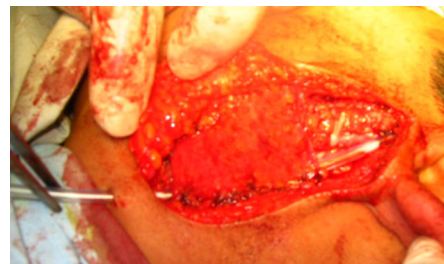
**Fig. (1g):** bifurcation of facial nerve (blue arrow) and Stensen's duct (yellow arrow) were exposed.



**Fig. (1i):** SMAS flap advanced so as to cover the dissected raw area and fixed to the anterior edge of the sternomastoid.



**Fig. (1h):** SMAS flap was dissected sharply from the skin and superficial fascia.



**Fig. (1j):** Suction drainage tube was inserted through a separate stab into the sub-SMAS space.

**Outcome evaluation :**

1. Primary outcome : the surgical feasibility, intraoperative bleeding, operative time and postoperative complication namely; occurrence of facial nerve weakness, hemoatoma or seroma formation, local saliva accumulation, or salivary fistula.

2. Secondary outcome: the development of Frey's syndrome and the aesthetic outcome. All patients were photographed in front and lateral views, pre and postoperatively, for comparison and aesthetic outcome was determined depending on subjective satisfaction with the incision scar and depth of the retromandibular dimple as assessed on a visual analogue scale ranged between 0=unsatisfied and 10=highly satisfied.

**Results**

The study included 23; 15 men and 8 females with mean age of 36.7±9.7; range: 21-53 years. Female patients were non-significantly ( $p>0.05$ ) older than males, (Table 1).

All patients had smooth intra-

operative course with mean operative time of 91±9.1; range: 80-110 minutes. Intraoperative blood loss was minimal during both parotidectomy and dissection of SMAS flap. Suction drains were removed after a mean duration of 58±11.2; range: 48-72 hours, (Fig. 2). Mean hospital stay was 3.8±0.8; range: 3-5 days. (Table 2).

Throughout the immediate postoperative period till time of hospital discharge, no salivary fistulae were reported. Mild cheek edema was noticed in 7 cases and resolved on conservative treatment with anti-edematous drugs. No wound infection or hematoma collection was noticed. Nine cases had temporary facial weakness that was resolved after a mean duration of 1.8±0.7; range: 1-3 months. Throughout the postoperative follow-up only one patient developed Frey' syndrome 10 months after surgery and 2 patients had complained of retromandibular recess, (Table 3, Fig. 3).

Evaluation of patients' satisfaction about the aesthetic appearance; revealed that 4 patients



(17.5%) had VAS=9, 13 patients (56.5%) had VAS=8, 2 patients (8.8%) had VAS score=7 and only 2 patients (8.8%) were partially satisfied. Two patients were unsatisfied and reported scores 2 and 3, respectively, (Table 4, Fig. 4). The mean patients' satisfac-

tion score about the aesthetic appearance was  $7.4 \pm 1.8$ ; range: 2-9. Female patients showed non-significantly lower mean satisfaction score ( $6.6 \pm 1.8$ ; range: 3-8) compared to that recorded for male patients ( $7.8 \pm 1.6$ ; range: 2-9), (Fig. 5).

**Table (1):** Patients' data.

	<b>Males</b>	<b>Females</b>	<b>Total</b>
Number	15 (65.2%)	8 (34.8%)	23 (100%)
Age (years)	$36 \pm 9.1$ (21-53)	$37.8 \pm 11.2$ (25-53)	$36.7 \pm 9.7$ (21-53)

Data are presented as mean $\pm$ SD & numbers; ranges & percentage are in parenthesis

**Table (2):** Operative and postoperative data

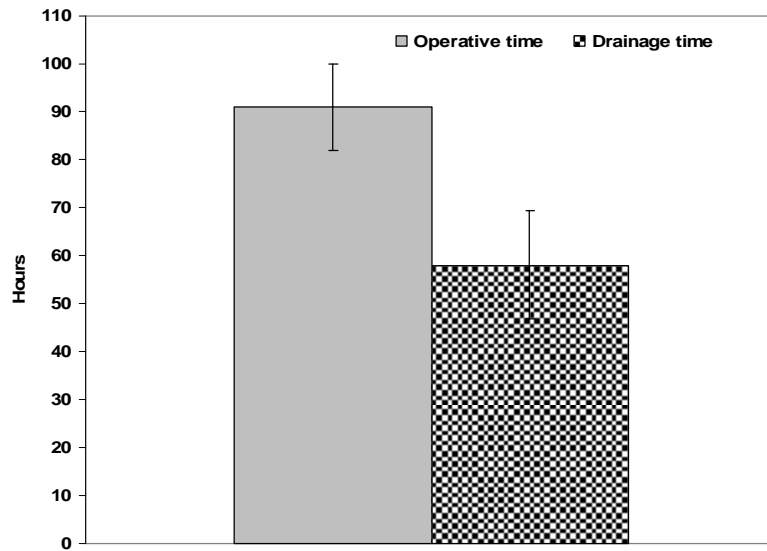
	<b>Mean<math>\pm</math>SD</b>	<b>Range</b>
Operative time (minutes)	$91 \pm 9.1$	80-110
Wound drainage period (hours)	$58 \pm 11.2$	48-72
Hospital stay (days)	$3.8 \pm 0.8$	3-5

**Table (3):** Postoperative complications.

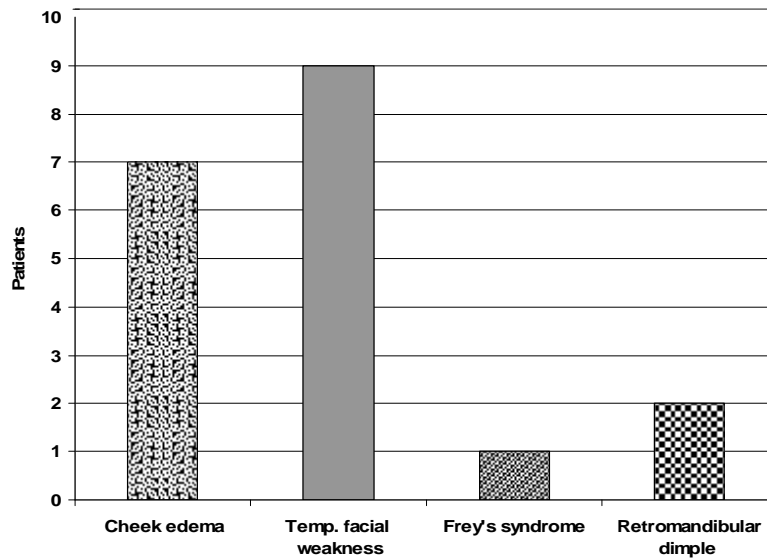
	<b>Number</b>	<b>(%)</b>
Salivary fistula	0	0
Cheek edema	7	30.4%
Wound complications	0	0
Temporary facial nerve weakness	9	39.1%
Frey's syndrome	1	4.3%
Retromandibular dimple	2	8.7%

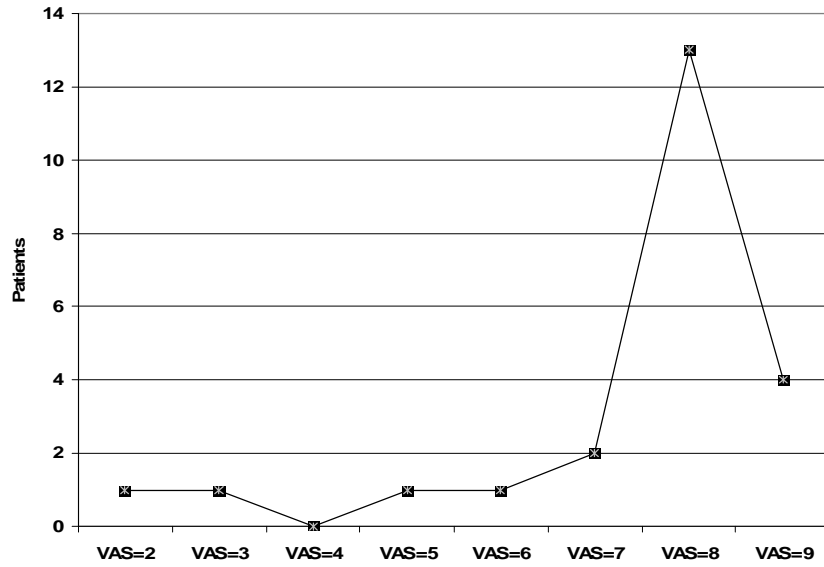
**Table (4):** Patients' satisfaction scores.

<b>Satisfaction scores</b>	<b>Number (%)</b>
VAS score=9	4 (17.5%)
VAS score=8	13 (56.5%)
VAS score=7	2 (8.8%)
VAS score=6	1 (4.3%)
VAS score=5	1 (4.3%)
VAS score=4	0
VAS score=3	1 (4.3%)
VAS score=2	1 (4.3%)

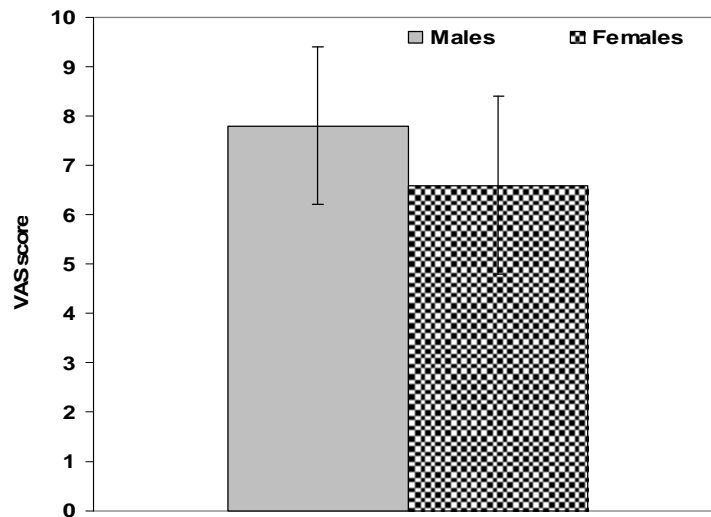


**Fig. 2 :** Mean ( $\pm$ SD) operative and wound drainage times.





**Fig. 4 :** Patients' distribution according to PO aesthetic satisfaction.



**Fig. 5 :** Satisfaction scores of male and female patients.

### **Discussion**

The primary outcome of the present study was the feasibility of identification, dissection and obtaining the SMAS uninterrupted to use it as a coverage for the resultant raw parotid bed; SMAS being located among structures of superficial fascia necessitated firstly dissection and elevation of the skin flap at level of sub-SMAS space at the parotid fascia so as to elevate SMAS within that flap; such maneuver also allowed preservation of the contents of the superficial fascia especially branches of the facial nerve and allowed identification of the zygomatic branch of the facial nerve at the zygomatic arch and was easy but meticulous so as not to miss any of parotid-cutaneous ligament-like tissue projections that may be obstacle for completion of dissection up to the zygomatic arch. This procedure was partially time-consuming resulted in longer operative time that extended for a mean of 91 minutes. Similarly, Zhi et al., (2008), reported significantly longer operative time with preserving the fascia parotidomasseterica and great auricular nerve and partial parotidectomy

compared to routine parotidectomy. One of disadvantages of such plane was perioperative bleeding, (Yu, 2001), however, this was overcome by careful use of cutting diathermy and identification of tissue projections that contains blood vessels.

Dissection and separation of SMAS out of contents of superficial fascia was easy, not time consuming with minimal bleeding. Similarly, Meningaud et al., (2006), found the dissection of SMAS is easy and rapid, provided undermining has carried out at the level of the parotid aponeurosis. This could be attributed to the previously performed control of feeding vessels passed through parotid-cutaneous ligament-like tissue projections.

Moreover, the modified Blair incision used allowed full dissection of the parotid area and exposure of all gland boundaries so that all patients had smooth postoperative course with good wound healing and no wound edge necrosis. This finding goes in hand with Wormald et al., (2009), who reported that using modified Blair incision

resulted in minor morbidities with lesser frequency than the traditional Blair incision.

The application of SMAS flap allowed disappearance of retromandibular defect and wound dimpling with mean patients' satisfaction score about the aesthetic appearance was  $7.4 \pm 1.8$ ; range: 2-9. Only 2 patients were unsatisfied and one of them developed Frey's syndrome. Both patients had long-standing large parotid adenoma and required extensive dissection for adhesions a factor that did not allow perfect separation of the SMAS and so no complete coverage of the raw area was possible.

The obtained results agreed with Honig, (2004), who reported that the vascularized SMAS rotation advancement flap is clinically simple to perform and provides satisfactory cosmetic and functional results in patients undergoing conservative parotidectomy and were superior to that obtained by Angspatt et al., (2004), who reported that the incidence of Frey's syndrome was substantially reduced from 48% by subjective re-

view and 72% by objective measurement in patients underwent parotidectomy without using the SMAS preservation technique to 23.1 and 26.9%, respectively in patients had SMAS preservation. Zhao et al., (2005) used a modified parotidectomy with conserving the sub-superficial musculo-aponeurotic system and great auricular nerve reported an incidence of Frey's syndrome of 5.32%.

These results illustrated the superior outcome of using SMAS flap repositioned to cover the surgical raw surface and advanced to be sutured to the anterior margin of the sternomastoid thus obliterating the retromandibular defect and gaining satisfactory aesthetic outcome. Such outcome is highly comparable to results obtained with conventional parotidectomy; Nitzan et al., (2004) evaluated the quality of life of 125 patients underwent conventional parotidectomy for change in appearance, gustatory sweating, and pain that were reported by 70%, 57% and 30%, respectively. Also, Luna-Ortiz et al., (2004), reported a frequency of Frey's syndrome in 61% of their series of superficial paroti-

dectomy. Guntinas-Lichius et al., (2006), retrospectively evaluated the frequency of Frey's syndrome in 610 patients underwent conventional parotidectomy and reported a frequency of 4% in that series.

Furthermore, the results of the current study were superior to that obtained by other maneuvers tried to overcome post-parotidectomy complications; Jost et al. (1999) proposed a procedure that combines displacement of the posterior belly of the digastric muscle, a flap with an upper pedicle taken from the sternocleidomastoid muscle and a double layer free graft, taken from the superficial and deep temporal fascias. This procedure seems complicated and time-consuming compared with the SMAS advancement flap. Han et al., (2004), found immediate transplantation of the stemocleidomastoid muscle-great auricular nerve flap can repair the depressed deformity of the parotid area and Asal et al., (2005), found reconstruction of the surgical defect after parotidectomy with a sternocleidomastoid muscle flap reduced the frequency

of Frey's syndrome and provided good aesthetic results compared to those without flap. However, these procedure despite the effectiveness was more aggressive, required more surgical dissections and surely more time-consuming. In addition no comment in both studies was provided on the effect of neck movement and long-term outcome.

Moreover, the applied maneuver spared the use of recently tried allogenic or synthetic grafts to fill the resultant defect with similar or better outcome; Curry et al., (2008), compared the outcome of elevation of the SMAS with or without fat graft interposition during superficial parotidectomy to prevent a concave facial deformity and Frey's syndrome and found simultaneous reconstruction of a superficial parotidectomy defect using SMAS elevation with or without fat grafting may improve postoperative facial symmetry and decrease the incidence of symptomatic Frey's syndrome without increasing complications. However, despite the benefits of fat grafting, resorption of dermal fat grafts was a problem and Cervelli et al.,

(2009) and Chandarana et al., (2009), found platelet-rich plasma favor maintenance and function of fat grafts are used to reconstruct facial contour defects in patients underwent plastic reconstructive surgery, possibly by stimulating adipose-tissue-derived stem cells proliferation. As regards synthetic grafts, Papadogeorgakis et al., (2009), found the use of porcine dermal collagen graft (Permacol) produced good results in both postoperative facial contouring and prevention of Frey's syndrome after operations on the parotid.

The advantage of the applied technique for abolishment of Frey's syndrome could be attributed to the fact that the SMAS flap used as a membrane guided tissue regeneration. Moreover, the SMAS flap seems to accelerate the nerve recovery, through provision of a supplementary blood flow inducing the formation of a capillary network around the ischaemic nerve, (Cesteley et al., 2002).

It could be concluded that the use of SMAS advancement flap fixed to the anterior margin of sternomastoid to cover the surgi-

cal raw area after parotidectomy is surgically feasible and effective surgical policy for minimizing the frequency of the development of Frey's syndrome and postoperative retromandibular dimpling and with high patients' satisfaction score and is advocated for surgical treatment of benign parotid lesions requiring superficial parotidectomy

### References

**Angspatt A., Yangyuen T., Jindarak S., Chokrungravanont P. and Siriwan P. (2004)** : The role of SMAS flap in preventing Frey's syndrome following standard superficial parotidectomy. *J Med Assoc Thai.*; 87(6):624-7.

**Asal K., Koybasioglu A., Inal E., Ural A., Uslu S. S., Ceylan A. and Ileri F. (2005)** : Sternocleidomastoid muscle flap reconstruction during parotidectomy to prevent Frey's syndrome and facial contour deformity. *Ear Nose Throat J.*; 84(3):173-6.

**Baek C. H., Chung M. K., Jeong H. S., Son Y. I., Jung S. C., Jeon H. K., Ryu N. G., Cho H. J., Cho J. K. and Jang J. Y. (2009)** :

Questionnaire evaluation of sequelae over 5 years after parotidectomy for benign diseases. *J Plast Reconstr Aesthet Surg*; 62 (5):633-8.

**Bisaccia E., Khan A. J. and Scarborough D. A. (2004)** : Anterior face-lift for correction of middle face aging utilizing a minimally invasive technique. *Dermatol Surg*; 30(5):769-76.

**Boynton J. F., Cohen B. E. and Barrera A. (2006)** : Rhytidectomy and parotidectomy combined in the same patient. *Aesthetic Plast Surg*; 30(1): 125-31.

**Carpintero H. N., Sainz G. C., Garcia C. M. and Virto Ruiz M. T. (2006)** : Frey's syndrome: report of three cases with two distinct etiopathogeneses. *An Pediatr (Barc)*; 64(6): 588-90.

**Cervelli V., Gentile P., Scioli M. G., Grimaldi M., Spagnoli L. G. and Orlandi A. (2009)** : Application of Platelet-rich Plasma to Fat Grafting during Plastic Surgical procedures: Clinical and In Vitro evaluation. *Tissue Eng Part C Methods*. Epub 2009 Feb .

**Cesteleyn L., Helman J., King S. and Van de Vyvere G. (2002)** : Temporoparietal fascia flaps and superficial musculoaponeurotic system placcation in parotid surgery reduces Frey's syndrome. *J Oral Maxillofac Surg* 60: 1284-97.

**Chandarana S., Fung K., Franklin J. H., Kotylak T., Matic D. B. and Yoo J. (2009)** : Effect of autologous platelet adhesives on dermal fat graft resorption following reconstruction of a superficial parotidectomy defect : a double-blinded prospective trial. *Head Neck*; 31(4):521-30.

**Curry J. M., Fisher K. W., Heffelfinger R. N., Rosen M. R., Keane W. M. and Pribitkin E. A. (2008)** : Superficial musculoaponeurotic system elevation and fat graft reconstruction after superficial parotidectomy. *Laryngoscope*; 118(2):210-5.

**Ghassemi A., Prescher A., Riediger D. and Axer H. (2003)** : Anatomy of the SMAS revisited. *Aesthetic Plast Surg*; 27(4): 258-64.



- Guntinas-Lichius O., Gabriel B. and Klusmann J. P. (2006) :** Risk of facial palsy and severe Frey's syndrome after conservative parotidectomy for benign disease: analysis of 610 operations. *Acta Otolaryngol.*; 126 (10): 1104-9.
- Han S. Y., Song T., Wang Y. X. and Wang X. K. (2004) :** Application the sternocleidomastoid muscle-great auricular nerve flap in radical parotidectomy. *Zhonghua Zheng Xing Wai Ke Za Zhi.*; 20(6):425-7.
- Henney S. E., Brown R. and Phillips D. E. (2009) :** Parotidectomy: the timing of post-operative complications. *Eur Arch Otorhinolaryngol.* Epub 2009 May 1.
- Honig J. F. (2004) :** Facelift approach with a hybrid SMAS rotation advancement flap in parotidectomy for prevention of scars and contour deficiency affecting the neck and sweat secretion of the cheek. *J Craniofac Surg.*;15 (5):797-803.
- Khawaja H. A. and Hernandez-Perez E. (2005) :** Transcutaneous face-lift. *Dermatol Surg.*; 31(4):453-7.
- Jost G., Guenon P. and Gentil S. (1999) :** Parotidectomy: a plastic approach. *Aesthetic Plast Surg* 23: 1-4.
- Luna-Ortiz K., Sanson-RioFrio J. A. and Mosqueda-Taylor A. (2004) :** Frey syndrome. A proposal for evaluating severity. *Oral Oncol.*; 40(5):501-5.
- Macchi V., Tiengo C., Porzionato A., Stecco C., Vigato E., Parenti A., Azzena B., Weiglein A., Mazzoleni F. and De Caro R. (2009) :** Histotopographic Study of the Fibroadipose Connective Cheek System. *Cells Tissues Organs.* Epub Jun 24.
- Meningaud J. P., Bertolus C. and Bertrand J. C. (2006) :** Parotidectomy: assessment of a surgical technique including facelift incision and SMAS advancement. *J Craniofac Surg.*; 34(1): 34-7.
- Mowlavi A. and Wilhelmi B. J. (2004) :** The extended SMAS

facelift: identifying the lateral zygomaticus major muscle border using bony anatomic landmarks. *Ann Plast Surg.*; 52 (4): 353-7.

**Nitzan D., Kronenberg J., Horowitz Z., Wolf M., Bedrin L., Chaushu G. and Talmi Y. P. (2004)** : Quality of life following parotidectomy for malignant and benign disease. *Plast Reconstr Surg.*; 114(5):1060-7.

**Papadogeorgakis N., Petsinis V., Christopoulos P., Mavrovouniotis N. and Alexandridis C. (2009)** : Use of a porcine dermal collagen graft (Permacol) in parotid surgery. *Br J Oral Maxillofac Surg.*; 47(5):378-81.

**Wang C. M., Nie J. Y. and Sheng H. M. (2006)** : Application of platysma flap in face lifting. *Zhonghua Zheng Xing Wai Ke Za Zhi.*; 22(4):292-4.

**Wormald R., Donnelly M. and Timon C. (2009)** : 'Minor' morbidity after parotid surgery via the modified Blair incision. *J Plast Reconstr Aesthet Surg.*; 62(8):1008-11.

**Yu G. Y. (2001)** : Superficial parotidectomy through retrograde facial nerve dissection. *J. R. Coll. Surg. Edinb.*; 46: 104-7.

**Zhao H. W., Li L. J., Han B., Liu H. and Pan J. (2005)** : A retrospective study on the complications after modified parotidectomy in benign tumors of parotid gland. *Hua Xi Kou Qiang Yi Xue Za Zhi.*; 23(1):53-6.

**Zhi K. Q., Deng P. F., Ren W. H., Zhang L., Li X. Q. and Wen Y. M. (2008)** : A clinical retrospective study on modified parotidectomy in benign tumors of parotid gland. *Shanghai Kou Qiang Yi Xue.*;17(3):229-32.

REPRINT

# **BENHA MEDICAL JOURNAL**

**SURGICAL FEASIBILITY AND  
OUTCOME OF SUPERFICIAL  
MUSCULOAPONEUROTIC SYSTEM  
(SMAS) ADVANCEMENT FLAP FOR  
PAROTID BED COVERAGE AFTER  
SUPERFICIAL PAROTIDECTOMY**

**Mahmoud M. Algamal MD, Emad Abdel Hafez MD,  
Kassem M Kassem MD and Abou-Bakr E. Ras MD**

**Published by  
Benha Faculty of Medicine**

*Volume 26 Number 3  
Sept. 2009*

**LIVE-BIRTH RATE FOLLOWING  
METFORMIN MONO-THERAPY IN MONOCYCLE  
ANOVULATORY YEMENI INFERTILE WOMEN  
WITH POLYCYSTIC OVARIAN  
SYNDROME (PCOS)**

**Allow A. Kaid Ph.D, Rashed A. A Thabet Ph.D\*\*,  
Saeed M. Saeed Ph.D\* and Bracamonte M. Allow Msc.**

*Departments of Human reproductive physiology , Histology\* and Basic Sciences\*\*  
Colleague of Medicine and Health Sciences, Sana'a University, Egypt*

**Abstract**

*Background: There are few data in the literature regarding the utility of metformin before involvement of women with PCOS in assisted reproductive techniques. In our country it is the first academic prospective systemic study to assess the effect of metformin mono-therapy in Yemeni infertile PCOS women on ovulation, pregnancy, live-birth and early pregnancy loss rates. Patients and Methods: One hundred eighty two Yemeni infertile women aged between 21 and 35 years were diagnosed as infertile women with PSOS according to the Rotterdam ESHRE/ASRM-Sponsored PCOS Consensus Workshop Group in 2003. These anovulatory infertile Yemeni women were attending 'Allow Medical IVF Center' for treatment of infertility. Design: clinical prospective controlled study. Setting: The study was conducted at the Allow Medical IVF Center, Unit of Human Reproductive Physiology, Colleague of Medicine and Health Sciences, Sana'a University, Republic of Yemen. Duration: from July 2005 to September 2008. All patients were divided into two groups. Group-I metformin treated group (n = 139) and control group - PSOS without metformin therapy (n = 43). Outcomes: ovulation, pregnancy, early abortion and live-birth rates. Results: No significance differences between all baseline parameters of study groups. Following 12 weeks of treatment by metformin (group-I) the ovulation rate was 39.57% (55/139) vs. to 16.28% (7/43) in the group-II without metformin (P<0.001). In study group-I 28/55 (50.91%) get normal ongoing pregnancies vs. to group-II 3/43 (6.98%), (P<0.002). The live-birth rate was 89.29% (25/28 or 17.99%, 25/139) in*

*metformin treated women compare to 1/7 (14.29% or 2.33%, 1/43) in group-II (P<0.002). The early abortion rate was significantly higher (P<0.001) in group-II in compare to group-I (1/43, 4.65% vs. 3/139, 2.16%, respectively). No congenital abnormalities were found in all born babies. Conclusion: metformin therapy for women with PSOS could be used as a first line drug for treatment of anovulatory PCOS infertile women. It increases ovulation, pregnancy, and live-birth rates and decrease rate of early pregnancy loss. In addition, it is safe to use during pregnancy and congenital abnormality and ectopic pregnancies were not observed.*

**Key words:** *metformin, live-birth rate, Yemeni, PCOS, infertile.*

### **Introduction**

Anovulation is the cause of about 40% of all female infertility that appears usually as a result of PCOS (The Rotterdam ESHRE / ASRM, 2004). Polycystic ovary syndrome is affected about 5-10% of reproductive women (Hardiman and Atiomo, 2003), and has recently become clear that PCOS is also linked to a number of metabolic disturbances, including type 2 (non-insulin-dependent) diabetes mellitus (especially by the age of 40 (Fleming et al., 2002)), so PCOS is an important health concern and may represent a major health issue affecting young reproductive women today ( Dvalle and Azziz, 2002). Metformin is biguanide insulin sensitizing agent traditionally used in the management of type 2 diabetes mellitus

and led to decrease intestinal absorption of glucose, decrease hepatic glucose production, improve peripheral insulin sensitivity, and weight loss has been noted in some women ( Brock et al., 2005).

We are postulated that the use of metformin in Yemeni infertile women with PCOS for appropriate period of time (12 weeks) may improve the endocrine milieu which leads to menstrual cyclicality and mono-ovulation. Thus, the aim of the current clinical prospective systemic controlled study is to explore the potential additional effect of metformin mono-therapy on ovulation, pregnancy, and live-birth rates in Yemeni infertile women with PCOS attending our 'Allow Medical IVF Center' for treatment of infertility.

### **Patients and Methods**

**Patients:** One hundred eighty two Yemeni infertile women aged between 21 and 35 years were diagnosed as infertile women with PSOS according to the Rotterdam ESHRE/ASRM-Sponsored PCOS Consensus Workshop Group in 2003. These anovulatory infertile Yemeni women were attending 'Allow Medical IVF Center' for treatment of infertility due to anovulation. The institutional review board at Colleague of Medicine, Sana'a University approved the protocol, and all women gave written informed consent. Design: clinical prospective systemic controlled study. Duration: the duration of this study was from July 2005 to September 2008. Exclusion criteria for all subjects included: age <20 or >35 years; body mass index (BMI) >30 and <18 kg/m<sup>2</sup>; neoplastic, metabolic (including glucose intolerance), hepatic, and cardiovascular disorder or other concurrent medical illness; hypothyroidism; hyperprolactinaemia; Cushing's syndrome; non-classical congenital adrenal hyperplasia; current abuse of alcohol and Qat chewing; use of oral contraceptives, glucocorticoids,

antiandrogens, antidiabetic, and anti-obesity and hormonal drugs. Other exclusion criteria were: organic pelvic diseases, previous pelvic surgery, suspected peritoneal factor infertility, tubal or male factor infertility. Tubal and male factor infertility were excluded with a hysterosalpingogram and with semen analysis, respectively. We also excluded women who intended to start a diet or a specific programme of physical activity. All subjects had a normal physical activity. Grouping of PSOS women. All patients were divided into two PSOS infertile groups. Group-I metformin treated group (n = 139) and control group-PSOS without metformin therapy (n = 43). **Outcomes:** ovulation, pregnancy, early pregnancy loss, and live-birth rates.

**Study Drugs:** In the present study for women Group-I was used film coated tablets containing 1000mg of metformin hydrochloride (equivalent to 780mg metformin base, Glucophage® 1000, Merck Sante, Lyon, France), 1000-2000 mg / day increasing gradually. The side effects of the metformin were discussed with

patients before starting the treatment and vitamin-B12 supplementation was done to avoid complication of metformin (1tab./Day). The course of metformin treatment was started from menstrual day 2 and continued for at least 12 weeks and continued during pregnancy. Patients discontinued the metformin treatment for any reason was excluded from this study. In subjects without recent menses, withdrawal bleeding was induced with a course of oral medroxyprogesterone acetate before the initiation of study medication. Group-II was observed for 12 weeks without ant treatment. Vitamins B were administrated one tablet alternative 2 days. In pregnant women Glucophage had been continued during pregnancy which additionally given us a new and very important information about the effect of Glucophage in the development of fetus intrauterinely.

**Monitoring of patients:** Baseline investigation of sex hormones was recorded for all patients. Serial transvaginal ultrasound was documented for all women before and during therapy for 12 weeks.

At the cycle day 21 progesterone and prolactin were also recorded for all women. The ovulation was performed by injection of 5000-10000 IU of human chorionic gonadotropin intramuscular when we found mature follicle size more than or = to 17mm. programming intercourse were recommended for all patients with good ovulation. Ovulation, ongoing clinical pregnancy, live-birth, and early abortion rates were calculated and studied during the duration of this study.

**Statistical Evaluation:** Data were analyzed with in built functions within the Statistical Package for Social Science (SPSS UK Ltd, version 7.5 : 2000, Chertsey, Surrey, United Kingdom). The statistical tests used depend on the nature of the data. In addition to the standard statistical methods to determine the mean, standard deviation we used student's t-test and multiple analysis of variances (MANOVA) to report the level of statistical significance between the means and correlation test. Differences were considered statistically significant at  $P \leq 0.05$ .

### Results

The data of patients involved in the present study is demonstrated in table 1. No significance differences between baseline variables among the study groups (table 1).

The sub-grouping of women group-I and group-II depending on the age factor is demonstrated in the figure 1 and 2 respectively. In the group-I about 38% (53/139) of infertile Yemeni women with PSOS have been age between 26-30 years, 30% have age less than 26 years old (42/139) and 32% (44/139) have more than 31-35 years old (figure 1).

In group-II 40% (17/43) of Yemeni infertile women with PCOS is presented in younger women (21-25 years) figure 2. No significant differences between all age groups of the present study.

Over the course of the study, the ovulation rate was 39.57% (55/139) in metformin treated PCOS Yemeni infertile women in compare to 16.28% (7/43) in the women of group-II ( $P<0.001$ , figure 3). During the course of this study which delayed around 38 months

28 women of 55 ovulated women group-I became pregnant (50.91% or 20.14%, 28/139) .

Versus group-II 6.98%, 3/43 ( $P<0.002$ ), figure 3. The pregnancy was certified chemically by measurement of beta human chorionic gonadotropin and progesterone levels 14 days at the day of ovulation. The clinical ongoing pregnancies were documented by presence of gestational sac by transvaginal ultrasonography. Luteal support was recommended for all clinically diagnosed pregnant women.

Highly significant differences ( $P<0.001$ ) were obtained in the early trimester abortion rate in both studied groups (Group-II 2/43, 4.65% vs. group-I 3/139, 2.16%, figure 4). The live-birth rate was in group-I 25/28 (89.29% or 25/139, 17.99%) in compare to group-II 1/3 (33.33% or 1/43, 2.33%,  $P<0.002$ ) figure 4.

All women who early aborted had been irregularly taken luteal support and were out of our control when they get pregnant. No congenital abnormalities were



observed in all babies of delivered women in present work. No multiple and ectopic pregnancies occurred in all pregnant women. Gastrointestinal symptoms were more frequent in the group-I receiving metformin and absent in women group-II. The rates of compliance with the recommended frequency of programming sexual intercourse ranged from 82 to 85% at the first visit and declined to 62

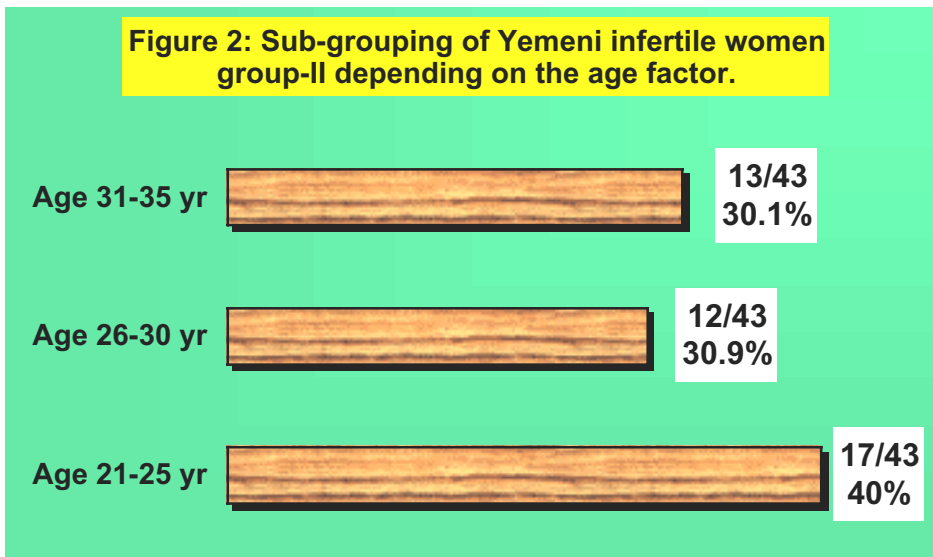
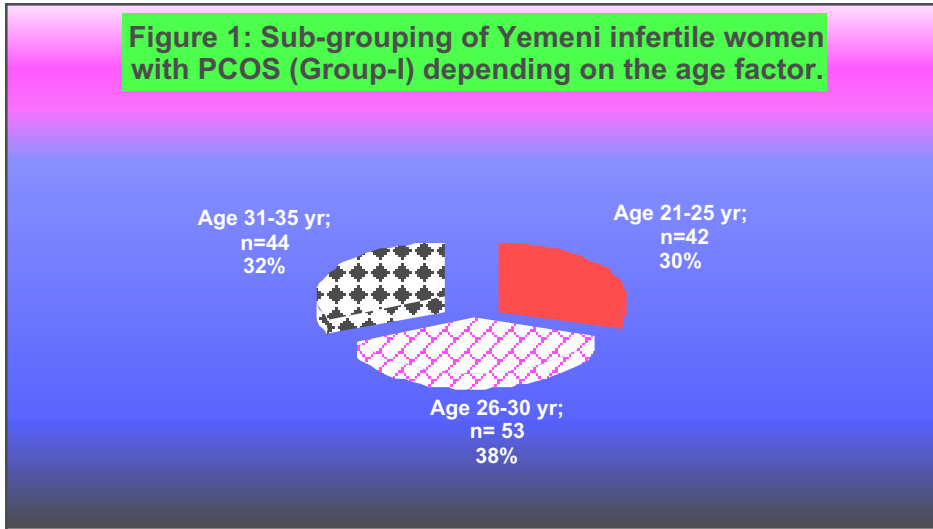
to 71% at the visit at 3 months. The compliance rates were similar across both study groups at all cycles (P<0.13).

Bad-responder patients were involved in the program of assisted reproductive techniques or induction of ovulation by gonadotropins and their results will be published later in separated papers.

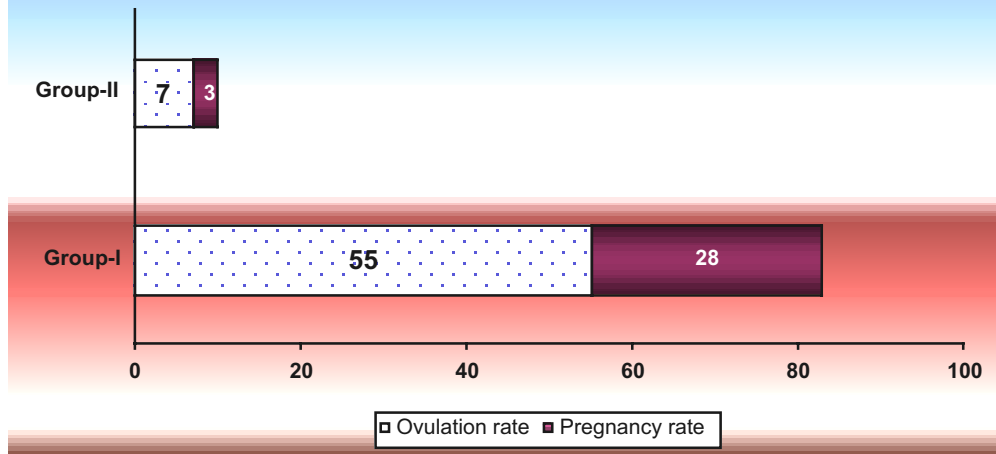
**Table 1:** Data of Yemeni infertile women with PCOS who were involved in the present study and performed metformin therapy (group-I, n=139) and infertile women without metformin therapy (group-II, n=43).

Variables	Group-I *	Group-II *	P value
Age (years)	28.82 ± 6.20	26.36 ± 5.61	NS
BMI-Body Mass Index (Kg/m <sup>2</sup> )	26.44 ± 3.12	26.24 ± 3.31	NS
Duration of infertility	6.13 ± 2.79	7.47 ± 3.11	NS
Type of infertility	All primary	All primary	--
Previous exposure to study drugs	0%	0%	--
Baseline right ovarian volume (cm <sup>3</sup> )	10.37 ± 4.81	10.92 ± 5.22	NS
Baseline left ovarian volume (cm <sup>3</sup> )	11.25 ± 3.63	11.54 ± 4.01	NS
Base line Estrodirole level (IU/ml)	63.29 ± 33.81	58.12 ± 27.46	NS
Base line LH (IU/ml)	13.94 ± 3.71	12.48 ± 2.25	NS
Base line FSH (IU/ml)	9.48 ± 5.73	7.71 ± 4.26	NS
Base line LH/FSH ratio	1.94 ± 0.68	1.57 ± 0.62	NS
Progesterone level at the CD 21 - natural cycle (pg/dl)	1.36 ± 1.61	1.23 ± 1.32	NS
Prolactin at the CD 21 - natural cycle (pg/dl)	12.16 ± 2.38	13.27 ± 1.16	NS
Base line Testosterone (IU/ml)	1.02 ± 0.47	0.9 ± 0.31	NS
Base line level HbA <sub>1c</sub> level	4.26 ± 1.36	4.31 ± 2.20	NS

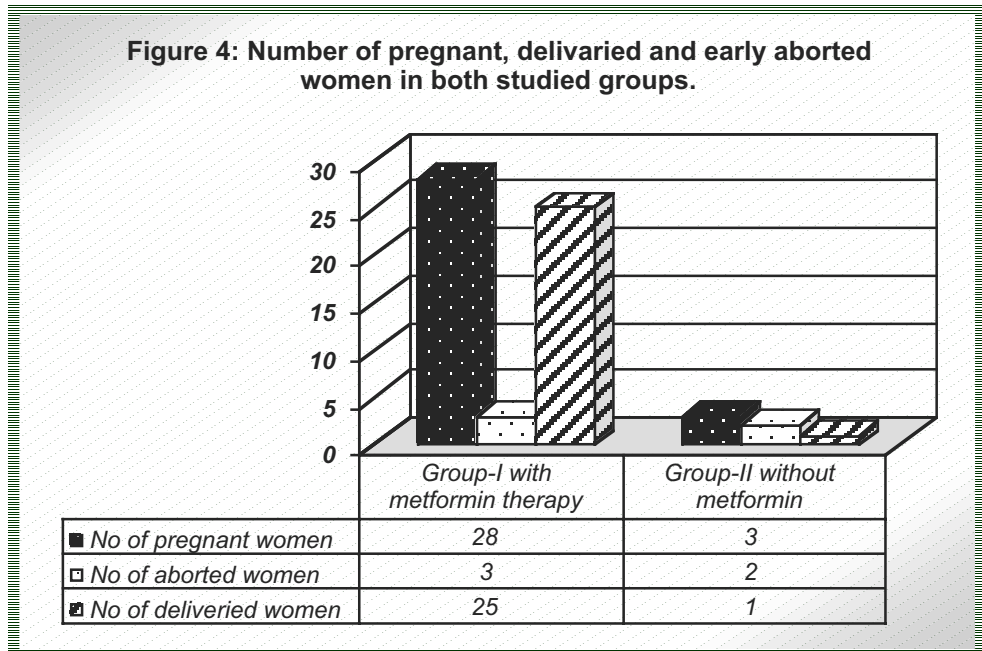
CD-cycle day; P-probability; NS- no significant differences.  
 \* All values are mean ± stander error of mean



**Figure 3: Number of ovulated and pregnant women in both studying groups.**



**Figure 4: Number of pregnant, delivered and early aborted women in both studied groups.**



### **Discussion**

To our knowledge, this is the first clinical prospective controlled trial of sufficient patient number to address the issue of efficacy of metformin mono-therapy in the treatment of infertility due to anovulation in Yemeni infertile women with PCOS. The results of the present work were not observed significant differences between the baseline variables of both studied groups.

The present study demonstrates that 3 months (12 weeks) of metformin therapy at 1500 mg/day, was associated with 1) improvement of ovarian responsiveness and good ovulation rate in these women who suffered from anovulatory cycles, 2) improvement in pregnancy rate, 3) lowering of early abortion rate, 4) increasing of live-birth rate in metformin treated infertile women with PCOS, and 5) this type of treatment was not expensive for our people who suffered from a lot of economical and financial problems and there no absolute indication to start any type of assisted reproductive techniques for our patients which involved in this

work. We didn't add clomiphine citrate for induction of ovulation in all women which involved in the present study because our experience found no advantage to add it with metformin therapy and we have been tried to point the benefits of metformin therapy alone in infertile women with PCOS. These findings are in good agreement with reports published by Moll et. al., (2006) and Legro et. al., (2007). We believe that metformin therapy facilitates ability of ovarian metabolism by increase ovarian insulin receptors and reproduce mature follicles.

An improvement in the folliculogenesis was associated with the action of metformin which lead to increase insulin receptors overall the body includes ovaries. Eisenhardt et. al., in (2006) reported that in insulin-resistant women, insulin sensitivity was improved as early as within 4 weeks of treatment. Interestingly, although improvements of insulin sensitivity in this group were moderate, effects of metformin on menstrual cyclicity were striking. The main outcome criterion menstrual disturbance was successfully

improved only in the metformin group without effect under placebo and restricted to insulin-resistant women, whereas women without insulin resistance failed to benefit significantly (Eisenhardt et al., 2006).

The same observation was observed by Kjøtroed and his co-workers that metformin therapy for at least 16 weeks in women with PCOS (1500-2000 mg daily) before they commenced IVF cycles have been successfully used in the management of various problems related to PCOS. Folliculogenesis is restored in up to 70% of women and ovulatory cycles are restored in approximately 50%. The use of insulin-sensitizing drugs often results in successful stimulation in women who previously displayed resistance to clomiphene (Kjøtroed et al., 2004).

In accordance to short-term findings of Nestler et al., 1998 [10], biphasic basal body temperature curve assessment in women who experienced regular menses after metformin showed that most cycles became ovulatory. Spontaneous ovulation can occur rapidly,

and normal menstrual rhythm can be achieved within 3 months of metformin treatment (Nestler et al., 1998, Pasquali et al., 2000). Those findings are documented in our study.

In accordance to results reported by Eisenhardt et al., (2006) several studies show that the ovulation rate increased with no changes in weight, suggesting that the effect is independent of weight loss (Azziz, 2003 & Solomon et al., 2001). Fleming et al., (2002) have recently shown the mean time until the first ovulation to be significantly shorter in the metformin-treated group (Ng et al., 2001) than the placebo-treated group (Quon, 2001). This suggests a rather rapid effect of metformin treatment upon ovarian and ovulatory function, which is further supported by the finding that the significant increase in estradiol concentrations was found already in the first week of treatment when the metformin dosage was restricted to only 850 mg/day. Interestingly no changes in the circulating inhibin-B or -T concentrations could be found suggesting that despite of improved follicular

maturation there appeared to be no changes in the remainder of ovarian metabolism (total immature granulosa cell activity and stromal androgen biosynthesis) (Eisenhardt et. al., 2006).

The high ovulation rate 40% which obtained in our study as a result of metformin is also agrees with that reported by Harborne et.al. (Harborne et al. , 2003) who were found ovulation rate 67% in metformin treated PCOS women. The high ovulation rate which recorded by Eisenhardt et al., (2006) might associated with low number of women 45 compare to 139 PCOS women which treated in our study as well as age of women studied by Eisenhardt et al., (2006) are not established i.e. they may involved only selected cases but both studies are documented an improvement in the ovarian functions include folliculogenesis which already associated with an increase in the estradiol levels continuously every 4 weeks with statistical evidence only in the metformin group indicating an improvement of ovarian function (Eisenhardt et. al., 2006).

The high clinical ongoing pregnancy (51%, 28/55 or 20%, 28/139) and high live-birth rates (89%, 25/28 or 17.99%, 25/139) in metformin treated Yemeni infertile women with PCOS in compare to group-II (3/43, 6.99% and 1/3, 33.33% or 1/43, 2.33%, respectively,  $P < 0.002$ ) that recorded in our study is in a good agreement with that study reported by Moll and their co-workers in 2007 (Moll et al., 2007) and (Harborne et al., 2003 & Kashyap et al., 2004 & Palomba et al., 2005). The live-birth rate was 7.2% (15 of 208) in the metformin group (Legro et al., 2007) which was lower than that reported in our present study. We are agree with the interpretation that was reported by Legro et.al., (2007) who found that the group receiving metformin (both the metformin group and the combination-therapy group) had improved insulin sensitivity (including effects on BMI, proinsulin and insulin levels, and insulin resistance as determined by homeostasis model assessment-HOMA), as compared with the clomiphene group. However, these effects did not translate into increased live-birth rates. Instead, increases in

sex hormone-binding globulin levels were associated with improved live-birth rates (Legro et al., 2007).

Our results are inconsistent with data from several other studies reporting benefits of metformin for stimulation of ovulation in women with PCOS (Palomba et al., 2005 & Vandermolen et al., 2001 & Sahin et al., 2004). Previous data have generally come from small, primarily single-center trials (Legro and Myers, 2004 & Lord et al., 2003) that did not assess pregnancy rates but rather focused on metabolic and hormonal measures, rates of ovulation, or both (Lord et al., 2003). In contrast to our results, levels of fecundity improved over time among subjects receiving metformin, as compared with clomiphene that reported by Legro et al., (2007).

The early pregnancy loss among subjects who conceived in our treated group-I due to treatment by metformin was 3/28 (10.72%) compare to 2/7 (28.57%) in non-treated women by metformin. We confirm that these positive findings are associated with

benefits of metformin in women with PCOS. Legro et al., (2007) had been reported high early pregnancy loss 40% (10/25) in compare to our study. This difference might be associated with BMI of PCOS women that involved in our and their studies ( $26.44 \pm 3.12$  vs.  $35.6 \pm 8.5$ , respectively).

The additional effects of metformin mono-therapy in women with PCOS had been reported by Romualdi et al., (2008) who confirmed the positive effects of metformin on the altered vascular reactivity in normoinsulinemic PCOS subjects. This improvement seems to be mediated through hormonal changes, thus highlighting the detrimental role of hyperandrogenemia on the endothelial function, even beyond the metabolic factors. However, a direct effect of metformin on the endothelium should not be excluded (Romualdi et al., 2008). Furthermore, Nestler in, (2008) reported that metformin improves insulin sensitivity and, as noted earlier, has been shown to retard or prevent progression to type 2 diabetes in patients with impaired glucose tolerance. Although metformin has not been

specifically shown to reduce the risk of cardiovascular events in patients with the PCOS, the available mechanistic and clinical evidence support the use of metformin as a protective measure against the adverse cardiovascular effects of insulin resistance and insulin excess. In addition, metformin may decrease circulating androgen levels and may improve ovulation and menstrual cyclicity, thus addressing the traditional goals of long-term treatment (Nesler, 2008).

**In conclusion:** we believe that the benefits of metformin monotherapy in mono-cycle anovulatory Yemeni infertile women with PCOS were the cornerstone to improve functions of their ovaries which finally resulted in high pregnancy and high live-birth rates when compared to Yemeni infertile PCOS women who didn't treated by metformin. Moreover, the additional effect of metformin was that babies who born in our study were also healthy and no ectopic and multiple pregnancies observed, too. Finally, we clear the benefits of metformin in infertile women with PCOS but we also suggest

further observations and studies needed to obtain the optimal dose of metformin during pregnancy.

### References

**Azziz R., (2003):** Androgen excess is the key element in polycystic ovary syndrome. *Fertil Steril.* 80: p. 252-254.

**Brock, B. (2005) :** Is metformin therapy for polycystic ovary syndrome safe during pregnancy? *Basic Clin Pharmacol Toxicol*, 96 (6): p. 410-412.

**Costello M. F., C. M. and Conway U. A. (2006) :** Systematic review and meta-analysis of randomized controlled trials on metformin co-administration during gonadotrophin ovulation induction or IVF in women with polycystic ovary syndrome. *Hum Reprod.*, 21: p. 1387-1399.

**Eisenhardt S., S. N., Henschel V., Germeyer A., von Wolff M., Hamann A. and Strowitzki T., (2006) :** Early Effects of Metformin in Women with Polycystic Ovary Syndrome: A Prospective Randomized, Double-Blind, Placebo-Controlled Trial *Clinical Endo-*



crinology & Metabolism. 91, No. 3 p. 946-952.

**Fleming R., H. Z., Wallace A. M., Greer I. A. and Sattar N. (2002)** : Ovarian function and metabolic factors in women with oligomenorrhea treated with metformin in a randomized double blind placebo-controlled trial. *J Clin Endocrinol Metab.*, 87 : p. 569-574.

**Harborne L., F. R., Lyall H., Sattar N. and Norman J. (2003)** : Metformin or antiandrogen in the treatment of hirsutism in polycystic ovary syndrome. *J Clin Endocrinol Metab.* 88: p. 4116-4123.

**Hardiman P., P. O., Atiomo W. (2003)** : Polycystic ovary syndrome and endometrial carcinoma. *Lancet.* 361 : p. 1810-1812.

**Johnson N. P. (2006)** : No more surrogate end-points in randomised trial: the PCOSMIC trial protocol for women with polycystic ovary syndrome using metformin for infertility with clomiphene. *Aust N Z J Obstet Gynaecol.* 46: p. 141-145.

**Kashyap S., W. G., Rosenwaks Z. (2004)** : Insulin-sensitizing agents as primary therapy for patients with polycystic ovarian syndrome. *Hum Reprod. Hum Reprod.*, 19: p. 2474-2483.

**Kjotrod S. B., V.D.V., Carlsen S. M. (2004)** : Metformin Treatment Before IVF/ICSI in Women With Polycystic Ovary Syndrome; A Prospective, Randomized, Double Blind Study. *Human Reproduction.* 19(6): p. 1315-1322.

**Kocak M., C. E., Simsir C. and Haberal A. (2002)** : Metformin therapy improves ovulatory rates, cervical scores, and pregnancy rates in clomiphene citrate-resistant women with polycystic ovary syndrome. *Fertil Steril.* 77:: p. 101-106.

**Legro R. S., K. A. and Dunaif A.,(2001)** : Prevalence and predictors of dyslipidemia in women with polycystic ovary syndrome. *Am J Med.* 111: p. 607-613.

**Legro R. S. and Myers E. (2004)** : Surrogate end-points or primary outcomes in clinical trials in women with polycystic ovary

syndrome?. Hum Reprod. 19: p. 1697-1704.

**Legro R. S., Z. R., Demers L. M., Kunselman A. R., Gnatuk C. L., Williams N. I. and Dodson W. C. (2007)** : The effects of metformin and rosiglitazone, alone and in combination, on the ovary and endometrium in polycystic ovary syndrome. Am J Obstet Gynecol. 196-b: p. 402-410.

**Legro R. S., B. H. X., Schlaff W. D., Carr B. R., Diamond M. P., Carson S. A., Steinkampf M. P., Coutifaris C., McGovern P. G., Cataldo N. A., Gosman G., Nestler J., Giudice L. C., Lepert P. C. and Myers E. R. (2007)** : (Cooperative Multicenter Reproductive Medicine Network), Clomiphene, Metformin, or Both for Infertility in the Polycystic Ovary Syndrome. N Engl J Med., 356(6): p. 551-566.

**Lord J. M., F. I. and Norman R. J. (2003)**: Metformin in polycystic ovary syndrome: systematic review and meta-analysis. BMJ. 327: p. 951-953. .

**Moll E, B.P., Korevaar JC,**

**Lambalk C. B. and Veen van der F. (2006)** : Effect of clomifene citrate plus metformin and clomifene citrate plus placebo on induction of ovulation in women with newly diagnosed polycystic ovary syndrome: randomised double blind clinical trial. BMJ. 332: p. 1485.

**Moll E., F. van der Veen and M. van Wely (2007)** : The role of metformin in polycystic ovary syndrome: a systematic review. Hum Reprod Update., 13(6): p. 527-37.

**Nestler J.E. (2008)** : Metformin for the Treatment of the Polycystic Ovary Syndrome. N Engl J Med. 358: p. 47-54.

**Nestler J. E, J. D., Evans W. S. and Pasquali R. (1998)** : Effects of metformin on spontaneous and clomiphene-induced ovulation in the polycystic ovary syndrome. N Engl J Med. 338: p. 1876-1880.

**Ng E. H., W. N. and Ho P. C. (2001)** : Effects of metformin on ovulation rate, hormonal and metabolic profiles in women with clomiphene-resistant polycystic ovaries: a randomized, double-blinded placebo-controlled trial.

Hum Reprod. 16: p. 1625–1631.

**Norman R. J. (2004)** : Metformin–comparison with other therapies in ovulation induction in polycystic ovary syndrome. *J Clin Endocrinol Metab.* 89 : p. 4797-4800.

**Ovalle F. and Azziz R. (2002)** : Insulin resistance, polycystic ovary syndrome, and type 2 diabetes mellitus. *Fertil Steril* 77: 1095-1105. 77: p. 1095-1105.

**Pasquali R., G. A., Biscotti D., Vicennati V., Gagliardi L., Colitta D., Fiorini S., Cognigni G. E., Filicori M. and Morselli-Labate A. M. (2000)** : Effect of long-term treatment with metformin added to hypocaloric diet on body composition, fat distribution, and androgen and insulin levels in abdominally obese women with and without the polycystic ovary syndrome. *J. Clin Endocrinol Metab.* 85: p. 2767-2774.

**Palomba S. (2005)** : Prospective parallel randomized, double-blind, double-dummy controlled clinical trial comparing clomiphene citrate and metformin as

the first-line treatment for ovulation induction in nonobese anovulatory women with polycystic ovary syndrome. *J Clin Endocrinol Metab.* 90(7): p. 4068-74.

**Quon M. J. (2001)** : Limitations of the fasting glucose to insulin ratio as an index of insulin sensitivity. *J Clin Endocrinol Metab.* 86: p. 4615-4617.

**Romualdi D., B. C., L. Selvaggi, M. Giuliani, F. Cristello, F. Macri, A. Bompiani, A. Lanzone and M. Guido (2008)** : Metformin improves endothelial function in normoinsulinemic PCOS patients: a new prospective. *Hum Reprod.* 23(9): p. 2127-2133.

**Sahin Y., Y. U., Kelestimur F. and Aygen E. (2004)** : The effects of metformin on insulin resistance, clomiphene-induced ovulation and pregnancy rates in women with polycystic ovary syndrome. *Eur J Obstet Gynecol Reprod Biol.* 113:: p. 214-220.

**Solomon C. G., H. F., Dunaif A., Rich-Edwards J., Willett W. C., Hunter D. J., Colditz G. A., Speizer F. E. and Manson J. E.,**

**(2001):** Long or highly irregular menstrual cycles as a marker for risk of type 2 diabetes mellitus. . JAMA. 286: p. 2421-2426.

**The Rotterdam ESHRE/ASRM-Sponsored PCOS Consensus Workshop Group. (2004) :** Revised 2003 consensus on diagnostic criteria and long-term health risks related to polycystic ovary syndrome. Fertil Steril.

81: p. 19-25.

**Vandermolen D. T., R. V., Evans W. S., Stovall D. W., Kauma S. W. and Nestler J. E. (2001):** Metformin increases the ovulatory rate and pregnancy rate from clomiphene citrate in patients with polycystic ovary syndrome who are resistant to clomiphene citrate alone. Fertil. Steril. 75: p. 310-315.

REPRINT

# **BENHA MEDICAL JOURNAL**

**LIVE-BIRTH RATE FOLLOWING  
METFORMIN MONO-THERAPY IN  
MONOCYCLE ANOVULATORY YEMENI  
INFERTILE WOMEN WITH  
POLYCYSTIC OVARIAN  
SYNDROME (PCOS).**

**Allow A. Kaid Ph.D, Rashed A. A Thabet Ph.D\*\*,  
Saeed M. Saeed Ph.D\* and Bracamonte M. Allow Msc.**

**Published by  
Benha Faculty of Medicine**

*Volume 26 Number 3  
Sept. 2009*

**IS ANTISPERM ANTIBODIES LAB  
INVESTIGATION TECHNIQUE NECESSARY AS  
A ROUTINE EXAMINATION FOR DIAGNOSIS  
OF IMMUNOINFERTILITY?**

**Allow A. Kaid Ph.D, Rashad A. A. Thabet Ph.D\*,  
Saeed M. Saeed Ph.D\*\*; Bracamonte M. Allow MSc.  
Almuhia E. Numan\*\*\* and Albarzanchi M. Taib Ph.D\*\*\*\***

*Departments of Human Reporodutive Phsiology , Histology\* ,  
Basic Sciences \*\* and Physiology & Pharmacology\*\*\*  
Colleague of Medicine and Health Sciences ,  
Sana'a University and Texas A & M University, USA \*\*\**

**Abstract**

*Background: One of the important causes of immunoinfertility is most probably antisperm antibodies (ASAs). Nonspecific seminal fluid infection might be the cause of ASAs. The percentage of sperm agglutination (SA) as well as sperm shaky head movement (SSM) also plays an important role in the process of ASAs. Objectives: 1) to evaluate the influence of immunoinfertility factors that is associated with formation of SA and SSM among Yemeni infertile couples. 2) The necessity of including fresh microslide SA and SSM lab techniques as a routine clinical lab tests for diagnosis of infertility. Design: prospective comparative study. Patients: two hundred thirty five infertile couples attending Allow Medical IVF (in vitro fertilization) Center ( colleague of medicine , Sana'a University ) , for infertility treatment were involved in the present study in the period from August 2005 to October 2007. All these couples were divided into two groups (group-I: 165 infertile men = have sperm agglutination > 10% and group-II: 70 infertile men with sperm agglutination 0-10%). Sera of the male were collected for measurement of ASA concentration. Main outcome: SA, SSM, sera ASAs titer in all couples. Results: Orchitis, chronic epididymitis, and sterile seminal fluid infection were highly significant in infertile patients with high sperm agglutination > 10% in group I compare to group II (12/165 (7.3%) and 1/70 (1.4%); 29/165 (17.6%) and 3/70 (4.3%); 31/165 (18.8%) and 8/70 (11.4%), respectively,  $P < 0.003$ ). A posi-*

*tive correlation between concentration of ASAs and SSM as well as percentage of SA was noted (n = 235, r = 0.738, P<0.0001). A further positive correlations was observed between ASAs and sterile seminal fluid infection (n=165, r=0.692, P<0.01). Conclusion: The prevalence of immunoinfertility factors among Yemeni infertile patients report more than 63% of causes mainly due to sterile seminal fluid infection, chronic epididymitis and orchitis. We confidently recommend the use of these so simple useful, accessible, and reliable lab tests as a routine investigation for diagnosis of high titer of ASAs as well as immunoinfertility and this should be considered seriously.*

**Key words:** ASAs, sperm agglutination, immunoinfertility, Yemeni infertile couples.

### **Introduction**

Conception is normally achieved within twelve months in 80-85% of couples who use no contraceptive measures and persons presenting after this time should therefore be regarded as possibly infertile and should be evaluated. Immunologic factors are considered as important causes of infertility (Berek and Novak , 2007). One of the immunologic factors proposed for infertility ( $\approx$ 20% of all causes of infertility) is presence of SA, ASAs in sera of infertile men and women, seminal plasma, cervical mucus, and follicular fluids (Berek and Novak, 2007 & Karimi, et al ., 2008)

Rumke (1954) and Wilson (1954) were the first to report the

presence of ASAs in infertile men. Now ASAs are defined as immunoglobulines (Ig) of the IgG, IgA and/or IgM class that are located to various sites of the spermatozoa (head, tail, midpiece or combination thereof) (Karimi, et al., 2008). The incidence of sperm agglutination due to autoimmunity in infertile couples is 9-36% in contrast to 0.9-4% in the fertile population. The incidence of detection of ASAs in the fertile male is 8-21% and in the female 6-23%. Immunological cause may contribute to 5-15% of the male infertility factors (Marshburn, 1997). It was reported that immunologic infertility is possible if more than 50% sperm are bound to IgG or IgA antibodies and it may be suspected if more than 10% spermatozoa are anti-

body bound. An un-symptomatic immune response to certain tissues of the reproductive system can cause infertility (Marshburn, 1997 and Allow , 2000,) .

Furthermore, presence of ASAs in the female reproductive tract can prevent their motility through the female reproductive tract or prevent the process of fertilization (Koide and Kamada , 2002 and Karimi, et al., 2008) and decrease the cleavage rate in patients with high titer of ASAs following IVF (Tian et al., 1999).

Finally, all these immunoinfertility factors that lead to the development of SA and ASAs among Yemeni infertile patients are prevailing and are yet to be evaluated, thus enabling us to take the necessary measures of prevention and treatment. On the other side, SA and ASAs lab tests are still subjects of debate and there is a lack of consensus on clinical consequences of ASAs. We hope our present study will define the importance of SA, SSM and ASAs screening in the process of diagnosis of immunoinfertility and their relationship with infertility by in-

volving large number of infertile patients with high percentage of SA (agglutination without seminal fluid infection), and high ASAs in their semen and sera and long duration of this study. Furthermore, in all Yemeni labs (governmental and private) the seminal fluid reports do not include percentage and types of SA, percentage of SSM and ASAs tests as a routine test for diagnosis of immunoinfertility. All these problems give us strong impetus to study them thoroughly. So, the present study is aimed to:

- \* Evaluate "firstly" the influence of immunoinfertility factors that are associated with formation of sperm agglutination, shaky movement of sperms and ASAs among Yemeni infertile couples.
- \* The necessity of including fresh micro-slide sperm agglutination, sperm shaky head movement and ASAs lab techniques as a routine clinical lab tests for diagnosis of infertility.

### **Patients and Methods**

**Patients:** two hundred thirty five infertile couples attending Al-



low Medical IVF Center, for infertility treatment were prospectively analyzed and involved in the present study. Duration of this study was from August 2005 to October 2007. Complete physical, medical, and infertility data were documented and diagnosed as infertile cases with positive SA and SSM. Their sex and thyroid hormonal profiles, and prolactin were within the normal values. There was no history of administration of glucocorticoids at least for 3 months prior to participation in the present study and seminal fluid culture and sensitivity was negative for pathogenic bacterial growth. They were inspected for any history of testicular trauma, mumps, orchitis, testicular torsions, varicocele, cryptorchidism, surgical intervention, sterile seminal fluid infection. The institutional review board at Colleague of Medicine and Health Sciences, Sana'a University approved the protocol, and all couples gave written informed consent. All these couples were divided into two groups (group-I: 165 men = have sperm agglutination > 10% and group-II: 70 infertile men with absent of sperm agglutination or

<10%). Inclusion criteria for women were no anatomical or endocrine problems. Sera of the male were collected for measurement of ASA concentration. Following the diagnosis of immunoinfertility (group-I) and infertility (group-II) all couples were recommended to be treated by appropriate assisted reproductive techniques. The outcome of assisted reproductive techniques for couples which involved in the present paper is not involved and will publish in future in separated papers.

**Spermogram and its Evaluation:** Written informed consent was obtained from all participants after recruitment. Semen samples were collected by masturbation at the site of our center, after the men had been asked to abstain from ejaculation for at least 48 hours before semen was collected. All semen analyses were performed manually within one hour after the sample was collected and included measurements of the volume of the ejaculate and determinations of the sperm concentration and the percentage of sperm motility, shaky head movement, agglutination and morphology.

Two-three semen specimens were obtained from each man who was involved in the present study. The number of days between the specimen collections was from 25-42 days. The mean values for each semen sample were calculated in studied by slide method. Semen fluid analysis was performed in our external out-patient lab- according the guidelines of the World Health Organizatio (WHO, 1999).

**Sperm Agglutination:** Agglutination of spermatozoa means that motile spermatozoa stick to each other - head to head agglutination, tail to tail or in a mixed way, e. g. medpiece to tail. The adherence either of immotile spermatozoa to each other or of motile spermatozoa to mucus threads, cells other than spermatozoa, or debris is considered to be nonspecific agglutination. The specimen was observed for sperm agglutination by preparing a drop (50 $\mu$ L) of semen into a warm microscopic slide covered by a cover slip. The presence of sperm agglutination with shaky sperm head was suggestive of the existence of an immunological cause of infertility. The extent of

agglutination was important. The presence of only a few groups of small numbers of agglutinated spermatozoa was also recorded. Sperm agglutination and interaction between spermatozoa were graded as:

- + (sub-mild sperm agglutination) -----  $\leq$  10%
- + + (Mild sperm agglutination)--  
----- 10-20%
- + + + (Marked sperm agglutination)----- 21- 40%
- + + + + (Very marked agglutination)-----  $>$ 40%

For estimation of percentage of sperm agglutination the following formula is used:

$$\text{Percentage of agglutinated sperms} = \frac{\text{No. of agglutinated sperms}}{\text{Total number of spermatozoa}} \times 100$$

Sperm Shaky head Movement: was determined by the same formula applied to the above mentioned for sperm agglutination.

Detection of ASAs by Immuno-bead Test: fresh spermatozoa, harvested by swim-up technique are incubated with serum or seminal

plasma, then carefully washed, and immunobeads covered with anti-IgG or anti-IgA (or anti-IgM) are added. Under the microscope immunobeads are seen adhering to the motile spermatozoa if the sample contains ASA of the proper immunoglobulin class. The test was carried out with higher dilutions of serum (1:100), to provide better clinical guidance. The reaction is negative or weakly positive (50% of the motile spermatozoa carrying immunoglobulins: IgG, or IgA, or both). On the other hand, if the majority (>50%) of spermatozoa have immunoglobulins on their membrane, the consequences are diagnosed as immunological infertility.

**Serum ASA ELISA Test:** Serum concentration of ASAs was performed Using Exym-ELISA, Roche, Swiss. Sperm Antibody Enzyme Immunoassay Kit - Human Comp. England. The strips were incubated with diluted sera (1:50) from patients, and after washing steps, were incubated again with peroxidase conjugated anti-human-Ig (IgA, IgG and IgM). Following the final wash and enzyme substrate addition, the developed

colour was determined using the ELISA reader. Positive results are indicated by ASA concentrations > 75 U/ml in diluted sample of serum as recommended by Human Company, England.

**Sperm-Cervical Mucus Interaction:** For fertilization to take place in-vivo, the sperm must be able to get past the cervical mucus. The post coital test assesses the ability of sperm to penetrate and progress through cervical mucus. Cervical mucus is examined 2-3 hours after intercourse at the time of expected ovulation. A presence of greater than 10-20 motile sperm per high power field is generally accepted as a normal post coital test. Post coital testing is a bio-assay that provides information concerning sexual function, motility of the sperm, and the sperm-mucus interaction. A positive result implies normal semen and mucus. A poor result in an individual with normal semen parameters implies either cervical abnormality or the presence of sperm antibodies.

**Statistical Evaluation.**

Data were analyzed with in

built functions within the Statistical Package for Social Science (SPSS UK Ltd, version 7.5:2000, Chertey, Surrey, United Kingdom). The statistical tests used depend on the nature of the data. In addition to the standard statistical methods to determine the mean, standard deviation and standard error of the mean (SEM), we used student's t-test and multiple analysis of variances (MANOVA) to determine the level of statistical significance between the means and correlation test. Differences were considered statistically significant at  $P \leq 0.05$ .

### Results

The result of the present study has demonstrated the prevalence of possible causes of ASAs among Yemeni infertile patients as shown in table 1. A significant increase in the number of cases with a history of orchitis (unknown causes), chronic epididymitis, and sterile seminal fluid infections were high in infertile patients with high sperm agglutination >10% in group I compare to group II (12/165 (7.3%) and 1/70 (1.4%); 39/165 (23.6%) and

3/70 (4.3%); 44/165 (26.7%) and 8/70 (11.4%), respectively,  $P < 0.003$ , table 1).

The number of patients with high sperm agglutination but unknown causes was significantly ( $P < 0.02$ ) lower in group-I compare to group-II. Furthermore, the number of infertile men with varicocele was higher ( $P < 0.04$ ) in group-I in compare to groupe-II (table 1).

The spermogram and ASAs screening of patients involved in this study are demonstrated in table 2. All parameters of spermogram which were documented in this study (except volume of semen and sperm concentration) showed high differences ( $P < 0.02$ ) between group I and II. The level of serum ASAs in group-I was significantly higher ( $P < 0.001$ ) when compared to group-II and the number of women with poor post-coital test (i.e. positive cervical factor) was significantly ( $P < 0.003$ ) different between both groups (table 2).

In the present study a positive correlation between concentration

of ASAs and sperm shaky head movement as well as percentage of sperm agglutination was noted (n = 235, r = 0.738, P<0.0001).

The patients with high serum ASA titers (in their sera) showed a positive correlations with sterile seminal fluid infection (n=44, r=0.692, P<0.01).

**Table 1 :** Prevalence of possible causes of ASAs in Yemeni infertile couples.

<b>Parameter</b>	<b>Group I with SA &gt;10% n = 165</b>	<b>Group II with SA &lt;10% n =70</b>	<b>P values</b>
Age (years) ± SD*	28.3 ± 2.6	27.5 ± 3.5	0.17
BMI (Kg/m <sup>2</sup> ) ± SD*	24.8 ± 1.9	23.6 ± 1.7	0.33
Duration of Infertility (yrs)± SD*	6.6 ± 4.2	7.3 ± 5.1	0.07
Accidental Testicular Trauma, (%).	7/165 (4.2%)	3/70 (4.3%)	0.19
Orchitis due to mumps, (%).	9/165 (5.5%)	Zero	----
Orchitis (unknown causes), (%).	12/165 (7.3%)	1/70 (1.4%)	0.003
Varecocele , (%).	17/165 (10.3%)	2/70 (2.9%)	0.04
Surgical Intervention , (%).	11/165 (6.7%)	8/70 (11.4%)	0.13
Chronic Epididymitis , (%).	39/165 (23.6%)	3/70 (4.3%)	0.001
Sterile Seminal Fluid Infection , (%).	44/165 (26.7%)	8/70 (11.4%)	0.001
Idiopathic, (%).	26/165 (15.8%)	45/70 (64.3%)	0.02

\* SD-Standard Deviation ; BMI-Body mass index

<b>Table 2:</b> Comparison of spermogram, sera ASA-titers, and cervical factor in infertile couples, which involved in the present study.			
<b>Parameter</b>	<b>Group I with SA &gt;10% n = 165</b>	<b>Group-II with SA &lt;10% n =70</b>	<b>P values</b>
Volume (ml)*	2.5 ± 0.6	2.1 ± 0.5	0.27
Sperm concentration (x 10 <sup>6</sup> /ml)*	34.7 ± 3.2	28.1 ± 5.7	0.09
Sperm motility (%)*	43.4 ± 5.8	45.9 ± 4.2	0.004
Sperm normal morphology (%)*	26.3 ± 8.6	49.1 ± 3.9	0.001
Sperm shaky head movement (%)*	35.7 ± 3.8	8.1 ± 2.7	0.003
Sperm agglutination (%)*	42.3 ± 15.2	3.2 ± 0.7	0.02
Serum level of ASAs*	364.6 ± 86.3	52.2 ± 36.2	0.001
Number of women with positive cervical factor (poor results of post coital test), (%)	128/165 (76.4%)	3/70 (4.3%)	0.003
* All values are Mean ± Standard Deviation			

### **Discussion**

The present study showed the possible causes of ASAs among Yemeni infertile patients . It was found out that more than 60% of Yemeni infertile patients group-I involved in the present study suffered from sterile seminal fluid infection (44/165 (26.7%) , chronic epididymitis (39/165 (23.6%) and orchitis (21/165 (12.7%)) and their positive interference with high concentration of ASA in own sera. These results were in good agreement with that reported by McDonald in (2000) and Lombardo et al., in (2004).

Presence of sterile seminal fluid infection (i.e. no bacterial growth after culturing of ejaculate) or previous orchitis lead to damage of blood-testis barrier (BTB). Physiologically, the BTB is a tight junction between Sertoli cells and appears to play a major role in keeping the developing spermatozoa and immune system separate. It prevents those testicular cells expressing "foreign" antigens from coming into contact with lymphoid tissue and immunocompetent cells from entering the seminiferous tubules (Omu et al., 1998 and

Buhanovic et al., 2004) . However, the BTB is commonly breached by physiological leakage of normally sequestered sperm antigens.

When the BTB were damaged due to infection these antigens come into contact with immunocompetent cells, ASA formation occurs and lead to formation of auto-immunity against own sperms (Almagor et al., 1998 & Bronson in 1999) reported that the active local immunoregulatory mechanisms start being operative within the testes. Autoimmunity to sperm may occur because sperm cell antigens are first expressed during sexual maturation (Allow, 2002), long after the prenatal period when immunological self-tolerance is induced (Koide and Kamada, 2000; Lombardo et al., 2004 & Naz and Menge , 1994).

Generally, every breakdown of blood-testis barrier and protective immunomodulatory mechanisms or humoral immune response such as ASA formation can be induced primarily during infectious and noninfectious inflammations lead to immunoinfertility, or by

Benha M. J.

---

Vol. 26 No 3 Sept. 2009

obstruction of testicular efferent duct - obstructive azoospermia (Almagor et al., 1998). The ASAs were also induced after accidental and/or surgical injury of testicles (group-I = 11/165 (6.7%) and group-II 8/70 (11.4%)), exposure to very low temperature or cryptorchidism (McDonald, 2000 & Fabio et al., 2003). Subsequently, infertility can result from antibodies directly binding the sperm, or from spermatogenesis due to orchitis. A similar phenomenon occurs in vasectomized laboratory rodents and man (McDonald, 2000).

Most affected individuals develop epididymal sperm granulomas and testicular degeneration associated with the formation of ASAs. Mechanisms that can provide the autoimmunity and ASA production are micro-environmental acceleration of T-helper-type-1 (Th1) of immunity, enhanced secretion of pro-inflammatory cytokines like IL-1, reduced secretion of anti-inflammatory cytokines like IL-10 and TGF- $\beta$ , up-regulation of MHC and co-stimulatory molecules expression and down-regulation of immune cells apoptotic mecha-

nism (McDonald , 2000). Finally, the presence of sperm agglutination > 10% of viable sperms without bacterial seminal fluid infection and high concentration of serum ASAs reacting with antigens on the sperm are considered typical and specific immunoinfertility (Allow et al., 2001).

The indication for ASAs testing in these Yemeni infertile patients was abnormal semen parameters which include high percentage of SA, SSM, poor sperm motility and poor sperm mucous interaction tests (postcoital test). All these tests were strongly and significantly higher in group-I when compared to group-II. These sperm parameters were also positively correlated significantly with high concentration of their own sera ASAs and poor sperm mucous interaction tests of their wives. In the last decade there are a lot of reports on human ASAs and interference of some of them with reproductive physiology. It is supposed that sterile seminal fluid infection and high percentage of SA associating with high concentration of ASAs and binding to sperm surface which inhibit



sperm function parameters and fertilization and the presence of circulating ASAs in uterine cervix of women have been implicated as a contributing factor to immunoinfertility (Allow, 1999). In these studies, the incidence of subsequent pregnancy in infertile couples was absent if one or both partners had ASAs in serum (Cibulka et al., 2009) or in genital tract secretions (Emin et al., 2008). According to other reports, the prevalence of ASA positive cases in men and women with unexplained infertility was significantly more than cases with explained infertility. This certifies that ASAs affect fertility (Ulcova - Gallova et al., 2009) and this relationship had been confirmed in our present work.

Regarding the aforementioned studies, the concept of ASAs in fertilization is based on their presence in serum and different secretions of the human reproductive tract (Bronson , 1999) . Although some studies have pointed to the higher prevalence of ASAs in infertile patients (Berek and Novak , 2007). Recently, it was successfully recommended the using of

phage display technology to obtain antisperm scFv antibodies of defined antigen specificity. These antibodies will find clinical applications in the development of novel immunocontraceptives, and specific diagnostics for immunoinfertility (Samuel and Naz , 2008).

The positive correlations between percentages of sperm agglutination as well as sperm shaky head movement and ASAs titers indicated that sperm agglutination and sperm shaky head movement should be used as a good and simple lab tests indicators for the presence of ASAs in the own sera and seminal plasma as well as good indicator for diagnosis of immunoinfertility. Ability to diagnose carefully will lead to right way of treatment. Finally, using of these lab test techniques are useful, answerable, and acceptable methods for diagnosis of immunoinfertility.

Our study does not agree with the result presented by Karimi, et.al. (2008) for the following reasons: 1) the group of patients involved in their study had unexplained infertility and such group of patients have to be infertile with

unknown causes 2) the researchers did not present any data about their spermogram including sperm agglutination, sperm shaky head movement, etc. It is our belief that such groups of unexplained infertility are a matter involving divine powers and keeping them unexplained infertile. Such group should not be subject to experimentation. Probably, for these reason the authors did not find and significant differences. That is true because it is unexplained infertility. It is our belief that the cases of such group (unexplained infertility) are unexplainable and fall in the domain of divinity.

### **Conclusions**

#### **we concluded that:**

1. The prevalence of immunoinfertility factors among Yemeni infertile patients report more than 63% of causes mainly due to sterile seminal fluid infection, chronic epididymitis and orchitis.
2. We emphasized on the importance of percentage of sperm agglutination and sperm shaky head movement should be associated with high titer

of ASAs in their sera and seminal plasma.

3. We recommend the use of these so simple useful, accessible, and reliable lab tests as a routine investigation for diagnosis of high titer of ASAs as well as immunoinfertility and should be considered seriously.
4. We advise that such tests should be involved in medical reports regarding infertility and expect that the authorities concerned in the ministry of health will put into effect all our suggestions and help to diagnose of immunoinfertility.

### **References**

**Allow A. K. (1999)** : Treatment and in vitro sperm activation for immunologically infertile patients.M.Sc. thesis - in Reproductive physiology and infertility, University of Kufa, College of Medicine, Iraq.,: p. 236.

**Allow A. K. and R.B.M.T.a.A.-S.Y.M., (2001)** : The effect of three courses of treatment with antibiotic and prednisolone on sperm agglutination and sperm

morphology in immunologically infertile patients. . Kufa Medical J. 4: p. 392-399.

**Allow A. K. and R.-B.M.T.a.A.S., (2002)** : The efficacy of antisperm antibody separation (ASAS) and anintrauterine insemination in couples with immunologic infertility. Annals of College of Medicine Mousel., 28: p. 36-41.

**Almagor M.; Dan-Goor M.; Hovav Y. and Kafka I., (1998)** : Antisperm antibodies in men with psychogenic anejaculation. Arch Androl. 41: p. 1-4.

**Berek and Novak, Berek and Novak's Gynecology. New York (2007)** : Immunology and infertility., Lippincott Williams & Wilkins., 14th ed. Chapter , 3. P. 235

**Berkowitz R. S., B. R., Ryan K. J., Kistner R. W. and Kistner's Gynecology (1995)** : Principles and Practice. St. Louis: Mosby-Year Book., 6th ed.

**Bronson R. (1999)** : Detection of antisperm antibodies : an argument against therapeutic ni-

hilism. Hum. Reprod., 14: p. 1671-1673.

**Bubanovic I., Najman S. and Kojic S. (2004)** : Immunomodulatory Treatment for Infertile Men with Antisperm Antibodies. Fertil. Steril., 81(3:S7-31).

**Cibulka J., U.G.Z., Balvín M., Bibková K. and Micanová Z. (2009)** : Isolation and immunology identification of spermagglutinating antibodies from human serum. Ceska Gynekol., 74(3): p. 201-8.

**Emin A., K. E., Lichev D., Avazova N., Popov I. and Radev R. (2008)** : The importance of the presence of antisperm antibodies in serum and ejaculate of men with infertility. Akush Ginekol (Sofia). , 47(2): p. 26-30.

**Fábio F., A. M., Lucon H., Plínio M., Góes B. and Saldanha S. (2003)** : Induction of spermatogenesis in azoospermic men after varicocele repair. Hum Reprod., 18: p. 108-112.

**Karimi F., Khazaei S. and Alaedini F. (2008)** : Serum anti-

sperm antibodies in fertile and infertile individuals. *IJMS*, 33-2: p. 88-93.

**Koide S. S., W.L. and Kamada M. (2000)** : Antisperm antibodies associated with infertility: properties and encoding genes of target antigens. *Proc Soc Exp Biol Med.*, 224: p. 123-132

**Lombardo F., G. L., Lenzi A. and Dondero F. (2004)** : Antisperm immunity in assisted reproduction. *J of Reprod Immunol.*, 62: p. 101-109.

**Marshburn P. B. (1997)** : Antisperm antibodies and infertility. *Infertility & Reproductive Medicine Clinics of NorthAmerica.*, 1 8(2): p. 243-266.

**McDonald S. W. (2000)** : Cellular responses to vasectomy. *Int Rev Cytol* 199: p. 295-339.

**Naz R. K. and Menge R. C. (1994)** : Antisperm antibodies: origin, regulation and sperm reactivity in human infertility. *Fertil Steril.* 61: p. 1001-1013.

**Omu A. E., Al-Othman S., Mo-**

**hamad A. S., Al-kalnaby N. M., and Fernandes S. (1998)** : Antibiotic Therapy for Seminal Infection Effect on Antioxidant Activity and T-Helper Cytokines. *J. Reprod. Med.*, 43: p. 857- 864.

**Rumke P. (1954)** : The presence of antisperm antibodies in the serum of two patients with oligospermia. *Vox Sang.*, 4: p. 135-40.

**Samuel A. S. and Naz R. K. (2008)** : Isolation of human single chain variable fragment antibodies against specific sperm antigens for immunocontraceptive development. *Hum. Repr.*, 23(6): p. 1324-1337.

**Tian X., Z. L., Wu y, Yang C. and Liup (1999)** : Relationship between serum antisperm antibodies and anticardiolipin antibodies and clinical pregnancy outcome in an in vitro fertilization and embryo transfer program. *Chinese Medical Journal.*, 112(1): p. 34-36.

**Ulcova-Gallova Z., G. J., Vrzalova J., Bibkova K., Peknicova J., Micanova Z. and Topolcan O.**

**(2009)** : Sperm antibodies, intra-acrosomal sperm proteins, and cytokines in semen in men from infertile couples. *Am J Reprod Immunol.* ., 61(3): p. 236-245.

**Wilson L. (1954)** : Sperm agglutination in human semen and blood. *Exp. Biol. Med.*, 85 :

p. 625-655.

**World Health Organization (WHO), (1999)** : Laboratory manual for the examination of human semen and sperm cervical mucus interaction. 4rd ed. New York, Cambridge University. Press., 4 : p. 4-59.

REPRINT

# **BENHA MEDICAL JOURNAL**

**IS ANTISPERM ANTIBODIES  
LAB INVESTIGATION TECHNIQUE  
NECESSARY AS A ROUTINE  
EXAMINATION FOR DIAGNOSIS  
OF IMMUNOINFERTILITY?**

**Allow A. Kaid Ph.D, Rashad A. A. Thabet Ph.D,  
Saeed M. Saeed Ph.D; Bracamonte M. Allow MSc.  
Almuhia E. Numan and Albarzanchi M. Taib Ph.D**

**Published by  
Benha Faculty of Medicine**

*Volume 26 Number 3  
Sept. 2009*

## **PLASMA RENIN ACTIVITY AND CEREBRAL ISCHEMIC STROKE EXPERIMENTAL AND CLINICAL STUDY**

**Mohamed Ahdy A. Saad Ph.D, Amr M. Abbas Ph.D\*,  
Vivian Boshra Ph.D, Mohamed Elkhateeb MD\*\*  
and Ibrahim Abd El Aal MD\*\*\***

*Departments of Pharmacology , Medical Physiology \*,  
Neurology \*\* and Clinical Pathology\*\*\*,  
Faculty of Medicine, Mansoura University, Egypt*

### **Abstract**

**Background:** *This study aims at studying the probable affection of renal renin secretion after human ischemic stroke and correlating it to the post stroke neurological and renal function alterations using  $\beta_1$  adrenoreceptor blocker atenolol in Wistar rats subjected to middle cerebral artery occlusion.*

**Methods:** *This study comprised 21 patients with cerebral ischemic stroke. Seventeen normal persons were used for comparison. Recumbent and standing PRA, reflex plasma renin sensitivity, plasminogen activator inhibitor and creatinine clearance (Ccr) were estimated at admission and two weeks later. Moreover, 40 albino rats were divided into SHAM, Non-treated and atenolol treated, and ischemic, non-treated and atenolol treated groups. In all rats, neurobehavioral evaluation, Ccr, PRA, and infarct size were measured.*

**Results:** *Together with the significant deterioration of the neurological score, focal cerebral ischemia in rats had increased PRA and decreased GFR. In ischemic stroke patients, GFR was significantly decreased at admission and two weeks later, while plasma renin reflex secretion sensitivity had decreased significantly at admission relative to controls, but it increased significantly 2 weeks later. Atenolol caused significant improvement of the neurobehavioral score and renal function of rats subjected to focal cerebral ischemia.*

**Conclusion:** *PRA could be a promising therapeutic target for stroke.*

**Key Words:**  *$\beta_1$  adrenoreceptor blocker, GFR, Ischemic stroke, renal renin secretion.*

### **Introduction**

Focal cerebral ischemia is a common, life-threatening disease in humans. The severity of clinical manifestations after cerebral ischemia depends mainly on the location and size of the infarct area in the brain (Hunter et al, 1998). There is increasing data showing that angiotensin II (AII) may be involved in the initiation and regulation of processes occurring in brain ischemia either in animal models of cerebral ischemia (Walther et al, 2002) or in stroke patient (Espiner et al, 2002). Activation of the RAS has been linked with an increased risk of myocardial infarction and stroke (Alderman et al, 1991; Schneiderman et al, 1992). Several reports have indicated chronic kidney disease to be an additional independent and powerful predictor for stroke outcome (Covic et al, 2008).

We suggest a post stroke alteration of the renal secretion of renin and a probable incrimination of the renal renin angiotensin system in the post-stroke morbidity. So this work aims at studying the probable affection of renal renin secretion after human ischemic

stroke and correlating it to the post stroke neurological and a probable renal function alteration using the anti-renin  $\beta_1$  adrenoreceptor blocker atenolol in the rats subjected to middle cerebral artery occlusion. This is together with suggested plasminogen activated inhibitor integration in post-stroke morbidity since RAS can influence the fibrinolytic balance (Kerins et al, 1995).

### **Methods:**

#### **(I) Experimental part:**

**Drug used:** Selective  $\beta_1$  blocker: Atenolol, (powder- Epico Co, Egypt)

**Animals used:** This study was carried on 40 male Wistar rats weighting 210-250 grams/ rat. Animals were having free access to food and water. They were exposed to the same housing conditions of heat and humidity. All experimental procedures were performed in accordance with guidelines of the Medical Research Ethics Committee of Mansoura University, Egypt.

**Surgical procedures:** Rats were exposed to left permanent middle cerebral artery (MCA) oc-



clusion described by Tamura et al., (1981). Each animal was anesthetized by thiopental sodium at a dose of 30mg/kg body weight intraperitoneally and given additional dose of 10mg/kg when required (Wixson and White, 1987). Briefly, the MCA was approached through a temporal incision, and the bone overlying the vessel was removed using a dental drill. The dura was opened, and the arachnoid membrane was gently removed. The vessel was occluded by thermal coagulation, from a point proximal to the lenticulostriate branches to the rhinal fissure. The incision was closed, and the rats were returned to their home cage after full recovery from anesthesia.

**Animal grouping:**

Rats were divided into 4 groups (10 rats for each).

**Group (1):** Non-treated SHAM group (1ml saline).

**Group (2):** Atenolol treated SHAM group.

**Group (3):** Non-treated ischemic group (1ml saline)

**Group (4):** Atenolol treated ischemic group.

The animals received saline or medications intraperitoneally (IP) within 5 minutes after surgery and then once per day for successive seven days. The doses of drugs were dissolved in saline in order to obtain a dose required for each animal in 1ml saline. The dose of atenolol was 100  $\mu\text{g}$  / kg /day. This dose was used for inhibition of renin secretion without affecting the normal blood pressure in dogs (Osborn et al, 1981) and was calculated in rats according to Paget and Barnes (1964).

**Consequent steps after left MCA occlusion:**

**I- Neurobehavioral evaluation:** It was started on the next day after surgery and repeated for successive 6 days. It consisted of the following tests (Garcia et al, 1995):

**1- spontaneous activity:** The animal was observed for 5 minutes in its normal cage. The rat's activity was assessed by its ability to approach all four walls of the cage. Scores indicate the following: Score 3: Rat moved around, explored environment, and approached at least three walls of

the cage. Score 2: Slightly affected rat moved about the cage but did not approach all sides and hesitated to move, although it reached at least one upper rim of the cage. Score 1: Severely affected rat did not rise up at all and barely moved in the cage. Score 0: Rat did not move at all.

**2- Symmetry in the movement of four limbs:** The rat was held in the air by the tail to observe symmetry in the movement of the four limbs. Scores indicate the following: Score 3: All four limbs extended symmetrically. Score 2: Limbs on right side extended more or less slowly than those on left. Score 1: Limbs on right side showed minimal movement. Score 0: Limbs on right side did not move at all.

**3- Forepaw out stretching:** The rat was brought up to the edge of the table and to walk on forelimbs while being hold by the tail. Symmetry in the outstretching of both forelimbs was observed while the rat reached the table and the hind- limbs were kept in the air. Scores indicate the following: Score 3: Both forelimbs were

outstretched, and the rat walked symmetrically on forepaws. Score 2: Right side outstretched less than the left, and forepaw walking was impaired. Score 1: Right side moved minimally. Score 0: Right forelimb did not move.

**4- Climbing:** The rat was placed on the wall of a wire cage. Normally the rat uses all four limbs to climb up the wall. When the rat was removed from the wire cage by pulling it off by the tail, the strength of attachment was noted. Scores indicate the following: Score 3: Rat climbed easily and gripped tightly to the wire. Score 2: Right side was impaired while climbing or did not grip as hard as left side. Score 1: Rat failed to climb or tended to circle instead of climbing.

**5- Body proprioception:** The rat was touched with a blunt stick on each side of the body, and the reaction to the stimulus was observed. Scores indicate the following: Score 3 : Rat reacted by turning head and was equally anxious by the stimulus on both sides. Score 2 : Rat reacted slowly to stimulus on right side.

Score 1: Rat did not respond to stimulus placed on right side.

**6- Response to vibrissae touch:** A blunt stick was brushed against the vibrissae on each side; the stick was moved toward the whiskers from the rear of animal to avoid entering the visual fields. Scores indicate the following: Score 3: Rat reacted by turning head or was equally startled by stimulus on both sides. Score 2: Rat reacted slowly to stimulus on right side. Score 1: Rat did not respond to stimulus on right side.

The score given to each rat at the completion of the evaluation is the summation of all six individual test scores. The minimum neurological score is 3 and the maximum is 18.

**II. Determination of GFR:** On the 6th day of MCA occlusion, rats were put in the metabolic cage to determine the amount of urine all over next 24 hours. Then 2ml venous blood sample was taken from each rat tail vein and divided into two equal samples, one for assay of serum creatinine and the other for assay of PRA. The serum

was separated from the first sample by centrifugation at 1000 rpm for 10 min. Both serum and urine creatinine were assayed using a colorimetric method (Henry, 1974). Creatinine clearance, which indicates the value of the GFR, was calculated through the usual equation (Bartels et al, 1971):

$$\text{Urine creatinine mg/dl} \times \text{Urine volume collected for 24 hrs} \\ = \frac{\text{Serum creatinine mg/dl} \times 1440}{\text{Urine volume collected for 24 hrs}}$$

**III- Estimation of PRA:** The 2nd venous blood sample was collected on EDTA (1mg/ml blood). The plasma was separated by centrifugation at 1000 rpm for 15 min. and frozen at -20° till time of assay of PRA by radioimmunoassay (Yalow and Berson, 1971).

**IV- Assessment of the effect of MCA occlusion on the infarct size by staining of the brain with 2,3,5 triphenyl tetrazolium chloride (TTC) stain:** After decapitation of the rats, both hemispheres of the brain of each rat were quickly removed and placed in ice-cold saline for 5 minutes

and then cut into 2 mm coronal slices. Sections were incubated in TTC-containing saline solution (Sigma, St. Louis, MO) for 20 minutes. Then, the slices were refrigerated in 10% formalin over night. The infarcted areas were outlined in white. The percentage of infarcted size was measured by adobe photoshop-5 program (Goldlust et al, 1996).

**(II) Clinical part:**

The study was carried out at Neurology Department of Emergency and Mansoura University Hospitals, Mansoura, Egypt.

**Study population:** This study included 21 consecutive cases with a CT- confirmed diagnosis of ischemic stroke. All patients were followed up for two weeks. For comparison, 17 healthy individuals of nearly matched age and sex were taken as a control group. Informed consent was taken from all subjects and patient anonymity is preserved. In addition, this study has been approved by Medical Research Ethics Committee of Mansoura University, Egypt.

**Inclusion criteria and stroke**

**definition:** In this study, we included all patients aged around sixty that presented in Neurology Department, Mansoura Emergency Hospital with first ever stroke between February 2008 and January 2009. Ascertainment of each case was based on the medical history, clinical neurological examination, CT scan to confirm the diagnosis and to determine the type and evolution of stroke at admission at the first 24 hours and at the end of the two weeks of follow up. Eight patients were having no detectable CT scan lesion at admission in spite of stroke diagnosis based on the neurological examination, these patients had the detectable CT scan lesion by the scan done at the end of two weeks of follow up. All patients were under treatment with neurotrophics, antioxidants, antiplatelets and some patients received anticoagulants during the two weeks of follow up.

**Exclusion criteria:** Patients were excluded if they were of a suspected haemorrhagic stroke or already having a history of cardiovascular or renal diseases

or diabetes or with a pre-stroke drug treatment for a systemic disease.

**Clinical variables:** Details of neurological status and disabilities, and current drug use were recorded. Other relevant clinical data, including ECG and CT scan results, were also collected. With the objective of recording the conscious state of our patients along the two weeks of the study we followed Glasgow coma scale (Teasdale et al, 1979). All patients were having either 14 or 15 score of the good consciousness along the two weeks of follow up. Laboratory data, including creatinine and glucose concentration on admission, were collected. These in addition to:

**1. Definition of acute kidney function diminution:** Acute kidney function diminution was defined by estimation of the Ccr, which indicate the value of the GFR, both at the patient admission and after two weeks of follow up. Creatinine clearance was estimated through the usual equation (Bartels et al, 1971).

**2. Estimation of PRA:** The

patient coming recumbent to the emergency room within the first 12 hours of the stroke was consulted. Venous blood sampling was done at the end of one hour of recumbence. Following this period of recumbence another venous blood sample was taken at the end of 15 minutes of standing. Plasma renin activity was determined by radioimmunoassay (RIA) kit (Hyphen Medical, USA) according to the method described by Yalow and Berson, (1971). The difference between the estimated PRA of the two samples indicates the sensitivity of the baroreceptor mediated reflex renin secretion by the juxtaglomerular apparatus of the kidneys (Goldstein et al, 1982). The increase in serum PRA by standing indicates the efficiency of the reflex renin secretory activity of the kidneys.

**3. Determination of plasminogen activator inhibitor (PAI):** It was determined in plasma using ELISA kit (Hyphen Medical, USA) according to the method described by De Pergola et al, (1997).

**Statistical analyses:** The data are presented as mean  $\pm$  standard

error of mean (SEM). One-way ANOVA analysis of data was done followed by post hoc test of Tukey. Paired Student t-test was done when appropriate in comparing the infarction size and in comparing recumbent and standing PRA of the same patient. Pearson correlation statistical analysis was done for detection of a probable significance between two different parameters. A P value of < 0.05 value was considered significant (Armitage and Berry, 1994).

## Results

### (I) Experimental part:

The mean neurological scores of SHAM groups (either treated or non-treated) were 18 starting from the second postoperative day and maintained till the end of duration of follow up (7days). They were significantly decreased in the focal cerebral ischemic group as compared to SHAM groups starting from the second postoperative day, and then gradually improved until time of scarification. Treatment with atenolol caused significant improvement in the mean neurological score starting from the 3<sup>rd</sup> postoperative days till the time of scarification as compared

to those days in the non-treated ischemic group (table 1).

Plasma renin activity was significantly increased in the non-treated ischemic group (group 3) in comparison to that of SHAM group (group 1). Treatment with atenolol significantly decreased PRA in either SHAM or ischemic groups (groups 2, 4) in comparison with non-treated groups (groups 1, 3 respectively). However, PRA of treated ischemic group was still higher than that of either non-treated SHAM or treated SHAM (table 2).

Creatinine clearance was significantly decreased in the non-treated ischemic group (group 3) relative to that of SHAM group (group 1). Treatment with atenolol significantly increased creatinine clearance in the atenolol treated ischemic groups (groups 4) relative to non-treated group (groups 1) (table 2).

The infract size was significantly decreased in the ischemic group treated with atenolol relative to non-treated group after 7 days of permanent focal cerebral ischemia (table 2, figure 1).

**(II) Clinical part: (table 3)**

Seventeen patients of 21 admitted with a diagnosed ischemic stroke were of a left hemispheric localization and the remaining four patients were having a right hemispheric localization. Eight of the 21 ischemic stroke patients were having a non detectable C.T. scan lesion of either hemisphere and the lesion had been detected at the left hemisphere by the end of the second week. The C.T. detected lesion of the 21 patients was increased in size at the second week in comparison to the size measured at admission.

At admission, all patients had a significant decrease in GFR in comparison to control normal persons ( $68 \pm 8.6$  Vs  $103 \pm 4.0$  ml/min. respectively). This degree of diminution was detectable also ( $66 \pm 6.4$  ml/min) at the end of the second week after admission.

Recumbent PRA measured at admission was significantly higher than of the control normal persons ( $11.0 \pm 0.6$  Vs  $6.2 \pm 0.6$  ng/ml). It had increased more and more at the end of the second week ( $30.0 \pm 1.4$  ng/ml), an in-

crease which was significant in comparison to the level measured at admission. Moreover, PRA measured at the end of 15 minutes of standing, following one hour of recumbence, was having the same developing significant increases like those of the recumbent PRA. In both normal control persons and ischemic stroke patients, standing had induced a significant increase in PRA in comparison to the recumbent PRA at either admission or two weeks later.

Reflex PRA, indicated by the difference between standing and recumbent PRA, in ischemic stroke patients at admission ( $1.24 \pm 0.10$  ng/ml) was significantly less than that of the control normal persons ( $2.30 \pm 0.37$  ng/ml). However this reflex PRA was significantly increased at the second week measurement ( $4.86 \pm 0.37$  ng/ml) either in comparison to admission value or control normal persons. Only, admission value of the standing induced reflex PRA was significantly negatively correlated with GFR measured at admission of the ischemic stroke patients. This correlation had not

been detected at the second week of admission. Plasminogen activator inhibitor (PAI) had increased significantly by ischemic stroke to the same degree at either admission or at the second week measurement in comparison to the control normal persons.

**Table (1):** Effect of atenolol (100 µg/ kg IP for successive 7 days) on neurological score after 7 days of permanent focal cerebral ischemia (MCA occlusion) in Wistar rats

	<b>Non--treated SHAM group (group 1)</b> (n = 10)	<b>Atenolol Treated SHAM group (group 2)</b> (n = 10)	<b>Non-treated ischemic group (group 3)</b> (n = 10)	<b>Atenolol treated ischemic group (group 4)</b> (n = 10)
<b>2<sup>nd</sup> day</b>	18± 0	18± 0	4.5±0.4 <sup>ab</sup>	5.3±0.4 <sup>ab</sup>
<b>3<sup>rd</sup> day</b>	18± 0	18± 0	5.3± 0.3 <sup>ab</sup>	9.5± 0.2 <sup>abc*</sup>
<b>4<sup>th</sup> day</b>	18± 0	18± 0	6.7±0.2 <sup>abc*</sup>	11.2±0.9 <sup>abc*+</sup>
<b>5<sup>th</sup> -7<sup>th</sup> day</b>	18± 0	18± 0	7.0±0.1 <sup>abc*+</sup>	15.3±0.3 <sup>abc*+#</sup>

Data are expressed as mean ± standard error of mean (SEM)

P<0.05

a: versus group (1)

\*: versus the 2<sup>nd</sup> day

b: versus group (2)

+: versus the 3<sup>rd</sup> day

c: versus group (3)

#: versus the 4<sup>th</sup> day

**Table (2):** Effect of atenolol on creatinine clearance, PRA and the infarcted size of brain sections stained by 2,3,5 triphenyl tetrazolium chloride (TTC) stain after 7 days of permanent focal cerebral ischemia (MCA occlusion) in Wistar rats.

	<b>Plasma Renin activity (ng /ml /hr)</b>	<b>Creatinine Clearance (ml /min )</b>	<b>Percentage of total infarcted area</b>
<b>Non--treated SHAM group (group 1)</b> (n = 10)	0.86 ± 0.06	1.2 ± 0.1	-----
<b>Atenolol treated SHAM group (group 2)</b> (n = 10)	0.45 ± 0.03 <sup>a</sup>	1.07 ± 0.08	-----
<b>Non--treated ischemic group (group 3)</b> (n = 10)	5.09 ± 0.20 <sup>ab</sup>	0.7 ± 0.06 <sup>a</sup>	18.37 ± 0.87
<b>Atenolol treated ischemic group (group 4)</b> (n = 10)	1.49 ± 0.19 <sup>abc</sup>	1.1 ± 0.1 <sup>c</sup>	8.75 ± 0.46 <sup>c</sup>

Data are expressed as mean ± standard error of mean (SEM)

P<0.05 a: versus group (1) b: versus group (2) c: versus group (3)



**Table (3):** Reflex PRA, plasminogen activator inhibitor and GFR in patients with ischemic cerebral stroke.

	<b>Control Normal Persons</b> (n = 17)	<b>Admission</b> (n = 21)	<b>Two Weeks Later</b> (n = 21)
<b>GFR (ml/min)</b>	103± 4.0	68± 8.6 *	66± 6.4 *
<b>RPRA (ng/ml)</b>	6.2± 0.6	11.0± 0.6 *	30± 1.4 *Δ
<b>SPRA (ng/ml)</b>	8.5± 0.7 †	12.2± 0.6 † *	35.0± 1.4 Δ *†
<b>Reflex PRA (ng/ml)</b>	2.30± 0.26	1.24± 0.15 ‡ *	4.86± 0.37 Δ *
<b>PAI (ng/ml)</b>	20.5± 1.2	40.5± 1.1 *	42.7± 1.2 Δ *
<b>Infarction area (Cm)</b>	-----	0.2960±0.09	0.5620±0.12 †

Data are expressed as Mean± standard error of mean (SEM)

1-One-way ANOVA analysis of data was done followed by post hoc test of Tukey.

\*  $P < 0.05$  in comparison to control normal persons & Δ in comparison to admission value

2- Paired Student t- test was done in comparing recumbent and standing PRA of the same patient & in comparing the infarction size.

†  $P < 0.05$  in comparison to control normal persons

3-Pearson correlation statistical analysis

‡  $P < 0.05$  significant negative correlation with GFR at admission.



**Fig. 1 :** TTC stain of non-treated (A), atenolol treated (B) ischemic fore-brain sections of rats.

### **Discussion**

This study confirms the post stroke acute diminution of the renal function as indicated by the significant decrease in the GFR at the first 24 hours of admission of those patients with detected CT hemispheric infarction. Interestingly this impairment of renal function seems to be not reversible since our patients had no improvement of the renal function by the end of the two weeks of follow up (table 1). This incidence of post stroke acute diminution of renal function is in accordance with the findings of Covic et al. (2008).

Since activation of the RAS has been linked with an increased risk of myocardial infarction and stroke (Alderman et al, 1991; Schneiderman et al, 1992), we have evaluated both tonic (recumbent) and reflex (standing) PRA. The difference between recumbent and standing levels indicates the baroreceptor reflex mediated renin release. The cardiopulmonary reflex represents a powerful mechanism for the direct control of renin secretion by the juxtaglomerular cells and under most physiological circumstances this control out-

weights the control exerted by the arterial baroreceptors during assumption of the upright posture (Stella et al, 1987). Reflex renin secretion is a complex physiological activity modulated by the supramedullary centers in addition to the medullary ones (Kapp and DiBona, 1992). This visceral reflex function could be altered by stroke (Elghozi et al, 1989). Renin angiotensin system is important in the haemodynamic regulation and the modulation of renal function (Zanchetti and Stella, 1975). In addition angiotensin II (A II) is recently implicated in stroke induced cerebral tissue necrosis (Espiner et al, 2002; Walther et al, 2002).

Our results show that, at admission and two weeks latter, stroke increases significantly PRA in the recumbent state, indicating an increase in the tonic stimulation of renin secretion. Our patients at admission would be stressed with an increased tonic sympathetic activity explaining the increased recumbent PRA. Reflex renin secretion at admission is inhibited compared to that of control persons which could be

explained by the activated inhibitory cortical centers that inhibit the subcortical reflex modulatory cardiovascular centers (Elghozi et al, 1989). But two weeks later, the enhanced reflex PRA could be explained by the probable loss of cortical modulatory function on reflex PRA due to ischemic destruction of lamina terminalis (Mackinley et al, 2001), insula and amygdale (Elghozi et al, 1989). The detected significant correlation between GFR and the decreased reflex PRA at admission indicates the link between the reflex PRA and the developing renal insufficiency. Also the significant increase in the infarction area by the end of the second week could be related to the significantly increased reflex PRA.

On the other hand, permanent occlusion of the left MCA in rats for successive 7 days caused significant deterioration of the mean neurological score since the second postoperative day with increase in the infarct size in comparison to the SHAM group. These neurological effects were associated with a significant rise in the PRA accompanied by a decrease in

the Ccr. Measurement of reflex PRA after 7 days of MCA occlusion put our model in a state of loss of function of higher cortical centers and not acute release of cortical neurotransmitters associated with stress or acute stage of stroke. In MCA occlusion, the destruction of the cortical centers (like the insula and amygdale) integrated in the modulation of the subcortical autonomic centers leads to liberation of these subcortical centers, controlling the baroreflex from the normal or stress mediated tonic activity (Elghozi et al, 1989). Peripheral inhibition of renin secretion by a selective  $\beta_1$  adreoreceptor blocker atenolol caused significant improvement of the markers of cerebral ischemia (the neurological score and infarct size) as well as the renal function (Ccr) compared with the non-treated ischemic group. Atenolol caused significant decrease in the raised levels of PRA with subsequent rise of the low level of Ccr noted in the non-treated focal ischemic group. Moreover, it caused significant improvement of the mean neurological score since the 3rd postoperative day. This improvement was increased by the 4th and 5th post-

operative days, a level that was maintained till the 7th day. These levels of scores were significantly higher than those obtained in the non-treated ischemic group, but still significantly less than those of SHAM groups. This improvement of the neurological score was accompanied with significant decrease in the infarct size. This result is in accordance to that of Goyagi et al., (2006) who reported that different  $\beta$ -adrenoreceptor antagonists (as propranolol) had improved the neurological and histological outcomes after transient focal cerebral ischemia in rats. This neuroprotective effect of propranolol was suggested to involve a decrease in oxygen consumption and inhibition of platelet aggregation and calcium influx (Standefer and Little, 1986). Also Laowattana and Oppenheimer (2007) found that beta-blocker use was associated with less severe stroke on presentation and may be cerebroprotective due to a sympatholytic effect associated with decreased thrombin, inflammation, and hemoglobin A1C. In contrast, selective  $\beta_1$ -adrenoreceptor antagonists seem to be different from other  $\beta$ -adrenoreceptor an-

tagonists with respect to the mechanism of neuroprotection. The reported larger proportion of  $\beta_1$ - than  $\beta_2$ -receptors in the area injured by MCA occlusion (Chidlow et al, 2000) suggested our use of the selective  $\beta_1$ -adrenoreceptor antagonists as a neuroprotective therapeutic approach. Moreover, Han et al, (2009) reported that  $\beta_2$ -adrenoreceptor agonists have neuroprotective activity by increasing nerve growth factor expression as NGF, bFGF, so our use of selective  $\beta_1$ -adrenoreceptor antagonist could enhance the neuroprotective effect of unblocked  $\beta_2$ - adrenoreceptors.

Although atenolol is a hydrophilic compounds and can not cross the blood-brain barrier, it caused significant improvement in the neurological score and reduction in the infarct volume. Because the blood-brain barrier might collapse at the early phase of ischemia, hydrophilic  $\beta$ -adrenergic antagonists might have crossed the barrier at an early phase of ischemic injury, possibly providing the neuroprotective effects (Gasche et al, 1999).

Sokol et al., (2004) reported that RAS had a role in the regulation of homeostasis and tissue response to injury in both CNS and the peripheral tissue via the activity of A II. Vascular and hematologic effects induced by A II including endothelial dysfunction, vascular structural changes, inflammation, homeostasis and fibrinolysis may increasingly link to the occurrence of cerebrovascular events (Rossi et al, 1995). Another hypothesis for the role of RAS as a risk factor in the development of cerebrovascular diseases, away from atherosclerosis and hypertension, is focused on the influence of AII on the production and release of reactive oxygen species (Volpe et al, 2002). The oxidative stress, which is selectively stimulated via the AT1 receptors subtype and most likely reduced by AT2 receptors stimulation, has a central role in the development of cerebrovascular diseases (Tsutsumi et al, 1999). Moreover, A II is capable of increasing the expression of a number inducible transcription factors including c-Fos and c-Jun via stimulation of AT1 receptors in the brain (Lebrun et al, 1995). It seems likely that in-

creased expression of these transcription factors represents part of the genetic program mediating apoptosis in brain following focal ischemia (Herra and Robertson, 1996). Therefore, another explanation for the neuroprotective effect of the hydrophilic  $\beta_1$  blocker atenolol, noted in our research, is through its peripheral inhibition of the renin secretion with a consequent prevention of the proposed deleterious effect of the circulatory AII on the cerebral function through area postrema.

The tubuloglomerular feedback (TGF) response and renin secretion share the same sensor. When loop flow and salt delivery are low, afferent arteriolar conductance is increased and renin secretion is stimulated (Cupples and Braam, 2007). Angiotensin II acts at multiple sites in the kidney; directly as a vasoconstrictor on both afferent and efferent arterioles and also as a major regulator of reabsorption from the proximal tubule, thus altering the signal that reaches the macula densa (Braam, 1999). Importantly, it is also a strong modulator of the magnitude of the TGF response; this

effect occurs at the afferent arteriole and is apparent in the absence of AII-dependent vasoconstriction (Braam and Koomans, 1995). Thus, modulation by AII of both myogenic and TGF-mediated autoregulation is at least conceptually independent of its vasoconstrictor effect. So, the regulation of GFR and RBF at low perfusion pressures results from AII-mediated efferent constriction combined with autoregulatory afferent vasodilatation (Rosivall et al, 1986). These may explain the decrease in Ccr and hence the GFR as a result of the increase of PRA noted in our research together with the direct effect of AII on the mesangial tissue (Rosivall et al, 1987). Therefore, we can, explain the protective effect of peripheral inhibition of PRA by the selective 1 blocker that preserve the GFR via prevention of the direct effect of AII on the mesangial tissue (Rosivall et al, 1987).

Plasminogen activator inhibitor (PAI), a key molecule in thrombotic vascular diseases (Kohler and Grant, 2000), is significantly increased by stroke to the same degree in all groups of stroke as measured at admission or at the

end of the two weeks of follow up. Absence of difference in the observed values at admission and at the end of two weeks of follow up of stroke may exclude its incrimination or integration in the two weeks evolution. Meanwhile it could be a consequence of the more elevated values of PRA in this group of patients.

**In conclusion**, ischemic stroke has been found to be associated with increased basal level of PRA which may be incriminated in the developed post-stroke acute renal insufficiency and the resulting infarction size. Consequently, renal renin secretion could be a promising therapeutic target in ischemic stroke patients.

### References

**Alderman M. H., Madhavan S., Ooi W. L., Cohen H., Sealey J. E. and Laragh J. H. (1991) :** Association of the renin-sodium profile with the risk of myocardial infarction in patients with hypertension. *N Engl J Med.* 324 (16):1098-104.

**Armitage P. and Berry G. (1994) :** Statistical methods in

medical research third ed. Blackwell Scientific Publication, London.

**Bartels A., et al. (1971)** : Clin. Chim. Acta. 32: 81(1971).

**Braam B. (1999)** : Renal endothelial and macula densa NOS: integrated response to changes in extracellular fluid volume. Am J Physiol Regul Integr Comp Physiol. 276:R1551-R1561

**Braam B. and Koomans H. A. (1995)** : Nitric oxide antagonizes the actions of angiotensin II to enhance tubuloglomerular feedback responsiveness. Kidney Int. 48: 1406-1411.

**Chidlow G., Melena J. and Osborne N. N. (2000)** : Betaxolol, a  $\beta_1$ -adrenoceptor antagonist, reduces  $\text{Na}^+$  influx into cortical synaptosomes by direct interaction with  $\text{Na}^+$  channels: comparison with other  $\beta$ -adrenoceptor antagonists. Br.J.Pharmacol. 130:759766.

**Covic A., Schiller A., Mardare N. G., Petrica M., Mihaescu A. and Posta N. (2008)** : The impact of acute kidney injury on short-

term survival in an Eastern European population with stroke. Nephrology Dialysis Transplantation. 23(7):2228-34.

**Cupples W. A. and Braam B. (2007)** : Assessment of renal autoregulation. Am. J. Physiol. Renal Physiol. 292:F1105-F1123.

**De Pergola G., De Mitrio V., Sciaraffia M., Pannacciulli N., Minenna A., Giorgino F., Petrelli M., Laudadio E. and Giorgino R. (1997)** : Lower androgenicity is associated with higher plasma levels prothrombotic factors irrespective of age, obesity, body fat distribution and related metabolic parameters in men. Metabolism. 46(11):1287-93.

**Elghozi J. L., Saad M. A., Hurta F. and Trancard J. (1989)** : Ischemia of the insular cortex selectively increases the vagal contribution to the baroreceptor reflex in the rat. J. Hypert. 7(96):S36-S40.

**Espiner E. A., Leikis R., Frech R. D., Bonkowski J. A., Frampton C. M. and Richards A. M. (2002)** : The neuro-cardio-

endocrine response to acute subarachnoid hemorrhage. *Clin. Endocrinol.* 56:629-635.

**Garcia J. H., Wanger S., Liu K. and Hu X. (1995)** : Neurological deficit and extent of neurological necrosis attributable to middle cerebral artery occlusion in rats. *Stroke.*26:627-635.

**Gasche Y., Fujimura M., Morita-Fujimura Y., et al., (1999)** : Early appearance of activated matrix metalloproteinase-9 after focal cerebral ischemia in mice: a possible role in blood-brain barrier dysfunction. *J. Cereb. Blood Flow Metab.* 19:1020-1028.

**Goldlust E. J., Paczynski R. P., He Y. Y., Hsu C. Y. and Goldberg M. P. (1996)** : Automated measurement of infarct size with scanned image of TTC stained rat brains. *Stroke.*27:1657-1662.

**Goldstein D. S., Horwitz D. and Keiser H. R. (1982)** : Comparison of techniques for measuring baroreflex sensitivity in man. *Circulation.* 66:432-439.

**Goyagi T., Kimura T., Nishi-**

**kawa T., Tobe Y. and Masaki Y. (2006)** :  $\beta$ -adrenoreceptor antagonists attenuate brain injury after transient focal ischemia in rats. *Anesth. Analg.* 103:658-663.

**Han R. Q., Ouyang Y. B., Xu L., Agrawal R., Patterson A. J. and Giffard R. G. (2009)** : Postischemic brain injury is attenuated in mice lacking the beta 2-adrenergic receptors. *Anesth Analg.* 108(1):280-7.

**Henry R. J. (1974)** : Clinical chemistry, principles and techniques, second ed., Harper and Row.

**Herra D. C. and Robertson H. A. (1996)** : Activation of c-Fos in the brain. *Progr. Neurobiol.* 50: 83-107.

**Hunter A. J., Mackay K. B. and Rogers D. C. (1998)** : To what extent have functional studies of ischemia in animals been useful in the assessment of potential neuroprotective agents? *Trends Pharmacol. Sci.* 19:59-66.

**Kapp U. C. and DiBona C. F. (1992)** : The neural control of



renal function. In: *The kidney: Physiology and pathology*, eds, Seldin, DW, Giebisch G, Raven Press, New York, pp. 1157-1204.

**Kerins D. M., Hao O. and Vaughan D. E. (1995)** : Angiotensin induction of PAI-1 expression in endothelial cells is mediated by the hexapeptide angiotensin IV. *J Clin Invest.* 96:2515-20.

**Kohler H. P. and Grant P. J. (2000)** : Plasminogen-activator inhibitor type 1 and coronary artery disease. *N Engl J Med.*342:1792-1801.

**Laowattana S. and Oppenheimer S. M. (2007)** : Protective effects of beta-blockers in cerebrovascular disease. *Neurology.* 68 : 509-514.

**Lebrun C. J., Blume A., Herdegen T. and Unger T. (1995)** : Angiotensin II induces a complex activation of transcription factors in the rat brain. *Neuroscience.* 65:93-99.

**Mackinley M. J., McBurnic M. I. and Mathai M. L. (2001)** : Neural mechanisms subserving cen-

tral angiotensinergic influences on plasma renin in sheep. *Hypert.* 37:1375-1381.

**Osborn J. L., DiBona G. F. and Thames M. D. (1981)** : Beta-1 receptor mediation of renin secretion elicited by low frequency renal nerve stimulation. *J. Pharmacol.Exp.Ther.*216:265-269.

**Paget G. E. and Barnes J. M. (1964)** : Evaluation of drug activities. In: *Pharmacometrics*, eds, Lawrence DR, Bacharach AL, Academic press, New York, pp.135.

**Rosivall L., Youngblood P. and Navar L. G. (1986)** : Renal autoregulatory efficiency during angiotensin-converting enzyme inhibition in dogs on a low sodium diet. *Ren Physiol.* 9:18-28.

**Rosivall L., Narkates A. J., Oparil S. and Navar L. G. (1987)** : De novo intrarenal formation of angiotensin II during control and enhanced renin secretion. *Am J Physiol Renal Fluid Electrolyte Physiol.* 252:F1118-F1123.

**Rossi G., Rossi A., Sacchetto**

- A., Pavan E. and Perssina A. C. (1995)** : Hypertensive cerebrovascular disease and the renin angiotensin system. *Stroke*.26:1700-1706.
- Schneiderman J., Sawdey M. S., Keeton M. R., et al. (1992)** : Increased type-1 plasminogen activator inhibitor gene expression in atherosclerotic plaques of human arteries. *Proc Natl Acad Sci USA*. 89:6998-7002.
- Sokol S. I., Portany E. L., Curtis J. P., Nelson M. A., Herbert P. R., Setaro J. F. and Foody J. M. (2004)** : Modulation of the renin-angiotensin-aldosterone system for the secondary prevention of stroke. *Neurology*.63:208-213.
- Standefer M. and Little J. R. (1986)** : Improved neurological outcome in experimental focal cerebral ischemia treated with propranolol. *Neurosurgery*. 18:136-140.
- Stella A., Dampney R. A. L., Golin R. and Zanchetti A. (1978)** : Afferent vagal control of renin release in the anesthetized cat. *Circ. Res.* 43 (suppl. 1) : 107-111.
- Tamura A., Graham D. I., McCulloch J. and Teasdale G. M. (1981)** : Focal cerebral ischemia in the rat: Description of technique and early neuropathological consequences following middle cerebral artery occlusion. *J. Cereb. Blood Flow Metab.* 1:53-59.
- Teasdale G., Murray G., Parker L. and Jennett B. (1979)** : Adding up the Glasgow coma score. *Acta Neurochir. Suppl.* 28 (1): 13-16.
- Tsutsumi Y., Matsubara H., Masaki H. et al. (1999)** : Angiotensin I type 2 receptor over expression activates the vascular kinin system and causes vasodilatation. *J. Clin. Invest.* 104 : 925-935.
- Volpe M., Savoia C., Depaolis P., Gstrowska B., Tarasi D. and Rubattu S. (2002)** : The renin angiotensin system as a risk factor and therapeutic target for cardiovascular and renal disease. *J. Am. Soc. Nephrol.* 13 : 173-178.

**Walther T., Olah L., Harns C., Maul B. and Mies G. (2002)** : Ischemic injury in experimental stroke depends on angiotensin II. FASEB J.16:169-176.

**Wixson S. K. and White W. J. (1987)** : A comparison of pentobarbital, Fentanyl-Droperidol, Ketamin-xylazine and ketamine-diazepam anesthesia in adult male rats. Lab. Animal. Sci. 37: 726-730.

**Yalow R. and Berson S. (1971)** : Introduction and general considerations. In: Principles of competitive protein binding assays, eds, Odell WD, Daughaday WH, Lippincott. Co. Philadelphia, pp. 1-19.

**Zanchetti A. and Stella A. (1975)** : Normal control of renin release. Clin. Sci. Mol. Med.; 48 : 215-223.

REPRINT

# BENHA MEDICAL JOURNAL

**PLASMA RENIN ACTIVITY AND  
CEREBRAL ISCHEMIC STROKE  
EXPERIMENTAL AND  
CLINICAL STUDY**

**Mohamed Ahdy A. Saad Ph.D, Amr M. Abbas Ph.D,  
Vivian Boshra Ph.D, Mohamed Elkhateeb MD  
and Ibrahim Abd El Aal MD**

**Published by  
Benha Faculty of Medicine**

*Volume 26 Number 3  
Sept. 2009*

## **DES- $\gamma$ -CARBOXY PROTHROMBIN AS SCREENING MARKER FOR PATIENTS WITH DE NOVO HEPATOCELLULAR CARCINOMA**

**Magdy A. Gad MD, Gamal Elewa MD\*  
and Adel Z. El-Saidy MD\*\***

*Departements of Hepatology, Gastroenterology & Infectious Diseases ,  
Clinical Pathology \* and Pathology \*\*, Faculty of Medicine,  
Benha University, Egypt*

### **Abstract**

**Objectives:** This study aimed to evaluate the predictability of estimation of serum Des- $\gamma$ -carboxyprothrombin (DCP) in cirrhotic and chronic hepatitis C (CHC) patients for the development of de novo hepatocellular carcinoma (HCC) in comparison to alpha-fetoprotein (AFP).

**Patients & Methods:** The study included 90 patients; 30 patients with CHC, 20 patients with HCC and 30 compensated cirrhotic patients and 10 controls. All patients underwent complete clinical examination, radiologic and laboratory assessment. Patients with CHC and cirrhosis were followed up for de novo development of HCC depending on sonography and/or computed tomography (CT). Liver biopsies were done and histopathological inflammatory activity and fibrosis stage of CHC and cirrhotic patients were evaluated according to Scheuer classification and HCC was also graded. All patients and controls gave a fasting blood sample for estimation of serum levels of AFP and DCP.

**Results:** Mean total Scheuer score was non-significantly higher in cirrhotic compared to CHC patients; while mean Scheuer-lobular scores and fibrosis scores were significantly higher but mean Scheuer-portal score was non-significantly lower in cirrhotic compared to CHC patients. Mean serum levels of AFP and DCP were significantly elevated in patients' groups compared to control group and in HCC patients compared to CHC and cirrhosis groups with significantly elevated levels in cirrhotic patients compared to CHC patients. There was a positive correlation between serum levels of both DCP and AFP and total Scheuer score in cirrhotic and CHC groups and HCC pathological grading. Regression analysis of serum levels of DCP and AFP defined DCP as the significant predictor for patho-

logical grading of HCC and the combined use of both markers improved the predictability of AFP. Throughout follow-up period, 4 (13.3%) cirrhotic patients, developed HCC. ROC curve analysis showed that estimation of serum DCP (AUC=0.892) was significantly more specific predictor for de novo HCC than AFP (AUC=0.608). Also ROC analysis defined serum DCP and AFP levels at 38 mAU/ml and 16 ng/ml as specific cutoff point for prediction of de novo HCC with AUC=0.698 and 0.565, specificity rate of 88.7% and 73.6%, accuracy rate of 86.7% and 70%, and sensitivity rate of 71.4% and 42.9%, respectively.

**Conclusion:** Estimation of serum DCP in cirrhotic patients free of HCC could predict de novo development of HCC with higher specificity than AFP but diagnostic validity could be improved by estimation of serum levels of both markers.

### Introduction

Des -  $\gamma$  - carboxyprothrombin (DCP) also known as a protein induced by vitamin K absence or antagonist II (PIVKA-II), is an abnormal product from liver carboxylation that lacks  $\gamma$ -carboxylation of its glutamine residue yielding an abnormal prothrombin. DCP is unable to bind calcium ion that is essential for its conformational transition and functional activity. Because the  $\gamma$ -carboxylation is vitamin K dependent, the DCP protein appears when a patient is in a vitamin K-deficient state, (Suzuki et al., 2005).

Prothrombin precursor has 10 glutamic acid (Glu) residues in the N terminus that are converted

into  $\gamma$ -carboxyl-glutamic acid (Gla) residues by vitamin K-dependent  $\gamma$ -glutamyl carboxylase. All of these Glu residues need to be converted into Gla residues before prothrombin can obtain coagulation activity. In DCP, not all of the 10 Glu residues are transformed to Gla; some remain as Glu residues, (Uehara et al., 1999).

Liebman et al., (1984) reported a relatively high incidence of DCP in HCC patients and suggested that it might be a useful tumor marker of HCC. The exact biochemical defect in HCC has never been clearly identified, although it is thought that vitamin K cannot act as a carboxylase cofactor, leading to a decrease in mature

prothrombin production and an increase in DCP by the HCC; possibly as a result of a vitamin K transport defect (Li et al., 2002). This disturbance is partly dependent on the vitamin K dose available, since in human hepatoma cell lines in culture, this defect could be corrected by addition of exogenous vitamin K, (Wang et al., 1995). The same correction was found after administration of pharmacological doses of vitamin K1 to HCC patients, (Carr et al., 1996). Yoshiji et al., (2005) reported that vitamin K1 could weakly inhibit cell growth in vitro; however, the mechanism(s) for the weak growth inhibitory actions of natural K vitamins have not been identified. Since the major physiological function of K vitamins is to act as a cofactor for carboxylation of prothrombin (factor II) and other K vitamin dependent coagulation factors (VII, IX and X) as well as proteins C and S, prothrombin itself might have growth regulatory activity, (Suzuki et al., 2005).

It is believed that the elevation of the serum DCP level correlates with the presence of vascular invasion or intrahepatic metastases,

(Shirabe et al., 2007). Furthermore, DCP has been reported to be an independent prognostic factor for recurrence and survival after transarterial chemoembolization treatment (Maeda et al., 2002), hepatic resection, (Kai-bori et al., 2004), ablation treatment, (Toyoda et al., 2006a) and liver transplantation (Soejima et al., 2007).

Hepatocellular carcinoma is the most common primary malignancy arising within the liver and almost always in the setting of cirrhosis. HCC is the fifth most common solid tumor in the world that is increasing in incidence and accounts for about 500,000 deaths each year, (Gomaa et al., 2009). Data on the epidemiology and natural history of chronic hepatitis C virus infection show that its frequency has increased over the past 20-30 years especially in the United States and Europe and HCC is the leading cause of death in patients with cirrhosis in Europe, (Thompson et al. 2007). Although only a minority of patients with cirrhosis diagnosed with HCC have tumor amenable to potential curative therapy, all

therapies have best results with single nodules  $\geq 3$  cm in size, (Bruix et al., 2001), including liver transplantation (Burroughs et al., 2004). This clinical scenario has important implications for screening and diagnosing HCC at an early stage, (Ando et al., 2006).

The current study was conducted to evaluate the predictability of estimation of serum DCP in cirrhotic and CHC patients for the development of de novo HCC in comparison to AFP.

### **Patients & Methods**

The present study was conducted at Departments of Hepatology, Gastroenterology & Infectious Diseases and Clinical Pathology, Faculty of Medicine, Benha University since June 2006 till June 2009 to allow a minimum follow-up period of 6 month for the last enrolled patient.

This study included 30 patients with chronic hepatitis C (CHC group) infection persisting for longer than 6 months with HCV antibody positive and increased serum ALT values and ra-

diological assessment excluded the presence of any evidence of cancer. After complete history taking and full clinical examination, all patients were subjected to the following investigations: urine & stool analysis, complete blood picture, rectal biopsy for diagnosis of Bilharziasis, ultrasonographic scanning for the abdomen and ELISA test for hepatitis C virus antibodies (HCVab) (Arash et al., 1993) for confirmation of inclusion criteria.

The second group (HCC group) included 20 patients with HCC that was histologically confirmed. Tumor size was estimated by using ultrasonography and/or CT and patients who had advanced HCC with tumor size  $>3$  cm or patients with portal vein invasion were excluded. Blood samples from HCC patients were drawn before initial treatment. All HCC patients underwent determination of hepatitis B surface antigen (HBsAg), antibody to HCV (anti-HCV) and serum levels of ALT, albumin, total bilirubin, and platelet count and prothrombin time.

Thirty compensated cirrhosis



(modified Child-Pugh score <7) patients were also enrolled in the study (Cirrhosis group); cirrhosis was defined by clinical development of esophageal varices, thrombocytopenia (platelet count less than  $100\ 000/\text{mm}^3$ ), splenomegaly or small liver size with irregular liver surface to be noted by imaging studies at enrollment. Among all patients with chronic hepatitis and cirrhosis, HCC was ruled out depending on sonography and/or CT performed on a regular examination through out the follow-up period till end of the study and at least for 6 months. The study also included 10 volunteers to donate blood samples as Control group.

Patients on chronic use of non-steroidal anti-inflammatory drugs, aspirin, and anticoagulants or had concomitant other non-gastroenterologic diseases, in particular, rheumatoid arthritis or other connective tissue inflammatory diseases were excluded of the study. Patients with prothrombin concentration <60% of the control, serum total bilirubin level >20 mg/l, decompensated liver disease or on vitamin K ther-

apy were also excluded of the study.

Ultrasound guided liver biopsies were done by means of true cut needle. Histopathological inflammatory activity (grading, 0-4 scale, Table 1) and fibrosis stage (staging, 0-4 scale, Table 2) were evaluated according to Scheuer classification, (Scheuer, 1991). HCC was histopathologically graded according to the criteria proposed by the Liver Cancer Study Group of Japan (1990) into well differentiated, moderately differentiated, or poorly differentiated.

Whole blood (5ml) was obtained from patients and controls prior to initiation of therapy, irrespective of the diagnosis. Blood samples were collected in plain tube and allowed to clot and centrifuged at 5000 rpm for 10 minutes and serum was collected and stored at  $-80^{\circ}\text{C}$  till assayed for determination of :

1. Serum level of AFP using the commercially available immunometric assay (Architect AFP assay, Abbott Laboratories, North Chicago, IL, USA). The cut-off value of AFP for HCC was set at 20 ng/

ml; the most commonly set value (Trevisani et al., 2001).

2. Serum level of DCP was measured by using an ELISA (Eitest PIVKAI, Eisai Co., Tokyo, Japan), according to the manufacturer's instructions. The detection limit is 10 mAU/ml, with value of 40 mAU/ml as cutoff point for differentiation of HCC and non-malignant liver disease based on previous studies (Okuda et al., 1999).

3. Serum levels of ALT, total bilirubin and albumin were done by routine methods.

4. Hepatitis markers for HbsAg and HCV antibodies using ELISA technique

#### **Statistical analysis :**

Obtained data were presented as mean±SD, ranges, numbers and ratios. Results were analyzed using paired t-test and Chi-square test. Possible relationships were investigated using Pearson linear regression. Regression analysis using Stepwise method was used to test the predictability of estimated parameters for de novo HCC. Test validity characters and cutoff points were evaluated using

the receiver operating characteristic (ROC) curve analysis judged by the area under the curve (AUC). Statistical analysis was conducted using the SPSS (Version 10, 2002) for Windows statistical package. P value <0.05 was considered statistically significant.

### **Results**

The study included 90 patients; 55 males (61.1%) and 35 females (38.9%) and 10 controls; 7 males and 3 females with a non-significant difference between patients and controls as regards sex distribution, ( $X^2=0.146$ ,  $p>0.05$ ). Mean age of studied patients was  $47.5\pm 8.7$ ; range: 26-64 years, while mean age of controls was  $49.7\pm 12.5$ ; range: 29-66 years, with a non-significant ( $p>0.05$ ) difference between both groups.

Mean total Scheuer score was  $5.6\pm 2.37$ ; range: 2-10 in CHC patients, while patients with cirrhosis had mean total Scheuer score of  $6.5\pm 1.48$ ; range: 4-9 with a non-significantly ( $p>0.05$ ) higher total Scheuer score in patients with cirrhosis compared to those with CHC, (Fig. 1). As regards differential items, mean Scheuer-

lobular scores and Scheuer-fibrosis scores were significantly higher ( $p=0.016$  &  $0.026$ , respectively), while mean Scheuer-portal score was non-significantly ( $p>0.05$ ) lower in patients with cirrhosis compared to those had CHC, (Table 3, Fig. 2). There were 12 patients with well differentiated HCC, 4 patients with moderately differentiated and 4 patients had poorly differentiated.

Mean serum levels of DCP, (Fig. 3) and AFP, (Fig. 4) were significantly elevated in patients' groups compared to control group and in HCC patients compared to CHC and cirrhosis groups with significantly elevated levels in cirrhotic patients compared to CHC patients, (Table 4).

There was a positive correlation between serum levels of both DCP and AFP and total Scheuer score in cirrhotic and CHC groups. On contrary, there was positive correlation between serum levels of DCP and AFP with the pathological grading of HCC, however, the correlation was positive with DCP and non-significant with AFP, (Table 5). Using regression analysis of

serum levels of DCP and AFP to define the predictor for pathological grading of HCC defined DCP as the significant predictor ( $F=6.216$ ,  $p=0.009$ ) but the combined use of both markers improved the predictability of AFP ( $F=9.950$ ,  $p=0.005$ ).

Throughout the study period, follow-up investigations detected 4 (13.3%) cirrhotic patients developed HCC. Using ROC curve analysis, with a null hypothesis that the true area under curve=0.5, showed that estimation of serum DCP was significantly ( $p=0.023$ ) more specific predictor for the presence of HCC, irrespective of the underlying pathology, with  $AUC=0.892$ , while specificity of AFP as a predictor showed non-significant ( $p>0.05$ ) difference compared to the true area with  $AUC=0.608$ , (Table 6, Fig. 5).

Also using ROC analysis for verification of serum DCP and AFP cutoff points above which malignant lesion could be predicted defined serum DCP level at 38 mAU/ml as more specific cutoff point with  $AUC=0.698$ , sensitivity rate of 71.4%, specificity rate of 88.7%

and accuracy rate of 86.7%, while DCP levels at cutoff point of 37 mAU/ml showed AUC=0.614, sensitivity rate of 85.4%, specificity rate of 84.9% and accuracy rate of 85%. For AFP serum cutoff point at 16 ng/ml was the most specific cutoff point with AUC=0.565, specificity rate of 73.6% and accuracy rate of 70% but showed sensitivity rate of 42.9%, while cutoff point at 12 ng/ml showed higher sensitivity rate (71.4%) with low specificity and accuracy rates, 32.1% and 36.7%, respectively and AUC=0.472, (Table 7).

**Table (1):** Scoring Necro-inflammatory activity of chronic hepatitis.

Grade	Portal/periportal activity	Lobular activity
0	None or minimal	None
1	Portal inflammation	Inflammation but no necrosis
2	Mild piecemeal necrosis (mild chronic active hepatitis; CAH)	Focal necrosis or acidophilic bodies
3	Moderate piecemeal necrosis (moderate CAH)	Severe focal cell damage
4	Severe piecemeal necrosis (severe CAH)	Damage includes bridging necrosis

**Table (2):** Scoring Fibrosis and Cirrhosis.

Stage	
0	None
1	Enlarged, fibrotic portal tracts
2	Periportal or portal-portal septa but intact architecture
3	Fibrosis with architectural distortion but no obvious cirrhosis
4	Probable or definite cirrhosis

**Table (3):** Mean Scheuer scores of studied patients categorized according to histopathological examination of liver biopsies.

	CHC (n=30)	Cirrhosis (n=30)
Scheuer-portal score	2.23±1 (1-4)	2±0.87 (1-4)
Scheuer-lobular score	1.13±0.73 (0-3)	1.67±0.76 (1-3) †
Scheuer-fibrosis score	2.23±1.33 (0-4)	2.83±0.83 (2-4) †
Total Scheuer score	5.6±2.37 (2-10)	6.5±1.48 (4-9)

†: significant difference versus CHC group

**Table (4):** Mean ( $\pm$ SD) serum levels of AFP and DCP estimated in studied groups.

	AFP (ng/ml)	DCP (mAU/ml)
Control group	5 $\pm$ 2.6	12.7 $\pm$ 1.2
CHC group	12 $\pm$ 5.9*	22.3 $\pm$ 7.3*
HCC group	6105.1 $\pm$ 26935* $\ddagger$	1680.3 $\pm$ 500.8* $\ddagger$
Cirrhosis group	15 $\pm$ 5.2* $\ddagger$	33.3 $\pm$ 12.7* $\ddagger$

\*: significant difference versus Control group.  $\ddagger$ : significant difference versus CHC group  
 $\ddagger$ : significant difference versus Cirrhosis group

**Table (5):** Correlation coefficient of serum levels of AFP and DCP estimated in studied groups and histopathological grading.

	AFP (ng/ml)		DCP (mAU/ml)	
	"r"	p	"r"	p
CHC group	0.200	>0.05	0.315	>0.05
Cirrhosis group	0.235	>0.05	0.460	=0.011
HCC group	0.327	>0.05	0.597	=0.005

**Table (6):** AUC for serum DCP and AFP levels as specific predictor for HCC.

	AUC	Std Error	P value	95% confidence interval	
				Lower	Upper
DCP	0.892	0.057	0.023	0.781	1.003
AFP	0.608	0.198	>0.05	0.220	0.996

AUC: area under curve

Std Error: standard error

**Table (7):** AUC and sensitivity, specificity and accuracy rates for probable cutoff points of serum DCP and AFP levels for discrimination between HCC and non-HCC hepatic lesions.

	Cutoff point	AUC	Sensitivity rate	Specificity rate	Accuracy rate
Serum DCP	37 mAU/ml	0.614	85.7%	84.9%	85%
	38 mAU/ml	0.698	71.4%	88.7%	86.7%
Serum AFP	12 ng/ml	0.472	71.4%	32.1%	36.7%
	16 ng/ml	0.565	42.9%	73.6%	70%

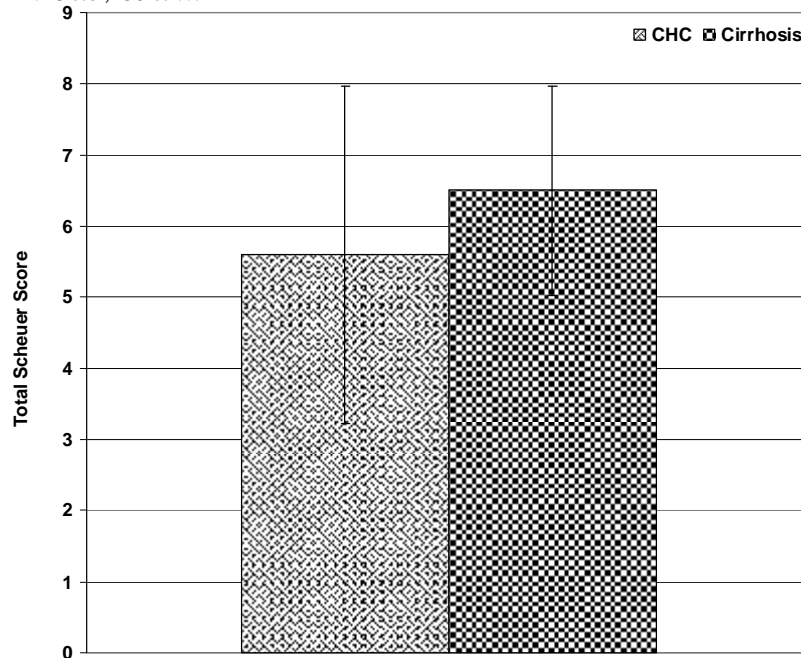


Fig. (1): Mean ( $\pm$ SD) total Scheuer score defined in CHC and Cirrhosis patients

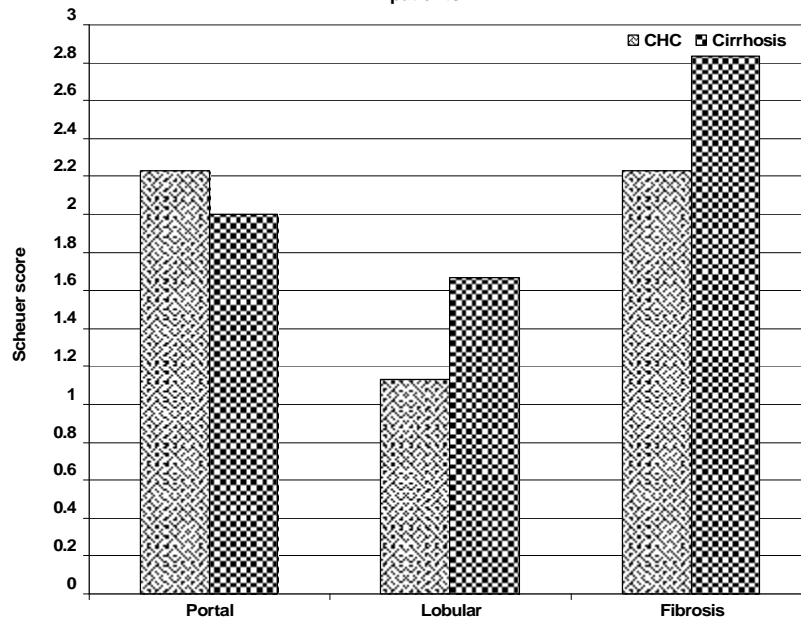


Fig. (2): Mean differential Scheuer scores defined in CHC and cirrhosis patients

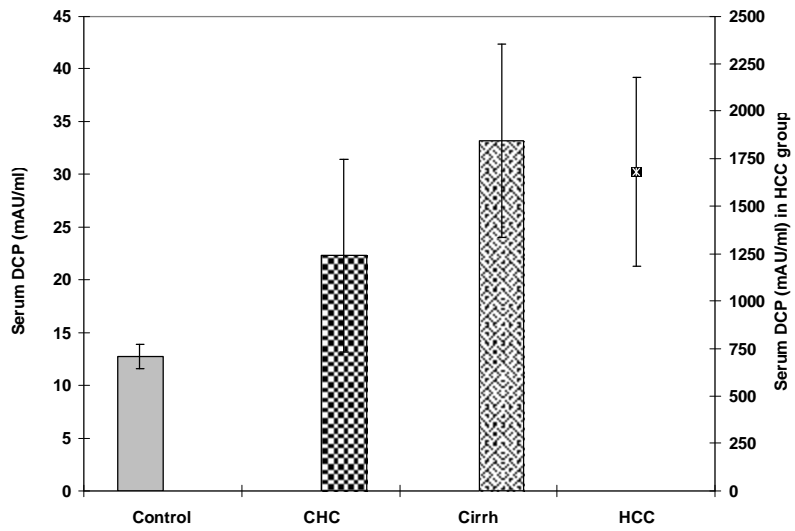


Fig. (3): Mean ( $\pm$ SD) level of DCP estimated in studied patients' groups

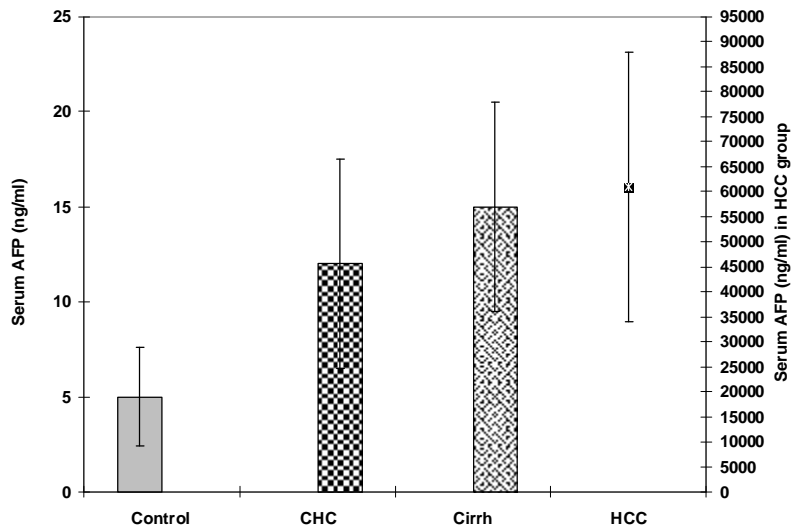


Fig. (4): Mean ( $\pm$ SD) level of AFP estimated in studied patients' groups

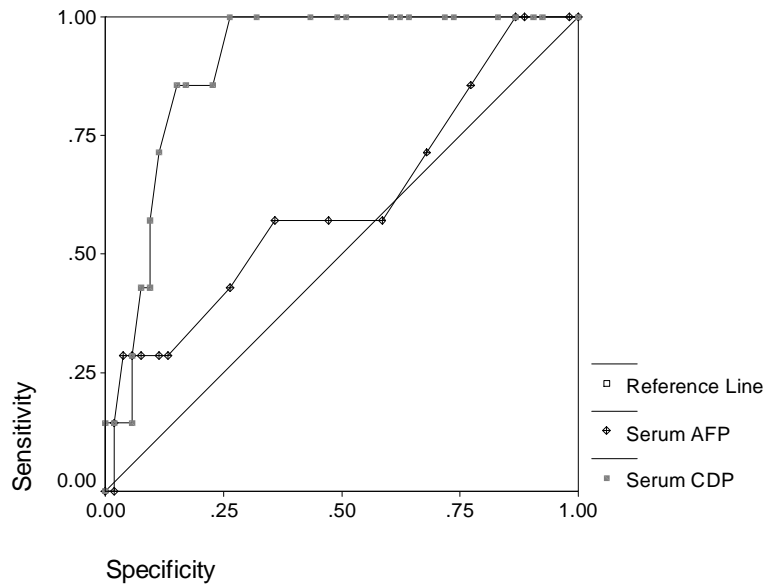


Fig. (5): ROC curve analysis of serum CDP and AFP as predictor for development of malignant hepatic lesions.

### Discussion

The present study was based as two-arm survey including healthy volunteers as negative control group and patients with histologically documented HCC as positive control group to compare serum levels of AFP and DCP in cirrhotic and CHC patients. Both markers showed significantly higher serum levels in patients compared to control group and in HCC compared to cirrhotic and hepatitis patients with significantly higher levels in cirrhosis patients compared to hepatitis patients.

These finding illustrate the impact of lesion type and progression of disease status on the serum levels of both markers and indicated the applicability of both parameters as markers for liver endangerment. Similarly, Durazo et al. (2008) found levels of both DCP and AFP were significantly higher in patients with HCC than in those without HCC.

In support of these data, the present study detected a positive significant correlation between serum levels of DCP and total Scheuer score in cirrhotic and



pathological grading of HCC, but the correlation was non-significant in CHC groups. On contrary, these correlations were positive non-significant correlation with AFP. Serum DCP was found as a significant predictor for pathological grade, while AFP was non-significant, but the predictability of these markers for HCC grading was improved on using combination of these markers. These findings go in hand with Toyoda et al., (2006b) who evaluated the significance of simultaneous measurement of AFP, Lens culinaris agglutinin A-reactive fraction of AFP (AFP-L3), and DCP in the evaluation of tumor progression and prognosis of patients with HCC and found AFP-L3 and DCP appear to represent different features of tumor progression in patients with HCC and could be useful for the evaluation of tumor progression, prediction of patient outcome, and treatment efficacy. Also, Murakami et al., (2008) found DCP is the most useful prognostic tumor marker in HCC patients and Tateishi et al., (2008) found diagnostic accuracy of AFP in small HCC was substantially limited and surveillance including

DCP with optimal cutoff value should be conducted to confirm the efficacy of the policy. Kim et al., (2009) found serum PIVKA-II level, not serum AFP, was a valuable independent prognostic factor in HBV-related HCC.

Throughout follow-up, 4 cirrhotic patients (13.3%) developed HCC; such frequency of de novo HCC goes in hand with Sterling et al., (2008) who followed-up 298 patients with hepatitis C virus-related cirrhosis for 2 years and reported that HCC developed in 34 of 298 (11.4%) who were free of HCC at entry and with Brady et al., (2009) who reported a frequency rate of de novo HCC of 13.6%, in cirrhotic patients waiting for liver transplantation.

The ROC curve analysis showed that estimation of serum DCP was significantly ( $p=0.023$ ) more specific predictor for the presence of HCC, irrespective of the underlying pathology, with  $AUC=0.892$  than serum AFP that showed an  $AUC=0.608$ . Moreover, for prediction of development of malignant lesion, serum DCP and AFP levels at  $\geq 38$  mAU/ml and 16

ng/ml, respectively, were the most specific cutoff points with AUC= 0.698 and 0.565, respectively. These data goes in hand with Okuwaki et al., (2008) who found serum DCP level  $\geq 40$  mAu/ml, local tumor progression, and ablative margin  $< 5$  mm were related to multiple intrahepatic distant recurrence and recommended careful follow-up to monitor any intrahepatic distant recurrence in HCC patients with high serum DCP.

Moreover, Sterling et al., (2008) found DCP levels have higher correlation values with an absence of HCC, as well as a higher specificity and negative predictive value, than total AFP and the combination of DCP and AFP-L3 could identify individuals with negative imaging results who would benefit from follow-up evaluation. Marre-ro et al., (2009) tried to determine performance of DCP and AFP-L3% for the diagnosis of early HCC and what factors affect DCP, AFP-L3%, or AFP levels and found AFP had the best sensitivity, but at the expense of specificity, followed by DCP and AFP-L3% for early stage HCC. Baek et al., (2009) found PIVKA-II is a useful marker for de-

tecting HCC, especially in small HCC and have correlations with known staging systems.

Despite the diagnostic and prognostic value of estimation of serum DCP in patients with HCC, the mechanisms for its production still a matter of debate; Bertino et al., (2008) reported that DCP detectable serum levels are the result not only of vitamin K deficiency or selective defects of carboxylase, because probably alterations of membrane receptors or cytoplasmatic transfers, that are necessary for the function of vitamin K, are involved. On the other hand, Ma et al., (2009) tried to examine in vivo the efficacy of vitamin K2 on the production of DCP as well as tumor cell growth and invasion and found vitamin K2 might suppress the growth and invasion of HCC cells via decrease of DCP.

However, Murata et al., (2008) hypothesized that DCP might be produced from HCC cells with functional impairment of vitamin K uptake and showed in vitro that cytoskeletal filament change by epithelial to fibroblastoid conver-

sion is crucial for DCP production in HepG2 cells.

It could be concluded that estimation of serum DCP in cirrhotic and CHC patients free of HCC could predict the de novo development of HCC with high specificity but its diagnostic validity could be improved by combination with AFP serum level estimation. However, wider-scale studies were advocated for establishment of valid cutoff points.

### References

**Ando E., Kuromatsu R., Tanaka M., Takada A., Fukushima N., Sumie S., Nagaoka S., Akiyoshi J., Inoue K., Torimura T., Kumashiro R., Ueno T. and Sata M. (2006)** : Surveillance program for early detection of hepatocellular carcinoma in Japan: results of specialized department of liver disease. *J Clin Gastroenterol.*; 40 (10):942-8.

**Arash G., Czeslaw W., Lin C., Feinstone S. M. and Rice C. M. (1993)** : Expression and identification of hepatitis C virus polyprotein cleavage products. *J. Virol.*; P:1385.

**Baek Y. H., Lee J. H., Jang J. S., Lee S. W., Han J. Y., Jeong J. S., Choi J. C., Kim H. Y. and Han S. Y. (2009)** : Diagnostic role and correlation with staging systems of PIVKA-II compared with AFP. *Hepatogastroenterology.*; 56 (91-92):763-7.

**Bertino G., Ardiri A. M., Boemi P. M., Ierna D., Interlandi D., Caruso L., Minona E., Trovato M. A., Vicari S., Li Destri G. and Puleo S. (2008)** : A study about mechanisms of des-gamma-carboxy prothrombin's production in hepatocellular carcinoma. *Panminerva Med.*; 50(3):221-6.

**Brady C. W., Smith A. D., Stechuchak K. M., Coffman C. J., Tuttle-Newhall J. E., Provenzale D. and Muir A. J. (2008)** : Frequency and predictors of de novo hepatocellular carcinoma in patients awaiting orthotopic liver transplantation during the model for end-stage liver disease era. *Liver Transpl.*; 14(2):228-34.

**Bruix J., Sherman M., Llovet J. M., Beaugrand M., Lencioni R., Burroughs A. K, et al., (2001)** : EASL Panel of Experts on

HCC. Clinical management of hepatocellular carcinoma. Conclusion of the Barcelona-2000 EASL Conference. *J Hepatol*, 35:421-30.

**Burroughs A. K., Hochhauser D. and Meyer T. (2004)** : Hepatocellular carcinoma: systemic therapy and liver transplantation two ends of the spectrum, *Lancet Oncology*; 5:409-418.

**Carr B. I. (1996)** : Vitamin K inhibits hepatoma growth in vitro and in patients. *Proc AACR*; 37:1485.

**Durazo F. A., Blatt L. M., Corey W. G., Lin J. H., Han S., Saab S., Busuttil R. W. and Tong M. J. (2008)** : Des-gamma-carboxyprothrombin, alpha-fetoprotein and AFP-L3 in patients with chronic hepatitis, cirrhosis and hepatocellular carcinoma. *J Gastroenterol Hepatol.*; 23 (10): 1541-8.

**Gomaa A. I., Khan S. A., Leen E. L., Waked I. and Taylor-Robinson S. D. (2009)** : Diagnosis of hepatocellular carcinoma. *World J Gastroenterol.*; 15 (11):1301-14.

**Kaibori M., Matsui Y., Yanagida H., Yokoigawa N., Kwon A. H. and Kamiyama Y. (2004)** : Positive status of alpha-fetoprotein and desgamma-carboxy prothrombin: important prognostic factor for recurrent hepatocellular carcinoma. *World J Surg*; 28: 702-7.

**Kim H. S., Park J. W., Jang J. S., Kim H. J., Shin W. G., Kim K. H., Lee J. H., Kim H. Y. and Jang M. K. (2009)** : Prognostic values of alpha-fetoprotein and protein induced by vitamin K absence or antagonist-II in hepatitis B virus-related hepatocellular carcinoma: a prospective study. *J Clin Gastroenterol.*; 43(5):482-8.

**Li F., He F., Stehle C. J., Wang Z., Kar S., Finn F. M. and Carr B. I. (2002)** : Vitamin K uptake in hepatocytes and hepatoma cells. *Life Sciences*; 70:2085-100.

**Liebman H. A., Furie B. C., Tong M. J., Blanchard R. A., Lo K. J., Lee S. D., Coleman M. S. and Furie B. (1984)** : Des-gamma-carboxy (abnormal) prothrombin as a serum marker of primary hepatocellular carcinoma. *N Engl J Med*; 310: 1427-31.

**Liver Cancer Study Group of Japan. Primary liver cancer in Japan (1990)** : Clinicopathologic features and results of surgical treatment. *Ann Surg*; 211: 277-87.

**Ma M., Qu X. J., Mu G. Y., Chen M. H., Cheng Y. N., Koku-do N., Tang W. and Cui S. X. (2009)** : Vitamin K2 inhibits the growth of hepatocellular carcinoma via decrease of des-gamma-carboxy prothrombin. *Chemotherapy*;55(1):28-35.

**Maeda S., Fujiyama S., Tanaka M., Ashihara H., Hirata R. and Tomita K. (2002)** : Survival and local recurrence rates of hepatocellular carcinoma patients treated by transarterial chemolipiodolization with and without embolization. *Hepatol Res*; 23 : 202-10.

**Marrero J. A., Feng Z., Wang Y., Nguyen M. H., Befeler A. S., Roberts L. R., Reddy K. R., Harnois D., Llovet J. M., Normolle D., Dalhgren J., Chia D., Lok A. S., Wagner P. D., Srivastava S. and Schwartz M. (2009)** : Alpha-fetoprotein, des-gamma carboxy-

prothrombin, and lectin-bound alpha-fetoprotein in early hepatocellular carcinoma. *Gastroenterology*.; 137(1):110-8.

**Murakami N., Tamano M., Yoneda M., Sugaya H. and Hiraishi H. (2008)** : Des-gamma-carboxy prothrombin (DCP) ratio is a useful prognostic tumor marker for single nodule hepatocellular carcinoma (HCC). *Hepatogastroenterology*.; 55(81):197-201.

**Murata K. and Sakamoto A. (2008)** : Impairment of clathrin-mediated endocytosis via cytoskeletal change by epithelial to fibroblastoid conversion in HepG2 cells: a possible mechanism of des-gamma-carboxy prothrombin production in hepatocellular carcinoma. *Int J Oncol*.; 33(6):1149-55.

**Okuda H., Nakanishi T., Takatsu K., Saito A., Hayashi N. and Watanabe K. (1999)** : Measurement of serum levels of des-gamma-carboxy prothrombin in patients with hepatocellular carcinoma by a revised enzyme immunoassay kit with increased sensitivity. *Cancer*; 85: 812-8.

**Okuwaki Y., Nakazawa T., Shibuya A., Ono K., Hidaka H., Watanabe M., Kokubu S. and Saigenji K. (2008)** : Intrahepatic distant recurrence after radiofrequency ablation for a single small hepatocellular carcinoma: risk factors and patterns. *J Gastroenterol.*;43(1):71-8.

**Scheuer P. J. (1991)** : Classification of chronic viral hepatitis: a need for reassessment. *J Hepatol.*; 13: 372-4.

**Shirabe K, Itoh S, Yoshizumi T, Soejima Y, Taketomi A, Aishima S, Maehara Y. (2007)** : The predictors of microvascular invasion in candidates for liver transplantation with hepatocellular carcinoma-with special reference to the serum levels of desgamma-carboxy prothrombin. *J Surg Oncol*; 95: 235-40.

**Soejima Y., Taketomi A., Yoshizumi T., Uchiyama H., Aishima S., Terashi T., Shimada M. and Maehara Y. (2007)** : Extended indication for living donor liver transplantation in patients with hepatocellular carcinoma. *Transplantation*; 83: 893-9.

**Sterling R. K., Jeffers L., Gordon F., Venook A. P., Reddy K. R., Satomura S., Kanke F., Schwartz M. E. and Sherman M. (2009)** : Utility of Lens culinaris agglutinin-reactive fraction of alpha-fetoprotein and des-gamma-carboxy prothrombin, alone or in combination, as biomarkers for hepatocellular carcinoma. *Clin Gastroenterol Hepatol.*; 7(1):104-13.

**Suzuki M., Shiraha H., Fujikawa T., Takaoka N., Ueda N., Nakanishi Y., Koike K., Takaki A. and Shiratori Y. (2005)** : Des-gamma-carboxy prothrombin is a potential autologous growth factor for hepatocellular carcinoma. *J Biol Chem*; 280: 6409-15.

**Tateishi R., Yoshida H., Matsuyama Y., Mine N., Kondo Y. and Omata M. (2008)** : Diagnostic accuracy of tumor markers for hepatocellular carcinoma: a systematic review. *Hepatol Int.*; 2 (1):17-30.

**Thompson Coon J., Rogers G., Hewson P., Wright D., Anderson R., Cramp M., Jackson S., Ryder S., Price A. and Stein K.**

(2007) : Surveillance of cirrhosis for hepatocellular carcinoma: systematic review and economic analysis. *Health Technol Assess.*;11 (34):1-206.

**Toyoda H., Kumada T., Osaki Y., Oka H., Urano F., Kudo M. and Matsunaga T. (2006a)** : Staging hepatocellular carcinoma by a novel scoring system (BALAD score) based on serum markers. *Clin Gastroenterol Hepatol*; 4: 1528-36.

**Toyoda H., Kumada T., Kiri-yama S., Sone Y., Tanikawa M., Hisanaga Y., Yamaguchi A., Iso-gai M., Kaneoka Y. and Washizu J. (2006b)** : Prognostic significance of simultaneous measurement of three tumor markers in patients with hepatocellular carcinoma. *Clin Gastroenterol Hepatol.*;4(1):111-7.

**Trevisani F., D'Intino P. E., Morselli-Labate A. M., Mazzella G., Accogli E. and Caraceni P. (2001)** : Serum alpha-fetoprotein for diagnosis of hepatocellular

carcinoma in patients with chronic liver disease: influence of HBsAg and anti-HCV status. *J Hepatol*; 34: 570-5.

**Uehara S., Gotoh K., Handa H., Honjo K. and Hirayama A. (1999)** : Process of carboxylation of glutamic acid residues in the gla domain of human des-gamma-carboxyprothrombin. *Clin. Chim. Acta.*; 289: 33-44.

**Wang Z., Wang M., Finn F. and Carr B. I. (1995)** : The growth inhibitory effects of vitamin K and their actions on gene expression. *Hepatology*; 22:876-881.

**Yoshiji H., Kuriyama S., Noguchi R., Yoshiji J., Ikenaka Y., Yanase K., Namisaki T., Kitade M., Yamazaki M., Masaki T. and Fukui H. (2005)** : Combination of vitamin K2 and the angiotensin-converting enzyme inhibitor, perindopril, attenuates the liver enzyme-altered preneoplastic lesions in rats via angiogenesis suppression. *J Hepatol*; 42:687-93.

REPRINT

# **BENHA MEDICAL JOURNAL**

**DES- $\gamma$ -CARBOXY PROTHROMBIN  
AS SCREENING MARKER FOR  
PATIENTS WITH DE NOVO  
HEPATOCELLULAR  
CARCINOMA**

**Magdy A. Gad MD, Gamal Elewa MD  
and Adel Z. El-Saidy MD**

**Published by  
Benha Faculty of Medicine**

*Volume 26 Number 3  
Sept. 2009*



## **THE APPLICABILITY OF BIOMARKERS FOR DIFFERENTIATION OF INVERTED PAPILLOMA WITH DIFFERENT PATHOLOGICAL DIAGNOSES**

**Ahmed S. El-Kady MD, Kassem M. Kassem MD,  
Abou-Bakr E. Ras, MD, Adel F. Al-Kholy MD\*  
and Abdel Latif El-Balshy MD\*\***

*Departments of Otorhinolaryngology, Medical Biochemistry\*  
& Pathology\*\*, Faculty of Medicine, Benha University, Egypt*

### **Abstract**

**Objectives:** *The present study aimed to estimation of tissue extract epidermal growth factor receptor (EGFR) and serum squamous cell carcinoma antigen (SCCA) levels in patients with inverted papilloma (IP) in varied pathological states as a trial to determine their role in pathogenesis and/or their applicability for differentiation between these different pathological changes.*

**Patients & Methods:** *The study included 6 cases with primarily diagnosed IP, 4 cases with recurrent IP and 3 cases had IP with SCC and 10 healthy volunteers to give blood samples as control group. All patients underwent full history taking, general and local examination and CT imaging was conducted. All cases underwent endoscopical excision and freshly excised IP tissues were divided into two parts; the first for histopathological examination and the second was immediately frozen on dry ice and stored in liquid nitrogen at -70°C until processed for estimation of tissue extract level of EGFR. Venous blood samples were obtained prior to and after surgical resection for ELISA estimation of serum SCCA.*

**Results:** *The study included 13 patients; 10 males and 3 females, with mean age of 62.4±6.2 years. Nasal obstruction was the main presenting symptom followed by epistaxis and headache. Patients with recurrent IP gave history of previous endoscopic removal since a mean duration of 6.2±2.2 months and one patient had recurrent IP twice. Histopathological examination documented the diagnosis of benign IP in 10 cases and SCC changes in 3 IP. Mean EGFR levels estimated in tissue extract of IP with SCC was significantly higher compared to benign IP with significantly higher levels in recurrent IP compared to primary IP.*

*Preoperative serum SCCA levels were significantly higher in patients had IP with SCC compared to levels in controls and patients with benign IP and in sera of patients had recurrent IP compared to controls and patients had primary IP. Postoperative serum SCCA levels were significantly lower compared to preoperative levels in all patients' groups and in patients with benign IP nearly returned to control levels, while in patients with cancerous changes postoperative serum SCCA levels were still significantly higher compared to control levels and non-significantly higher compared to levels estimated in patients with benign IP.*

**Conclusion:** *EGFR tissue expression level could be used for differentiation between benign and malignant IP even in early phases of dysplasia and serum SCCA could be used as a marker for complete operative excision of IP irrespective of its pathological diagnosis.*

### **Introduction**

The respiratory tract comprises several distinct anatomical sections including the nasal cavity, paranasal sinuses, nasopharynx, oropharynx, hypopharynx, larynx, trachea, and bronchi. The epithelial lining in the major part of the respiratory tract is composed of respiratory epithelium (columnar cells), whereas stratified squamous epithelium covers the mucosa of the pharynx and a part of the larynx, (Syrjänen, 2000a). This coexistence of two different epithelia creates squamo-columnar junctions at multiple sites in the respiratory tract, entities that are thought to be a prerequisite for the spread of human papilloma virus infections in this region, (Syrjänen,

2000b). Because of this divergent histology of the mucosal lining, a wide variety of both benign and malignant tumors arises in the respiratory tract, (Kraft et al., 2001).

Epidermal growth factor receptor (EGFR) is composed of extracellular domains, including a ligand-binding domain, a hydrophobic transmembrane region and a tyrosine kinase-containing cytoplasmic region. Stimulation of the EGFR by endogenous ligands, EGF or transforming growth factor- $\alpha$  (TGF- $\alpha$ ) results in a conformational change in the receptor, permitting its dimerization and subsequent activation of intracellular tyrosine kinase, protein phosphorylation and stimulation

of various cell signaling pathways that mediate gene transcription and cell cycle progression, (Penaull-Llorca et al., 2003). The EGFR is expressed on normal human cells especially in injured tissues to aid wound healing, (Avisar et al., 2000); but higher levels of expression of the receptor have also been shown to be correlated with malignancy in a variety of cancers. The activation of the EGFR participates in oncogenesis by inducing cell proliferation, cell mobility and angiogenesis, and inhibiting apoptosis. This activation might be due to numerous abnormalities, including increased expression of its ligand, (Pysrri et al., 2005).

Soluble isoforms of the epidermal growth factor receptor (sEGFR) have been identified in the conditioned culture media of the vulvar adenocarcinoma cell line; the constitutive shedding of EGFR was inhibited by metalloprotease inhibitors and by the aspartyl inhibitors. This shedding of sEGFR arises by proteolytic cleavage of EGFR via a mechanism that is regulated by both protein kinase C and phosphoryla-

tion-dependent pathways and suggested that when proteolytic shedding of EGFR does occur, it is correlated with a highly malignant phenotype, (Perez-Torres et al., 2008).

The squamous cell carcinoma antigen (SCCA) is a group of glycoproteins with molecular weight ~45 kDa, belonging to the family of serine/cysteine -protease inhibitors (Suminami et al., 1991). SCCA first was isolated biochemically from SCC tissue of the uterine cervix and consists of at least 10 sub-fractions differing in isoelectric point (Kato & Torigoe, 1977). Thereafter, molecular studies have demonstrated that SCC antigen is transcribed by two nearly identical genes; SCCA1 and SCCA2, (Schneider et al., 1995) both are protease inhibitors that map to the serine protease inhibitor (serpin) cluster at 18q21. These gene products are expressed in SCC tissues as well as normal squamous epithelium (Cataltepe et al., 2000).

The exophytic and inverted growth pattern found microscopically in IP tissue is often confused

with sinonasal adenocarcinomas which contain only single-layered epithelium. Clinically, its behavior parallels inverted papillomas due to local recurrence and coexistence of malignancy, (Lui et al., 2004). However, neither the etiology nor pathogenesis of these tumors nor the putative role as a precursor to carcinoma and the factors responsible for associated malignancy has been clarified. Whether carcinomas in inverted papillomas arise meta- or synchronous is also still unknown, (Mirza et al., 2007).

Moreover, postoperative long-term follow-up of IP patients is recommended, and/or the establishment of a biologic marker reflecting the extent of disease can be of great help to the clinician. In the search for new biologic markers for IP, therefore, the present study was designed for estimation of tissue extract EGFR and serum SCCA levels in patients with IP in varied pathological states as a trial to determine their role in pathogenesis and / or their applicability for differentiation between these different pathological changes.

### **Patients & Methods**

This prospective study was conducted at Otorhinolaryngology department, Benha University hospital throughout the duration since July 2007 till June 2009. The study included 10 healthy volunteers had been consented and selected from those attending Benha Hospital Blood Bank for blood donation to give blood samples as control group.

The current prospective comparative study was designed on observational basis for collections of IP in varied pathological states. After approval of the study protocol by the Local Ethical Authority and obtaining fully informed patients' consent; 6 cases with primarily diagnosed IP, 4 cases with recurrent IP and 3 cases had IP with SCC changes were enrolled in the study. All patients underwent full history taking, general and local examination (Fig. 1). CT imaging (Fig. 2) was conducted and its results were verified according to Lund & Lloyd, (2000).

Prior to surgery, a biopsy was performed endoscopically under local anesthesia. General anesthe-

sia was used during the resection. A pack of cotton soaked with epinephrine at a concentration of 1:100,000 was used to induce vasoconstriction. Using the rigid 0° and 30° sinus endoscopes, en bloc resection was attempted in small tumors when the origin of the growth was identified. When this was unclear and the tumor filled the nasal cavity, parts of the tumor not involving the nasal cavity mucosa were debulked in order to further anatomically delineate the origin of the tumor's growth. Once located, an en bloc excision of the tumor through medial maxillectomy, with as wide a margin as possible, was performed. Secured margins were confirmed by frozen section. Nearby tissue suspected of involvement with the tumor was resected and sent for frozen section. Vaseline nasal pack were placed for 48 hours.

Freshly excised IP or taken biopsy tissues were divided into two parts; the first was examined histopathologically using H&E stain, according to the World Health Organization classification (Shanmugaratnam & Sobin, 1991) and fungiform papillomas and cylindrical

cell papillomas were excluded from the study. The second was immediately frozen on dry ice and stored in liquid nitrogen at -70°C until processed. Tumor specimens were finely minced and homogenized in 5 volumes of ice-cold buffer consisting of 25 mM Tris, 1.5 mM EDTA, 5 mM NaN<sub>3</sub>, 0.1% monothiolglycerol, and 20% glycerol by applying several intermittent bursts of an Ultra-turrax homogenizer. The crude homogenate was centrifuged at 7000 rpm for 20 min at 0°C, and the supernatant was further centrifuged at 105 rpm for 75 min at 0°C to obtain a membrane fraction for EGFR assay. The membrane pellet was resuspended in 25 mM Tris, 1.5 mM EDTA, 5 mM NaN<sub>3</sub>, 20% glycerol, and 10 mM MgCl<sub>2</sub>. Aliquots of the suspension (100 µl containing 300-500 µg of protein) were incubated with 125I-EGF (2.6 nM; 800,000 Ci/mmol; NEN, DuPont, Wilmington, DE) in the presence or absence of unlabeled EGF (1 µg) for 12-16 h at room temperature in a final volume of 400 µl. Binding was blocked by the addition of 3 ml of ice-cold 25 mM Tris, 20% glycerol, 5 mM NaN<sub>3</sub>, and 0.1% BSA. After cen-

trifugation at 2000 rpm for 20 min at 0°C, the supernatant was carefully aspirated, and pellets were counted in a gamma counter. Results were expressed as fmol/mg protein. EGFR status was defined using the arbitrary cutoff value corresponding to the median value of EGFR levels, (Battaglia et al., 1988).

Venous blood samples were obtained prior to and two months after surgical resection and allowed to clot then serum was separated by centrifugation at 3000 rpm for 10 min. Serum was removed and stored at -70°C until ELISA assayed for estimation of serum SCCA using monoclonal antibody (Fujirebio Diagnostics, Inc, Majnabbeterminalen, Göteborg, Sweden), (Röijer et al., 2003).

**Statistical analysis :**

Obtained data were presented as mean±SD, ranges, numbers and ratios. Results were analyzed using Wilcoxon (Z-test) test. Statistical analysis was conducted using the SPSS (Version 10, 2002) for Windows statistical package. P value <0.05 was considered statistically significant.

**Results**

The study included 13 patients; 10 males and 3 females, with mean age of 62.4±6.2, range: 54-73 years. Nasal obstruction was the main presenting symptom that was reported in all patients, epistaxis was reported in 9 patients and headache was a complaint of 7 patients. One of patients with SCC changes in an IP presented by unilateral facial swelling. Patients with recurrent IP gave history of previous endoscopic removal since a mean duration of 6.2±2.2; range: 3-9 months and one patient had recurrent IP twice. The three patients had papillomas associated with SCC; 2 cases gave history of multiple excisions for IP in the past, one had excised IP previously twice the last since 6 months and the other one since 4 months. Both were enrolled in the study presented by a left nasal mass extending into the ipsilateral maxillary sinus in one, while the second had a right nasal mass but sinuses were still free. The third patient denied a previous excision and presented by a left nasal mass with partial involvement of the ipsilateral maxillary sinus, (Table 1).

Histopathological examination of excised specimens documented the diagnosis of benign IP in 10 cases appeared macroscopically in the form of multiple polypoidal, firm mass with undulant or papillary surfaces, (Fig. 1). Microscopically, benign IP were characterized by focally sloughed stratified squamous epithelial covering with a mildly exophytic surface, (Fig. 3a) and multiple invaginations into the underlying focally edematous, vascular and focally fibrotic stroma that showed moderate to marked non-specific inflammatory cellular infiltration, (Fig. 3b). Microscopic examination of 3 IP revealed an evidence of nasal tissue involvement by an ulcerating, infiltrating neoplastic squamous epithelial growth, generally disposed in nests with central keratin pearls surrounded by desmoplastic stroma showing chronic non-specific inflammatory cellular infiltration. Focal high-grade dysplastic changes up to focal in-situ changes and few areas showing moderate anaplasia were also seen, (Fig. 4).

Mean EGFR levels estimated in tissue extract of IP with SCC was

65.77±11.26; range: 56.8-78.4 fM/mg protein and was significantly ( $P<0.05$ ) higher compared to its tissue levels estimated in both primary and recurrent IP. Moreover, mean EGFR levels estimated in tissue extract of recurrent IP was 41.08±5.9; range: 36.1-49.4 fM/mg protein and was significantly ( $P<0.05$ ) higher compared to its tissue levels estimated in primary; 26.71±8.1; range: 9.5-43.6 fM/mg protein, (Fig. 5).

Estimated preoperative serum SCCA levels were significantly higher in patients had IP with cancerous changes compared to levels in controls and patients with benign IP whether primary or recurrent, and in sera of patients had recurrent IP compared to levels estimated in controls and patients had primary IP; with significantly higher levels in those had primary IP compared to controls, (Fig. 6). Operative interference significantly reduced serum levels of SCCA in all patients with significantly lower postoperative serum levels compared to preoperative levels in all patients' groups. Moreover, postoperative (PO) serum SCCA levels in patients with be-

nign IP nearly returned to control levels with non-significant difference versus control levels and between patients with primary or recurrent IP. On the other hand postoperative serum SCCA levels were still significantly higher compared to control levels and non-significantly higher compared to levels estimated in patients with benign IP, (Table 2, Fig. 7).

**Table (1):** Patients' characters.

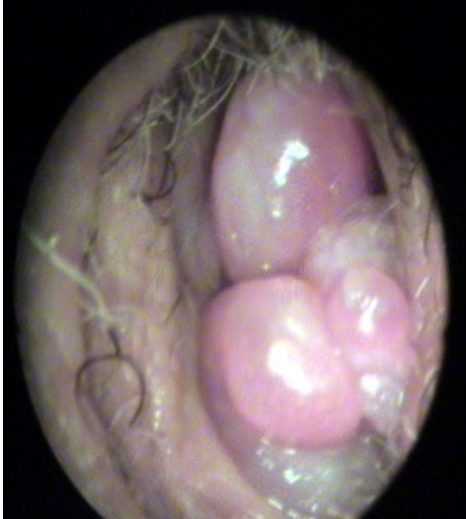
		Primary benign IP	Recurrent IP	IP with SCC	Total	
Number		6	4	3	13	
Age (years)		61.3±6.4	60.3±5.1	67.3±6	62.4±6.2	
Gender; M:F		4:2	4:0	2:1	16:9	
Presenting symptoms	Obstruction	6	4	3	13	
	Epistaxis	4	3	2	9	
	Headache	4	1	2	7	
Recurrence data	Duration	0	6.2±2.2	0	4 & 6 months	
	times	Once	0	3	0	3
		Twice	0	1	2	3

**Table (2):** Mean serum SCCA estimated in studied patients categorized according to clinical and histopathological data.

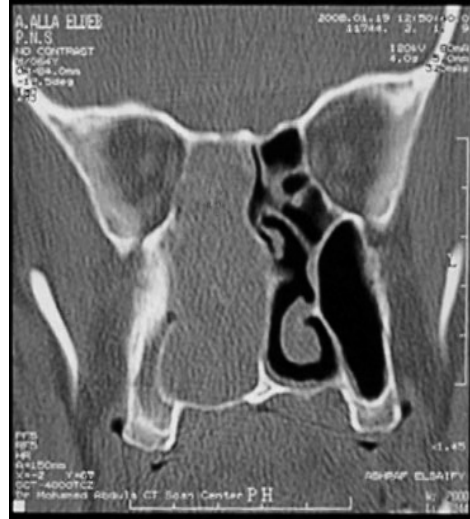		Control	Primary IP	Recurrent IP	IP with SCC	
Preoperative level	Mean±SD	2.31±0.33	5.87±1.7	9.6±1	20.48±4.6	
	Z		2.803	2.524	2.023	
	p <sub>1</sub>		=0.005	0.012	0.043	
	Z			2.032	2.524	
	p <sub>2</sub>			0.042	0.012	
	Z				2.023	
	p <sub>3</sub>				0.043	
Postoperative level	Mean±SD		2.41±0.4	2.8±0.4	3.62±0.9	
	Z		0.562	1.951	2.023	
	p <sub>1</sub>		>0.05	>0.05	0.043	
	Z			1.632	1.753	
	p <sub>2</sub>			>0.05	>0.05	
	Z				1.236	
	p <sub>3</sub>				>0.05	
	Z			3.297	2.524	2.023
	p <sub>4</sub>			0.001	0.012	0.043

p<sub>1</sub>: significance versus control levels      p<sub>2</sub>: significance versus levels estimated in primary IP  
 p<sub>3</sub>: significance versus levels estimated in recurrent IP      p<sub>4</sub>: significance versus postoperative levels

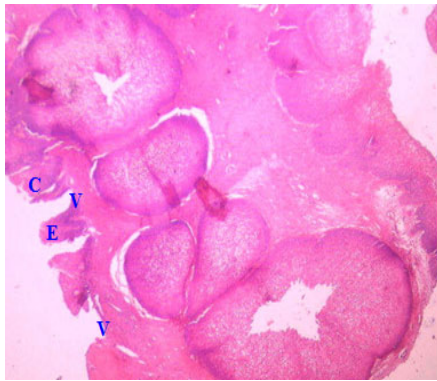




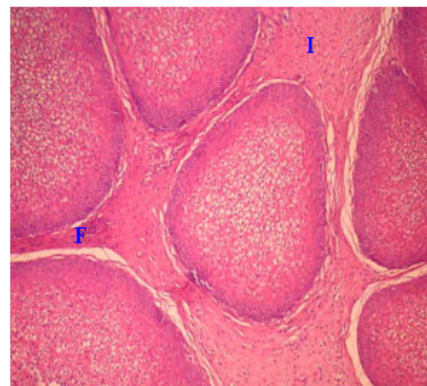**Fig. (1):** A photograph of IP appeared macroscopically in the form of multiple polypoidal mass with undulant surfaces.



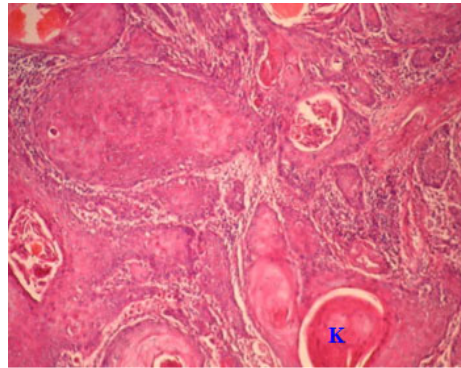
**Fig. (2):** CT imaging of a case of IP, coronal view, showing a right side large soft tissue mass occupying the middle meatus of the nasal cavity with involvement of both the maxillary antrum and the ethmoidal sinuses .



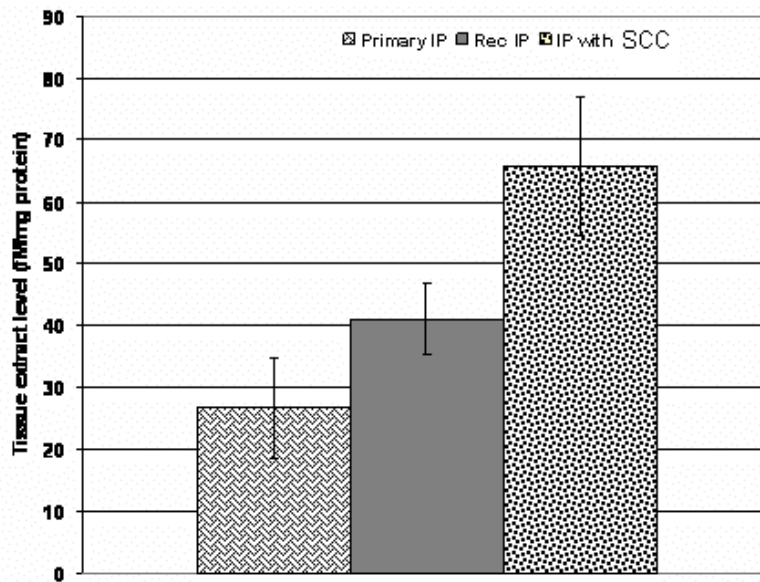
**Fig. (3a):** A photograph of endoscopically excised IP showing focally sloughed squamous epithelial (C) covering with multiple invaginations (V) and mildly exophytic surface (E), (H & E x100).



**Fig. (3b):** A photograph of endoscopically excised IP showing focally fibrotic stroma (F) and moderate to marked inflammatory cellular infiltrations (I), (H & E x200).



**Fig. (4):** A photograph of endoscopically excised IP showed an ulcerating, infiltrating neoplastic squameous epithelial growth of nasal tissue, generally disposed in nests with central keratin (K) pearls surrounded by desmoplastic stroma. Focal high-grade dysplastic changes and few areas showing moderate anaplasia were also seen,(H&E x160).



**Fig. (5):** Mean ( $\pm$ SD) IP tissue extract levels of EGFR estimated in studied cases

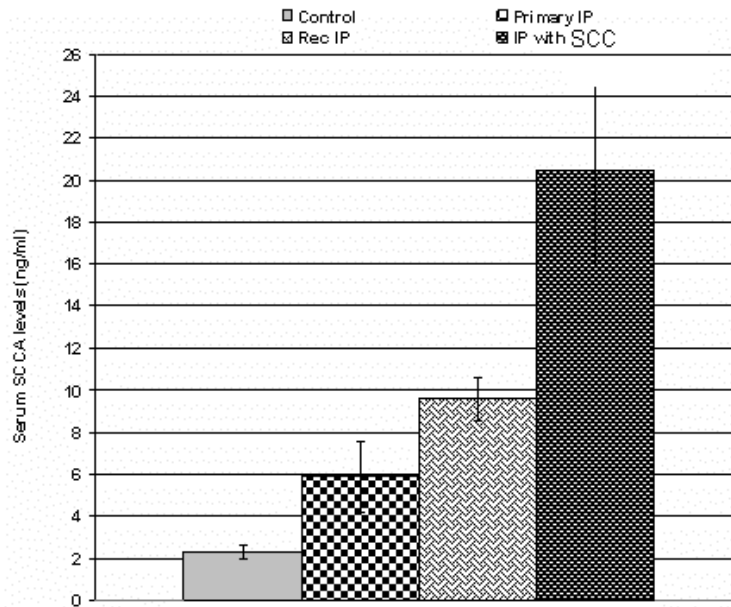


Fig. (6): Mean ( $\pm$ SD) of preoperative serum SCCA levels estimated in study groups

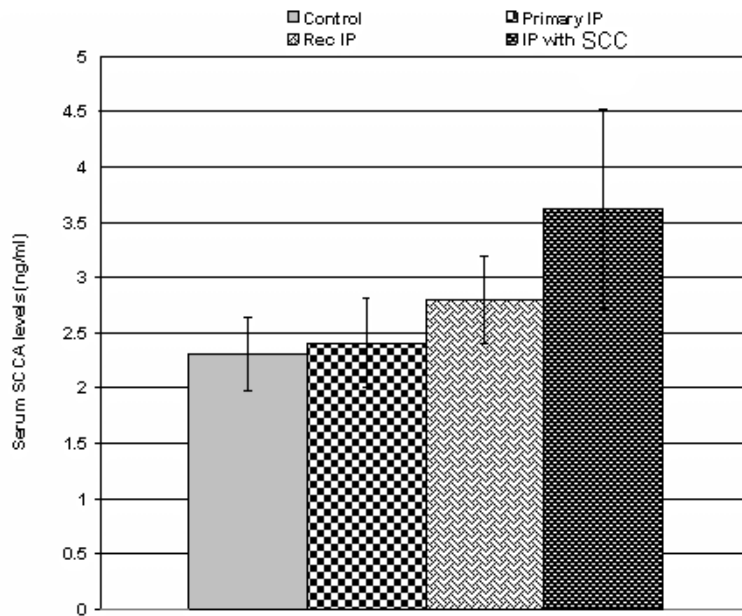


Fig. (7): Mean ( $\pm$ SD) of postoperative serum SCCA levels estimated in study groups

### **Discussion**

Inverted papillomas are primarily benign neoplasms that occur in the nasal cavity and paranasal sinuses. Many aspects of sinonasal IP are still controversial and active fields of research. Inverted papillomas generate considerable interest because they are locally aggressive, have a propensity to recur and are associated with malignancy (Ridder et al., 2008).

Throughout the current study which included, 13 patients with IP of which, three showed clinically suspicious but histopathologically proved cancerous changes. Such figure goes in hand with Tanvetyanon et al., (2009) who retrospectively reviewed the medical records of patients with IP and SCC treated at their institution and identified 6 patients with SCC arising from IP.

Mean EGFR levels estimated in tissue extract of IP with SCC were significantly higher compared to its tissue levels estimated in both primary and recurrent IP with significantly higher levels in recurrent IP compared to primary IP.

These data illustrated the impact of disease progression on tissue expression of EGFR and subsequent shedding it out of cellular compartment. These findings go in hand with Katori et al., (2005) who immunohistochemically measured EGFR and TGF- $\alpha$  tissue expression in exophytic papilloma, IP with dysplasia, IP with carcinoma and invasive SCC and found significant increase of EGFR and TGF- $\alpha$  in IP with severe dysplasia, IP with carcinoma and invasive SCC compared to IP with mild dysplasia and control nasal mucosa and concluded that precancerous lesions of IP exhibited elevated levels of EGFR and TGF- $\alpha$  and these expression may be associated with early events in IP carcinogenesis. Also, Sauter et al., (2007), reported that an increased EGFR and TGF-alpha expression is associated with early events in IP carcinogenesis.

The reported significant difference in tissue expression levels between primary IP and both recurrent and dysplastic IP spots light on a role of stimulated growth factors expression for the pathogenesis of both recurrence

and malignant transformation and thus could predict the oncoming prognosis of IP patients. These data go in hand with Chao & Fang, (2008), who found the positive rate of immunostaining, positive intensity of immunostaining for EGFR protein and EGFR mRNA were significantly up-regulated in the IP, synchronous carcinoma with IP and metachronous carcinoma with IP when comparing polyp and normal mucosa and concluded that a role for EGFR in the malignant transformation from IP to SCC of the nasal cavity is suggested.

These results coincided with that reported for other head and neck SCC (SCCHN); Katori et al., (2007), reported an association of patients' prognosis with EGFR staining and Ki-67 index; a significant increase was observed in patients who died or had residual disease compared with patients who were alive without disease and in the immunohistochemical analysis of EGFR and TGF- $\alpha$  and Ki67 index, a significant increase was observed in carcinoma ex-pleomorphic adenoma, especially

with adenocarcinoma, compared with pleomorphic adenoma and sialadenitis. Seethala et al., (2008), found in primary tumors, gastrin-releasing peptide receptor (GRPR) expression correlated with TGF- $\alpha$  and EGFR expression and the expression of EGFR and GRPR in the primary tumors correlated with TGF- $\alpha$  expression in paired nodal metastases and concluded that these findings support an autocrine signaling pathway involving TGF- $\alpha$  and EGFR in metastatic SCCHN as well as transactivation of EGFR by GRPR via TGF- $\alpha$ .

In parallel to tissue expression levels of EGFR, preoperative serum SCCA levels were significantly higher in patients had IP with cancerous changes compared to levels estimated in controls and patients with benign IP whether primary or recurrent, and in sera of patients had recurrent IP compared to levels estimated in controls and patients had primary IP with significantly higher levels in those had primary IP compared to controls. These data indicated that the source of SCCA estimated in serum was the papillomatous

growth and the more the change the more the serum level. In support of this assumption, operative interference significantly reduced serum levels of SCCA in all patients with significantly lower serum PO levels compared to preoperative levels in all patients' groups. Moreover, PO serum SCCA levels in patients with benign IP nearly returned to control levels with non-significant difference versus control levels and between patients with primary or recurrent IP.

Similarly, various studies concerned with SCC elsewhere in the body previously determined estimation of serum SCCA as a prognostic marker; Huang et al., (2006), indicated that SCCA may be of great potential as the biomarker of tongue cancer and as the potential therapeutic target for gene therapy. Iwata et al., (2007), report a case of inverted Schneiderian papilloma causing exceedingly high serum levels of carcinoembryonic antigen (CEA) and SCCA, postoperatively, the patient's symptoms resolved quickly, and the serum levels of CEA and SCCA decreased significantly

within 3 months. Zhu et al., (2008), found SCCA has prognostic significance for disease-free survival in patients with penile cancer treated with surgery. Also, Xiong et al., (2009) and van de Lande et al., (2009), found high serum SCCA levels can predict lymph nodal metastases in cancer cervix patients more accurately and are associated with a poor prognosis; the marker seems to identify a subgroup of LN negative patients with occult disease that may benefit from full lymphadenectomy.

It could be concluded that EGFR tissue expression level could be used for differentiation between benign and malignant IP even in early phases of dysplasia and serum SCCA could be used as a marker for complete operative excision of IP irrespective of its pathological diagnosis. However, further studies with larger series are needed to support these results and to clarify rationales.

### References

**Avissar N. E., Wang H. T., Miller J. H., Iannoli P. and Sax H. C. (2000)** : Epidermal growth factor receptor is increased in rab-

bit intestinal brush border membrane after small bowel resection. *Dig Dis Sci.*; 45(6):1145-52.

**Battaglia F., Polizzi G., Scambia G., Rossi S., Benedetti Panici P., Iacobelli S., Crucitti F. and Mancuso S. (1988)** : Receptors for epidermal growth factor and steroid hormones in human breast cancer. *Oncology*, 45 : 424-7.

**Chao J. C. and Fang S. Y. (2008)** : Expression of epidermal growth factor receptor in the inverted papilloma and squamous cell carcinoma of nasal cavity. *Eur Arch Otorhinolaryngol.*; 265 (8):917-22.

**Huang X., Wei Y., Li L., Wen Y., Yang J., Liu B., Song X. and Zhao J. (2006)** : Serum proteomics study of the squamous cell carcinoma antigen 1 in tongue cancer. *Oral Oncol.*; 42(1):26-31.

**Iwata T., Inoue K., Nishiyama N., Izumi N., Mizuguchi S., Morita R., Tsukioka T., Suehiro S., Obatake N. and Wakasa K. (2007)** : Pulmonary inverted Schneiderian papilloma causing

high serum levels of carcinoembryonic antigen and squamous cell carcinoma-associated antigen: report of a case. *Surg Today.*; 37 (9):790-3.

**Kato H. and Torigoe T. (1977)** : Radioimmunoassay for tumor antigen of human cervical squamous cell carcinoma. *Cancer*; 40: 1621-8.

**Katori H., Nozawa A. and Tsukuda M. (2005)** : Markers of malignant transformation of sinonasal inverted papilloma. *Eur J Surg Oncol.*; 31(8):905-11.

**Katori H., Nozawa A. and Tsukuda M. (2007)** : Cell proliferation, apoptosis, and apoptosis inhibition in malignant transformation of sinonasal inverted papilloma. *Acta Otolaryngol.*; 127 (5):540-6.

**Kraft M., Simmen D., Casas R. and Pfaltz M. (2001)** : Significance of human papillomavirus in sinonasal papillomas. *J Laryngol Otol.*; 115(9):709-14.

**Liu C. Y., Tsai T. L., Hsu C. Y. and Lin C. Z. (2004)** : Oncocytic

Schneiderian papilloma. *J Chin Med Assoc.* 2004; 67(5):255-7.

**Lund V J. and Lloyd G A. (1984)** : Radiological changes associated with inverted papilloma of the nose and paranasal sinuses. *Br J Radiol*; 57, 455-461.

**Mirza S., Bradley P.J., Acharya A., Stacey M. and Jones N. S. (2007)** : Sinonasal inverted papillomas: recurrence, and synchronous and metachronous malignancy. *J Laryngol Otol.*; 121 (9): 857-64.

**Ojiri H., Ujita M., Tada S. and Fukuda K. (2000)** : Potentially distinctive features of sinonasal inverted papilloma on MR imaging. *AJR Am J Roentgenol.*; 175 (2):465-8.

**Penault-Llorca F., Durando X. and Bay J. O. (2003)** : Prognostic value of epidermal growth factor receptor. *Bull Cancer*; 90 Spec No: S192-6.

**Perez-Torres M., Valle B.L., Maihle N. J., Negron-Vega L., Nieves-Alicea R. and Cora E. M. (2008)** : Shedding of epidermal

growth factor receptor is a regulated process that occurs with over-expression in malignant cells. *Exp Cell Res.*; 314(16):2907-18.

**Psyrrri A., Yu Z., Weinberger P. M., Sasaki C., Haffty B., Camp R., Rimm D. and Burtness B. A. (2005)** : Quantitative determination of nuclear and cytoplasmic epidermal growth factor receptor expression in oropharyngeal squamous cell cancer by using automated quantitative analysis. *Clin Cancer Res.*;11(16):5856-62.

**Ridder G. J., Behringer S., Kayser G., Pfeiffer J. (2008)** : Malignancies arising in sinonasal inverted papillomas. *Laryngorhinotologie.*; 87(11):783-90.

**Röijer E., Nilsson K., Oskarsson M., Dahlén U., Andersson I. and Nilsson O. (2003)** : Development of Monoclonal Antibodies and Immunoassays against different forms of Squamous Cell Carcinoma Antigens (SCCA). *Tumor Biol* 24, p. 83.

**Sauter A., Matharu R., Hörmann K. and Naim R. (2007):**



Current advances in the basic research and clinical management of sinonasal inverted papilloma (review). *Oncol Rep.*; 17(3):495-504.

**Schneider S. S., Schick C., Fish K. E., Miller E., Pena J. C., Treter S. D., Hui S. M. and Silverman G. A. (1995) :** A serine protease inhibitor locus at 18q21.3 contains a tandem duplication of the human squamous cell carcinoma antigen gene. *Proc Natl Acad Sci USA*, 92, 3147-51.

**Seethala R. R., Gooding W. E., Handler P. N., Collins B., Zhang Q., Siegfried J. M. and Grandis J. R. (2008) :** Immunohistochemical analysis of phosphotyrosine signal transducer and activator of transcription 3 and epidermal growth factor receptor autocrine signaling pathways in head and neck cancers and metastatic lymph nodes. *Clin Cancer Res.*; 14(5):1303-9.

**Shanmugaratnam K. and Sobin L. H. (1991) :** Histological Typing of Tumors of the Upper Respiratory Tract and Ear. 2nd

ed. Berlin, Germany: Springer; 1991:20-21.

**Suminami Y., Kishi F., Sekiguchi K. and Kato H. (1991) :** Squamous cell carcinoma antigen is a new member of the serine protease inhibitors. *Biochem Biophys Res Commun* 181, 51-58.

**Syrjänen K. (2000a) :** HPV infections in the respiratory tract. In: Syrjänen K, Syrjänen S, eds. *Papillomavirus infections in human pathology*. New York: Wiley & Sons:355-78.

**Syrjänen K. J., Chang F. and Syrjänen S. M. (2000b) :** HPV infections in etiology of benign and malignant sinonasal, bronchial and oesophageal squamous cell lesions. In: Monsonego J, ed. *4th International Multidisciplinary Congress EUROGIN 2000*, Paris 5-9, April, 2000. Bologna: Monduzzi Editore: 169-79.

**Tanvetyanon T., Qin D., Padhaya T., Kapoor R., McCaffrey J. and Trotti A. (2009) :** Survival outcomes of squamous cell carcinoma arising from sinonasal inverted papilloma: report of 6 cases

with systematic review and pooled analysis. *Am J Otolaryngol.*; 30 (1):38-43.

**van de Lande J., Davelaar E. M., von Mensdorff-Pouilly S., Water T. J., Berkhof J., van Baal W. M., Kenemans P. and Verheijen R. H. (2009) :** SCC-Ag, lymph node metastases and sentinel node procedure in

early stage squamous cell cervical cancer. *Gynecol Oncol.*; 112 (1): 119-25.

**Xiong Y., Peng X. P., Liang L. Z., Zheng M. and Li J. D. (2009):** Clinical significance of combined examination of pretreatment serum CYFRA21-1 and SCCAg in cervical cancer patients. *Chin J Cancer*; 28(1):64-7.

REPRINT

# BENHA MEDICAL JOURNAL

**THE APPLICABILITY OF BIOMARKERS  
FOR DIFFERENTIATION OF INVERTED  
PAPILLOMA WITH DIFFERENT  
PATHOLOGICAL DIAGNOSES**

**Ahmed S. El-Kady MD, Kassem M. Kassem MD,  
Abou-Bakr E. Ras, MD, Adel F. Al-Kholy MD  
and Abdel Latif El-Balshy MD**

**Published by  
Benha Faculty of Medicine**

*Volume 26 Number 3  
Sept. 2009*

## **PERIAMPULLARY TUMORS IN THE FIRST THREE DECADES OF LIFE**

**Talaat Abdallah MD**

*Departments of General Surgery,  
Faculty of Medicine, Mansoura University, Egypt*

### **Abstract**

**Introduction :** *Pancreaticoduodenectomy is established to be the potential cure for patients with periampullary carcinoma. Because a variety of physiological functions decline with aging, one should suspect a better outcome for young patients with this disease. This study aimed to present the experience of Mansoura gastroenterology surgery center in the management of periampullary carcinoma in patients  $\leq 30$  years old .*

**Patients and Methods :** *Between January 1998 and December 2007 and out of 748 cases, 18 (2.4 %) were  $\leq 30$  years old , the mean age was  $25 \pm 5.7$  years . Pancreatic head mass was found in 15 patients (83.3%) and ampullary lesion in 3 (16.7%). Pancreatoduodenectomy was done for 12 patients ( 66.7%) , Hepatico- jejunostomy for 4 patients (22.2%) and external biliary deainage for 2 patients (11.1%). The follow up period was  $40.9 \pm 35$  months.*

**Results :** *The tumor resectability rate was 66.7 % . The hospital stay was  $8.6 \pm 2$  days after pancreaticoduodenectomy and  $4.2 \pm 0.5$  days after hepaticojejunostomy . The hospital mortality after pancreaticoduodenectomy was 8.3 % ( one patient) due to hepatorenal failure . Morbidity after pancreaticoduodenectomy occurred in 2 patients (pancreatic leak in one and bleeding gastrojejunostomy in the other). The mean survival in the pancreaticoduodenectomy group was 42.4 months (8 months - 9 years). Eight cases are still living and disease free. In the other group, the mean survival was 35.6 months. The tumor recurrence rate after resection was 16.7%.*

**Conclusion :** *The tumor resectability , recurrence and survival in patients with periampullary malignancy  $\leq 30$  years old seem better than those in the older ages. Because the number of cases was limited, multicentric studies are essential to prove these results.*

### **Introduction**

It is well established that pancreaticoduodenectomy (PD) is the potential cure for patients with periampullary malignancies (Yeo et al 2002 , Cameron et al 2006). However, 10-20% of patients with pancreatic cancer are candidates for curative surgery at the time of diagnosis (Kelly and Benjamin 1995) and the number of long term survivors is limited because these tumors frequently recur even after curative surgery (Lindell et al 2000, Hishinuma et al 2006). Because a variety of physiological functions decline with aging, one should suspect a better outcome for young patients with periampullary tumors. This is a retrospective study involving young patients  $\leq 30$  years with periampullary tumors concerning their clinicopathological characteristics and the outcome after surgery.

### **Patients and Methods**

Between January 1998 and December 2007, 748 consecutive patients with periampullary tumors were subjected to surgery at Gastroenterology surgery center, Mansoura university. A total of 18 pa-

tients (2.4%) aged  $\leq 30$  years were retrospectively reviewed. The mean age was  $25 \pm 5.7$  years. Ten patients were females and female: male ratio was 1: 0.8. The main presenting symptom was jaundice (12 patients, 66.7%) followed by epigastric pain (6 patients, 33.3%). The mean preoperative serum total bilirubin was 9.4 mg% (0.5 - 36 mg%). Pancreatic head mass was found in 15 patients (83.3%) and ampullary tumor in 3 (16.7%). The patients were staged according to American joint committee on cancer (AJCC), 2002 (Greene et al 2002). The tumor was considered locally advanced and irresectable in the presence of encasement of the celiac trunk and/or superior mesenteric artery and invasion of the portal vein (Patients characteristics are shown in table 1). If histopathology was absent, the diagnosis was made on the basis of clinical evaluation and available radiology (computed tomography {Fig 1} and endoscopic retrograde cholangiopancreatography ERCP). Pancreaticoduodenectomy was performed in 12 patients (66.7%) with pancreatico-gastrostomy in 10 patients and pancreaticojeju-

stomy in 2 patients. Biliary bypass in the form of hepaticojejunostomy (HJ) was done in 4 patients (22.2%). Only external biliary drainage was done for 2 patients (11.1%) due to the presence of bilobar liver metastases. The mean follow up period was 40.9 months (6months - 9 years).

The results are reported as the mean  $\pm$  SD. The actuarial survival rates were calculated according to the Kaplan Meier method. Survival differences were assessed using the Log-rank test. P less than 0.05 was considered statistically significant. A two - group comparison was performed between the resection and non resection patients concerning their survival by the Mann - Whitney U test.

### **Results**

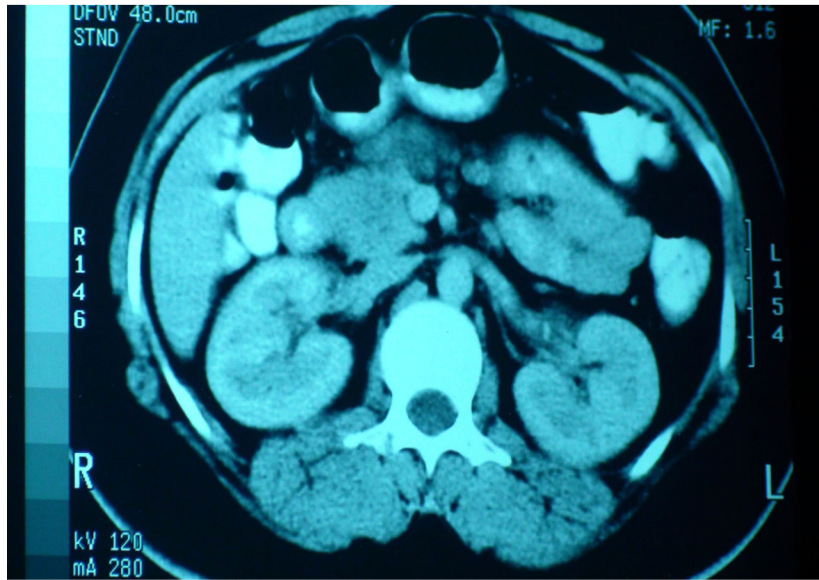
The resectability rate was 66.7% (12 patients, 3 with ampullary tumors and 9 with pancreatic head tumors). The mean hospital

stay was  $8.6 \pm 2$ days (6-14 days) in resection group and  $4.2 \pm 0.5$  days after HJ. The hospital mortality was 8.3% in the resection group (one patient) due to hepatorenal failure. Bleeding gastrojejunostomy occurred in one patient (8.3%) after PD, it was managed by refashioning of the anastomosis. The patient unfortunately developed hepatorenal failure and died 10 days after surgery. Pancreatic leakage and fistula occurred in one patient after PD (8.3%) and it was managed conservatively.

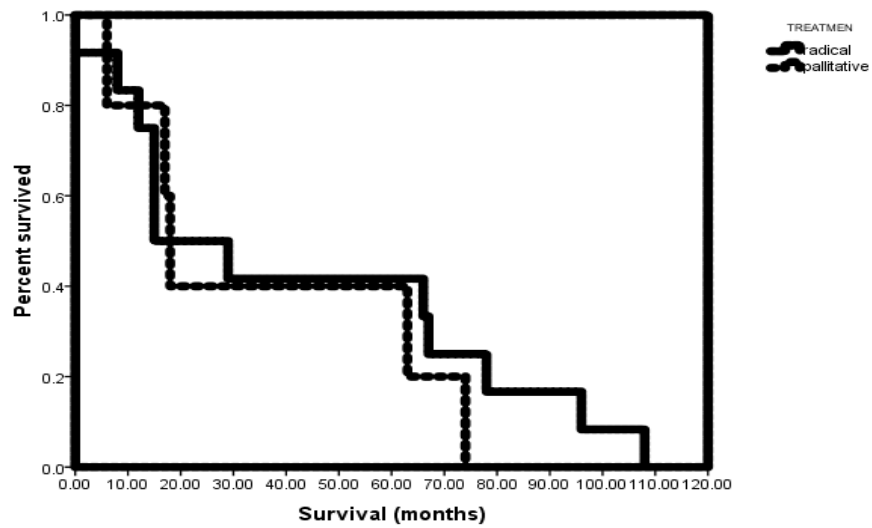
Tumor recurrence occurred in 2 patients after PD (16.7%), one patient had liver metastases 29 months after resection and the other developed local recurrence 4 years after resection. The mean survival in the PD group was 42.4 months (8 months - 9 years). Eight cases are still living and disease free. In the other group, the mean survival was 35.6 months (P 0.4) {Fig 2}.

**Table 1 :** Patient characteristics.

<b>Characteristic</b>	<b>No of patients</b>	<b>%</b>
<b>Age:</b>		
11-80 (yrs)	748	(100)
≤ 30 (yrs)	18	(2.4)
<b>Genders:</b>		
Male	8	(44.4)
Female	10	(55.6)
<b>Jaundice</b>	12	(66.7)
<b>Epigastric pain</b>	6	(33.3)
<b>Tumor location:</b>		
Pancreatic head	15	(83.3)
Ampullary	3	(16.7)
<b>TNM staging (AJCC):</b>		
I	9	(60)
IV A	4	(26.7)
IV B	2	(13.3)
<b>Histopathology: of resected tumors (12 patients)</b>		
Pancreatic adenocarcinoma	7	(58.3)
Ampullary carcinoma	3	(25)
Pancreatic carcinoid	1	(8.3)
Distal cholangiocarcinoma	1	(8.3)



**Fig. 1 :** CT scan : Pancreatic head mass.



**Fig. 2 :** Kaplan-Meier survival curve after PD and HJ for perampullary carcinoma.



### Discussion

This study focus on cases with periampullary malignancies in the first 3 decades of life. It included 18 patients managed at Mansoura Gastroenterology surgery center between January 1998 and December 2007. Fortunately, the incidence of the disease among this age group was 2.4% only (18 out of 748 patients). The mean age was  $25 \pm 5.7$  years. Other series studied the disease among the general population and the mean age was 62.4 years (Nakano et al 2008), 58 years (Fathy et al 2008) and 64.8 years (Takao et al 2008).

In the present study, the male to female ratio was 0.8 :1. Fathy et al (2008) reported male to female ratio of approximately 2:1 and Singhal et al (2008) reported a ratio of 3.6 :1.

The analysis was undertaken to analyse patients' morbidity and survival according to different lines of treatment which may be helpful to find optimal treatment modalities for individual patients. During 1960s, it was suggested that PD be abandoned for the management of periampullary ma-

lignancies because of high morbidity and mortality and the lack of long term survivors. Recently, PD and its modifications have clearly evolved to become safe and effective procedure (Cullen et al 1994). Although resection is the only potentially curative treatment modality for this disease, the overall resectability rate is approximately 20% (Connolly et al 1987). However 66.7% of patients in the present study were resectable.

In recent decades, several institutions have reported a significant drop in hospital morbidity and mortality after resection for periampullary carcinoma (Akhtar et al 2000). Pancreatic fistula is one of the most serious postoperative complications. The mean incidence of pancreatic fistula was reported to be 16% (Nakano et al 2008), 12% (Singhal et al 2008), 10.6% (Fathy et al 2008). In the present study the incidence of pancreatic fistula was 8.3% .

The hospital mortality rate after PD has been recorded in different series to reach 8% (Takao et al 2008), 6% (Cameron et al 2006), 5.6% (Singhal et al 2008) and

3.2% (Fathy et al 2008). In the present study, hospital mortality occurred in one patient (8.3%) due to hepatorenal failure.

The 5 year survival rate after resection has been reported to be around 10 % (Conlon et al 1996) and approaching 20% (Cameron et al 1991). Shimizu et al (2008) have reported a 5 year survival rate of 61% for ampullary carcinoma and 45% for distal cholangiocarcinoma. Connolly et al (1987) reported a median survival time of 20 months after resection of periampullary carcinoma. Fathy et al (2008) reported 34.9 months for ampullary carcinomas. and 19 months for periampullary carcinomas in general. In the present study, the mean survival time was 42.4 months after PD and 35.6 months in the non resection group.

Tumor recurrence whether local or by distant metastasis is common after PD. It approached 50% after 5 years in some series (Lee et al 2006, Shimizu et al 2008). They mentioned that the higher risk factors of recurrence include lymph node secondaries

or perineural invasion and should be considered for adjuvant treatment with postoperative chemotherapy and / or radiotherapy although the data supporting this option are limited. In the present study, tumor recurrence rate was 16.7% as 2 patients had recurrence in the form of local recurrence after 4 years in one and liver metastases after 29 months in the other

### **Conclusion**

This study provided important information for the management of periampullary malignancies in young patients with ages  $\leq$  30 years. However, the study has the limitation of small sample size and large samples are required before drawing an exact conclusion

### **References**

**Akhtar K., Perricone V., Chang D. and Watson R. J. (2000)** : Experienc of pancreaticoduodenectomy in a district general hospital. Br J Surg; 87:362/373.

**Cameron J. L., Crist D. W., Sitzmann J. V., Hruban R., Boitnott J. K., Seidler A. J. and**

- Coleman J. (1991)** : Factors influencing survival after pancreaticoduodenectomy for pancreatic cancer. *Am J Surg*; 161:120-125.
- Cameron J. L., Riall T. S., Coleman J. and Belcher K. A. (2006)** : One thousand consecutive pancreaticoduodenectomies. *Ann Surg*; 244 (1): 10-15.
- Cohen J. R., Kuchta. N., Geller N., Shires G. T. and Dineen P. (1982)** : Pancreaticoduodenectomy A 40-year experience. *Ann Surg* :195:608-617.
- Conlon K. C., Klimstra D. S. and Brennan M. F. (1996)** : Long-term survival after curative resection for pancreatic ductal adenocarcinoma. Clinicopathologic analysis of 5-year survivors. *Ann Surg*; 223: 273-279.
- Connolly M. M., Dawson P. J., Michelassi F., Moossa A. R. and Lowenstein F. (1987)** : Survival of 1001 patients with carcinoma of the pancreas. *Ann Surg* : 20(55) 366-373.
- Cullen J. J., Sarr M. G. and Ilstrup D. M. (1994)** : Pancreatic anastomotic leak after pancreaticoduodenectomy : incidence, significance and management. *Am J Surg*; 168 : 295 - 298.
- Fathy O., Abdelwahab M., Elghawalby N., Sultan A., El-Ebidiy G., Abu.zeid M., Abdallah T., El-Shoubary M., Fouad A., Kandeel Th., Abo-Elenin A., Gad El-Hak N., Abd El-Raouf A., Sultan A. M. and Ezzat F. (2008)** : Surgical management of periampullary tumors : A retrospective study . *Hepto- Gastroenterology* : 55:1463-1469.
- Greene F. L., Page D. L. and Fleming I. D. (2002)** : *AJCC Cancer Staging Manual*. 6th Edition. New York, Berlin, Heidelberg; Springer-Verlag; PP121-124.
- Hishinuma S., Ogata Y., Tomikawa M., Ozawa I., Hirabayashi K. and Igarashi S. (2006)** : Patterns of recurrence after curative resection of pancreatic cancer, based on autopsy findings. *J Gastrointest Surg*; 10 (4): 511-518.
- Kelly D. M. and Benjamin I. S. (1995)** : Pancreatic carcinoma. *Ann Oncol*; 6: 19-28.

**Lee G. W., Kang J. H., Kim H. G., Lee J. S. and Jan J. S. (2006)** : Combination chemotherapy with gemcitabine and cisplatin as first line treatment for immunohistochemically proven cholangiocarcinoma. *Am J Clin Oncol*; 29: 127-131.

**Lindell G., Hansson L., Dawiskiba S., Andersson R., Axelson J. and Ihse I. (2000)** : Operations for extrahepatic bile duct cancers: are the results really improving? *Eur J Surg*; 166 (7): 535-539.

**Nakano H., Asakura T., Koizumi S., Asano T., Watanabe T., Otsubo T. and Takizawa K. (2008)** : Second surgery after a pancreaticoduodenectomy in patients with periampullary malignancies . *Hepto-Gastroenterology* ; 55 : 687-691.

**Neoptolemos J. P., Russell R. C., Bramhall S. and Theis B. (1997)** : Low mortality following resection for pancreatic and periampullary tumours in 1026 patients :UK survey of specialist pancreatic units. *UK Pancreatic Cancer Group Br - J Surg* : 84 : 1370-1376.

**Shimizu Y., Kimura F., Shimizu H., Yoshidome H., Ohtsuka M. and Miyazaki M. (2008)** : The morbidity, mortality and prognostic factors for ampullary carcinoma and distal cholangiocarcinoma. *Hepato-Gastroenterology*; 55 : 699-703.

**Singhal D., Goyal N., Gupta S., Soin A. and Nundy S. (2008)** : Isolated loop Pancreatic remnant drainage following pancreatico-duodenal resection. *Hepto-Gastroenterology*, 55 : 677-680.

**Takao S., Shinchi H., Maemura K., Kurahara H., Natsugoe S. and Aikou T. (2008)** : Survival benefit of pancreaticoduodenectomy in a Japanese fashion for a limited group of patients with pancreatic head cancer. *Hepto-Gastroenterology*; 55:1789-1795.

**Yeo G. J., Cameron J. L., Lillemoe K. D., Sohn T. A., Campbell K. A., Sauter P. K., Coleman J., Abram R. A. and Hruban R. H. (2002)** : pancreatico duodenectomy with or without distal gastrectomy and extended retroperitoneal lymphadenectomy for periampullary adenocarcino-

Talaat Abdallah

---

ma. Part 2: randomized controlled trial evaluating survival, morbidity and mortality. Ann surg : 236 (3): 355-366.

REPRINT

# **BENHA MEDICAL JOURNAL**

**PERIAMPULLARY TUMORS  
IN THE FIRST THREE  
DECADES OF LIFE**

**Talaat Abdallah MD**

**Published by  
Benha Faculty of Medicine**

*Volume 26 Number 3  
Sept. 2009*

## **SOME TOXIC EFFECTS OF BUTYLATED HYDROXYTOLUENE AND GALLIC ACID**

**Eman A. Al-Shehri Ph.D  
and Ammenah M. Al-Suhaibani Ph.D**

*Nutrition and Food Sciences Department,  
Princess Norah Bent Abdul-Rahman University , Riyadh*

### **Abstract**

*Some toxic effects of the synthetic antioxidant butylated hydroxytoluene and the natural plant phenol gallic acid were studied in rats by feeding the animals diets containing 0, 0.3 and 0.6% of each of the compounds investigated for three weeks. The toxicological parameters included body weight gain, hematology, some parameters of kidney function and histopathological examination of the kidney. Body weight gains in the Butylated hydroxytoluene treated animals were significantly lower than controls. The group fed 0.6% butylated hydroxytoluene showed reduction in hemoglobin concentration, hematocrit and red blood cell count. Butylated hydroxytoluene in either concentrations caused significant increases in platelet count. This may be an adaptive response to platelet dysfunction. In addition , serum total protein and serum albumin were decreased and some histopathological changes in the kidney were noticed in the same groups. the only toxic effect of gallic acid was a decreased white blood cell count in the 0.6% treated group. Accordingly gallic acid and galates are suggested to be better food additives than butylated hydroxytoluene. Based on the present results 0.3% gallic acid is determined to be a no-observed-adverse-effect level (NOAEL) in rats. This level is translated into 178mg/kg/day.*

### **Introduction**

Butylated hydroxytoluene (2, 6-di-tert-p-cresol; BHT) is one of the antioxidants used extensively

in the food industry. It is also widely used in combination with other antioxidants as butylated hydroxanisole, propyl galate and

citric acid for the stabilization of oils and high fat foods (Madhavi et al., 1996). It was shown that feeding experimental animals certain synthetic antioxidants at levels ranging from 0.1- 1% of the diet may affect a number of normal processes such as hepatic microsomal drug metabolism, tumor necrosis factor- induced cytotoxicity and platelet aggregation (Fritsche and Mc-Guire, 1997). Administration of butylated hydroxytoluene by gavages to rats at levels of 25,250 or 500 mg/kg/day for 21 days resulted in a dose dependant related hepatomegaly and at the highest dose a progressive portal hepatocyte necrosis (Madhavi et al, 1996). Renal toxicity has been reported in rats fed 1% butylated hydroxyteluene for 12- 48 days (Meyer et al., 1989).

Butylated hydroxytoluene was reported to cause extensive internal and external hemorrhages in rats due to a disruption of the blood coagulation mechanism, resulting in increased mortality. This was indicated to be due to inhibition of phyloquene epoxide reductase activity in the liver by BHT methide, one of the reactive

metabolites of BHT (Cotreli et al., 1994; Medhavi et al., 1996). This metabolite was also shown to promote lung tumors by covalent binding to critical proteins (Lemerrier et al., 2004).

Gallic acid (3, 4, 5- Trihydroxy benzoic acid; GA), a natural plant phenol with well known antioxidant properties, occurs in many medicinal plants and presents mostly in a conjugated form, such as found in hydrolyzable tannins, which are commonly referred to as tannic acid. Gallic acid and its catechin derivatives are also present as one of the phenolic compounds of both green and black tea (Ow and Stupans, 2003). It is extracted by hydrolysis of galotannins for use as an antioxidant in foodstuffs (Niho et al., 2001). Its derivatives such as propyl gallate, octyl gallate and lauryl gallate are used widely as food additives to reduce rancidity and as preservatives (Serrano et al., 1998). Gallic acid could be absorbed from foods by biodegradation of tannic acid and gallates in the gastrointestinal tract. Hydrolyzable tannins are present in almost every food plant (Chung



et al., 1998; Chen and Chung, 2000).

Tannins have been shown to be responsible for decreases in feed intake, growth rate, feed efficiency, net metabolizable energy and protein digestibility in experimental animals (Bravo, 1998; Chun et al., 1998). The antinutritional effect may be due to the precipitation of proteins in the alimentary tract by the formation of complexes and inhibition of digestive enzymes (Carmona, 1996), or it may be due to the decreased efficiency in converting the absorbed nutrients to new body substances (Chung et al., 1998). Orally administered gallic acid may exert such nutritional effects as observed in tannins (Niho et al., 2001). On the other hand gallic acid is known to potentiate several pharmacological and biochemical pathways having anti-inflammatory (Kroes et al., 1992), antimutagenic (Ow and Stupans, 2003) and anticancer activity (Parsed et al., 2006; Stapleton et al., 2006; Raina et al., 2008).

The present study was conducted to identify the toxic effects

of butylated hydroxytoluene which is a synthetic antioxidant and gallic acid which is a natural phenolic compound having an antioxidant activity.

### **Materials and Methods**

Forty adult male albino rats weighing 180-200 grams were housed individually in stainless steel cages in an environmentally controlled room, with temperature of  $22\pm 3^{\circ}\text{C}$ , 12h light/ dark cycle and a relative humidity of  $50\pm 5\%$ . Rats were randomly divided into five groups and were allocated to either control powdered diet or the same basic diet containing 0.3% or 0.6% of either BHT or GA.

Animals had free access to food and water. After 21 days of consuming the experimental diet followed by an over night fasting, rats were anesthetized with ether and blood samples were collected from inferior vena cava for hematology and blood biochemistry. Hematological examination was performed using an automatic hematology analyzer, M- 2000 (Toa Medical Electronics; Hyogo, Japan) and the following parame-

ters were determined: white blood cell count, red blood cell count, hemoglobin concentration, hematocrit, and platelet count. Reticulocyte count was performed using a Microx HEG- 120A (Omron Tateishi Electronics Co., Tokyo- Japan). Prothrombin activity was determined using the method described by Ware et al (1964), and fibrinogen was estimated according to Dacia and Lewis (1975). Parameters for blood biochemistry included total protein, albumin, blood urea, creatinine and uric acid and were determined using commercial kits (Roche products Ltd and Randox Laboratories Ltd). At autopsy, samples of the kidneys were fixed in neutral buffered formalin and tissues were processed for histopathological examination.

Values are presented as means  $\pm$  SD. Significance of the difference was tested by students t test. The probability of 0.05 was chosen as the significant level.

## Results

Animals that received BHT presented lower body weight gain compared to controls or GA fed groups (Table 1) among parameters in blood biochemistry, decreases of serum total protein and serum albumen were observed with BHT treatment (Table 2). The histopathological examination of the kidney showed some BHT-related effects which were more prominent in case of the 0.6% fed group (Fig. 1-3). Hematological data (Table 3), indicated that the 0.6% BHT fed group showed reduced hemoglobin, red blood cell count and hematocrit. In addition, BHT at both concentrations caused significant increases in platelet count compared with controls. A decrease in the white blood cell count was noted in the 0.6% GA fed group. No other parameters were shown to be affected by administration of GA. The prothrombin activity and fibrinogen were normal for all groups investigated (Table 4).

**Table 1** : Initial body weight, final body weight and body weight gain of control rats and rats fed diet containing BHT or GA (mean  $\pm$ SD).

parameters	Control	BHT (0.3%)	BHT (0.6%)	GA (0.3%)	GA (0.6%)
Initial body weight (g)	188.15 $\pm$ 5.81	190.85 $\pm$ 6.13	186.50 $\pm$ 4.64	193.26 $\pm$ 5.12	185.84 $\pm$ 6.45
Final body weight (g)	258.93 $\pm$ 10.62	240.16 $\pm$ 8.82*	227.63 $\pm$ 7.57*	262.24 $\pm$ 12.43	254.61 $\pm$ 11.36
Body weight gain (g)	69.35 $\pm$ 5.48	51.38* $\pm$ 4.42	41.95* $\pm$ 3.88	70.82 $\pm$ 6.24	86.65 $\pm$ 5.98

\* Significant difference compared with control group.

**Table (2)** : Concentration of serum total protein, serum albumin, blood urea, Serum creatinine and serum uric acid in control rats and rats fed diets containing BHT or GA (mean  $\pm$ SD).

parameters	Control	BHT (0.3%)	BHT (0.6%)	GA (0.3%)	GA (0.6%)
Total protein (g/dl)	7.55 $\pm$ 0.28	6.89 $\pm$ 0.19*	6.43 $\pm$ 0.19*	7.51 $\pm$ 0.35	7.39 $\pm$ 0.63
Albumin (g/dl)	4.36 $\pm$ 0.39	3.56 $\pm$ 0.28*	3.19 $\pm$ 0.31*	4.25 $\pm$ 0.62	4.17 $\pm$ 0.56
Urea (mg/dl)	29.81 $\pm$ 1.92	29.15 $\pm$ 2.51	27.58 $\pm$ 2.31	27.42 $\pm$ 1.87	29.15 $\pm$ 2.24
Creatinine (mg/dl)	0.37 $\pm$ 0.11	0.35 $\pm$ 0.06	0.34 $\pm$ 0.09	0.31 $\pm$ 0.10	0.32 $\pm$ 0.12
Uric acid (mg/dl)	2.35 $\pm$ 0.96	2.12 $\pm$ 0.85	2.42 $\pm$ 0.73	2.15 $\pm$ 0.54	2.09 $\pm$ 0.64

\* Significant difference compared with control group.

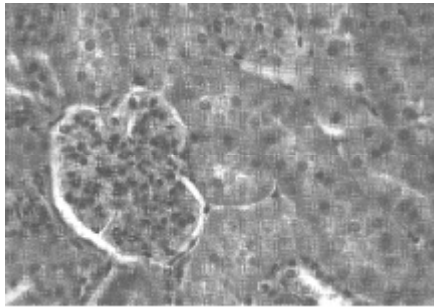
**Table (3) :** Hematology data for control rats and rats fed diet containing BHT or GA (mean  $\pm$ SD).

Parameters	Control	BHT (0.3%)	BHT (0.6%)	GA (0.3%)	GA (0.6%)
White blood cell count ( $10^9/L$ )	12.88 $\pm$ 2.11	12.34 + 1.45	12.65 $\pm$ 1.76	11.83 $\pm$ 2.31	10.12 $\pm$ 1.91*
Red blood cell( $10^{12}/l$ )	7.14 $\pm$ 0.18	7.11 $\pm$ 0.15	6.36 $\pm$ 0.14*	7.12 $\pm$ 0.12	7.21 $\pm$ 0.18
Hemoglobin (g/dl)	14.15 $\pm$ 0.28	14.24 $\pm$ 0.31	13.11 $\pm$ 0.21*	14.52 $\pm$ 0.42	14.51 $\pm$ 0.36
Hematocrit (%)	35.21 $\pm$ 1.42	34.85 $\pm$ 1.63	31.17 $\pm$ 1.12*	35.16 $\pm$ 1.56	36.18 $\pm$ 1.39
Platelet count ( $10^9/l$ )	630.21 $\pm$ 58.64	714.43 $\pm$ 62.12*	769.56 $\pm$ 57.28*	665.2 $\pm$ 46.34	654.38 $\pm$ 51.16
Reticulocytes (%)	1.11 $\pm$ 0.41	1.12 $\pm$ 0.83	1.13 $\pm$ 0.67	1.21 $\pm$ 0.88	1.15 $\pm$ 0.59

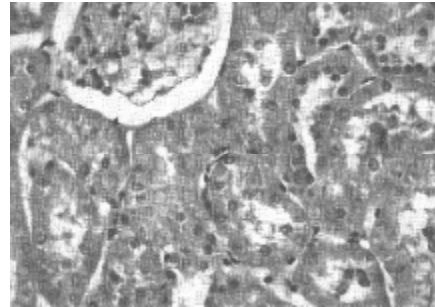
\* Significant difference compared with control group.

**Table (4) :** Prothrombin activity and fibrinogen concentration of blood from control rats and rats fed BHT or GA.(mean $\pm$ SD).

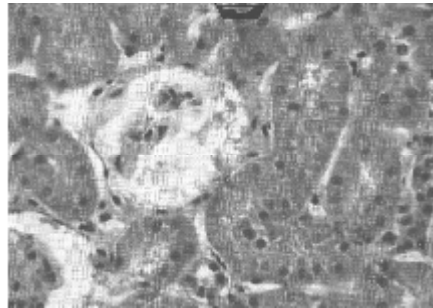
parameters	Control	BHT (0.3%)	BHT (0.6%)	GA (0.3%)	GA (0.6%)
Prothrombin activity (%)	100.00 $\pm$ 2.15	99.52 $\pm$ 5.21	91.56 $\pm$ 3.86	101.28 $\pm$ 4.76	92.67 $\pm$ 2.28
Fibrinogen (mg/dl)	236.25 $\pm$ 15.36	240.34 $\pm$ 10.45	238.46 $\pm$ 14.22	239.17 $\pm$ 16.12	231.74 $\pm$ 15.89



**Fig. (1):** Normal appearance of renal glomeruli, convoluted proximal, convoluted distal and collecting tubules (control).



**Fig. (2):** Cloudy swelling and hydropic degeneration of the lining epithelium of proximal and distal convoluted tubules with early necrotic changes in the lining tubular epithelium (0.3% BHT)



**Fig. (3):** Prominent necrosis of tubular epithelium, there is evident necrosis of glomerular epithelium with protein deposits in Bowman's space. (0.6% BHT).

### **Discussion**

This study was conducted to clarify the toxicity profile of BHT or GA when given as a dietary admixture to rats for three weeks. The present results indicated that several toxic effects were noticed in case of the groups fed BHT. These effects included decreased body weight gain, and decreased serum total protein and serum albumin. The reduction in serum total protein and serum albumin may be due to proteinuria and suggests some deterioration in the renal function. This finding confirms the work of Nakagawa and Tayama (1988) who showed that feeding rats BHT resulted in proteinuria and reduced accumulation of p- aminohippuric acid in renal slices reflecting some renal damage. This was further confirmed by the histopathological examination in the present study which indicated that at 0.3% BHT early necrotic changes were noticed, while 0.6% BHT caused prominent necrosis of tubular epithelium and glomerular epithelium with protein deposits in Bowman's space. Serum creatinine, urea and uric acid were normal for all groups.

From the present results, other toxic effects of BHT included reduced hemoglobin, hematocrit and red blood cell count in the group fed 0.6% BHT. There was no increase in reticulocyte count indicating that these anemic changes are not hemolytic in origin. No hemorrhage was noticed in all groups tested, and also no change in prothrombin activity or fibrinogen concentration. BHT was indicated to cause hemorrhages in rats when given at a level of 1.2% for three weeks. This was explained to be due to hypoprothrombinemia resulting from inhibition of phyloquinone epoxide reductase in the liver. (Madhavi et al., 1996). An earlier study, in which rats received a diet containing 2% BHT for up to 98 weeks, confirmed the occurrence of BHT related hemorrhagic death (Cottrell et al., 1994). Takhashi and Hiraga (1984) suggested that BHT might inhibit absorption of vitamin K in the intestine. This suggestion is supported by the work of Faine et al., (2006), when rats were given BHT (i.p) at a dose of 1500 mg/ kg twice a week for 30 days and no hemorrhages were recorded.

The present study demonstrated also that there was a significant increase in platelet count in the groups given BHT at either concentrations. Persistent increase in platelet count after BHT intake was noticed by Cottrell et al. (1994). Takahashi and Hiraga (1984) reported no significant difference in platelet count between control rats and animals fed a diet containing 1.2% BHT for seven days, although they reported a treatment related decrease in platelet distribution width. Cottrell et al. (1994) indicated that chemically induced platelet dysfunction can cause increased platelet production by megakaryocytes and suggested that when BHT is given to rats some stabilization of platelet membrane or inhibition of platelet shape change required for platelet aggregation may occur leading to increased platelet production. Accordingly, the increase of numbers of circulating platelets in the present work may be an adaptive response to a BHT-related suppression of normal platelet function.

In this work, the only toxic effect after feeding GA to rats was a

decrease of white blood cell count in the 0.6% group. Niho et al., (2001) investigated the subchronic toxicity of GA by feeding rats diet containing 0.0, 0.2, 0.6, 1.7 and 5% GA for 13 weeks. Toxic effect following administration of 0.6% or more included reduction in hemoglobin concentration, hematocrit and red blood cell count and increase in reticulocytes. They suggested 0.2% to be a no-observed-adverse-effect level (NOAEL) in rats. The anemic changes they noticed are in agreement with the study of Chung et al., (1998) who reported that tannins and their hydrolyzates could interfere with hematopoiesis in addition to reducing the bioavailability of iron and vitamin B12. It is to be noted that the anemic changes in the work of Niho et al., (2001) was very mild, since feeding rats 0.6% GA for 13 weeks resulted in a change of hemoglobin concentration from 15.5 g/dl for control rats to 15.0 g/dl for the GA treated group. The decrease in the white blood cell count in the present work further confirms the work of Marzo et al., (1990) who indicated that white blood cell count was reduced when tannins

were fed to growing chickens.

The results of the present investigation recommend avoiding using BHT as a food additive and suggest using gallic acid or gallates in food industry. Gallates are components of tannins we used to ingest in our food. It is estimated that people in the United States ingest each day one gram of tannins (Sanyal et al., 1997). Tannic acid is considered generally recognized as safe (GRAS) food additive, which may be present in foods up to 400 ppm (Chen and Chang 2000). Brune et al., (1989) indicated that tannic acid could be hydrolyzed in the acidic pH of the stomach releasing the ten potentially reactive gallic acid residues. The present results suggest the (NOAEL) of GA in rats to be 0.3%. This can be translated into 178mg/ kg/ day.

Unlike GA, BHT can accumulate in the adipose tissue and this accumulation was shown to be greater in humans than in rats (Conacher et l., 1986). Bioconcentration factor of BHT in man was found to be 45 times higher than that in rats. (Geyer, 1986). In ad-

dition it is well known that BHT has been utilized in experimental animals to induce pulmonary inflammation (Kisley et al., 2002), renal and hepatic damage (Farak et al., 2003) and cardiac oxidative stress (Faine et al., 2006).

### References

**Bravo L. (1998)** : Polyphenols: Chemistry, dietary sources, metabolism, and nutritional significance. *Nutrition Reviews*, 56: 317-333.

**Brune L. and Rossander L. (1989)** : Iron absorption and phenolic compounds: Importance of different phenolic structure. *European Journal of Clinical Nutrition*, 43: 547- 55.

**Carmona A. (1996)** : Tannins: Thermostable pigments which complex dietary proteins and inhibit digestive enzymes. *Archives of Latinoamerican Nutrition*, 44: 315- 35S.

**Chen S. and Chung K. (2000)**: Mutagenicity and antimutagenicity studies of tannic acid and its related compounds. *Food and Chemical Toxicology*, 38:1-5.



- Chung K., Wong T., Wei C., Huang Y. and Lin Y. (1998) :** Tannins and human health. *Critical Reviews of Food Science and Nutrition*. 38: 421- 464.
- Conacher H., Iverson F., Lau P. and page B. (1986) :** Levels of BHA and BHT in human and animal adipose tissues. *Interspecies Extrapolation. Food and Chemical Toxicology.*, 24 : 1159-1162.
- Cottrell S., Andrews C., Clayton D., Wild B. and Powell C. (1994) :** Haematological and platelet effects of butylated hydroxytoluene (BHT, E321); *Comp Haematol Int*, 4: 102- 107.
- Dacie J and Lewis S. (1975) :** *Practical Hematology*, Livingstone. London.
- Faine L, Rodrigues H., Galhardi C., Ebaid G., Diniz Y., Fernandes A. and Novelli E. (2006) :** Butylated hydroxytoluene (BHT)-induced oxidative stress: Effects on serum lipids and cardiac energy metabolism in rats. *Experimental and Toxicological Pathology*. 57: 221- 226.
- Farag R., El- Baroty G. and Basuny A. (2003) :** Safty evaluation of olive phenolic compounds as natural antioxidants. *Int J Food Sci Nutr.*, 54: 159- 174.
- Fritsche K. and Mc-Guire S. (1997) :** The use of dietary synthetic antioxidants at recommended levels does not alter rat immune cell eicosanoid production or hepatic vitamin E concentration. *Nutrition Research*, 17: 1311- 1319.
- Geyer H., Sch eunert I. and Korte F. (1989) :** Bioconcentration potential of organic environmental chemicals in humans. *Regul Toxicol Phrmacol*, 6(4): 313-347.
- Kisley L., Burrett B., Bwyer L., Bauer A., Thompson D. and Malkinson A. (2002) :** Celecoxib reduces pulmonary inflamtion but not lung tumorigenesis in mice. *Carcinogenesis.*, 23: 1653- 1660.
- Kroes B., Van den Berg A., Van ufford H., Van Dijk H. and Labadie R. (1992) :** Anti-inflammatory activity of gallic acid. *Planta Media*, 58: 499- 504.

- Lemerier J., Meier B., Comez J. and Thompson J. (2004)** : Inhibition of glutathione-S-transferase P1-1 in mouse lung epithelial cells by the tumor promoter BHT-quinone methide. *Chem Res Toxicol*, 17(12): 1675-1683.
- Madhavi D., Deshpande S. and Salunkhe D. (1996)** : Butylated hydroxyanisole and butylated hydroxytoluene. *Food Antioxidants*. Marcel Dekker, New York.
- Marzo. F., Tosar, A. and Santidrian, S. (1990)** : Effect of tannic acid on the immune response of growing chickens. *J Anim Sci.*, 68: 3306.
- Meyer O., Kristiansen E. and Wurtzen G. (1984)** : Effects of dietary protein and butylated hydroxytoluene on the kidney of rats. *Lab Anim.*, 23 (2): 175- 179.
- Nakagawa W. and Tayama K. (1988)** : Nephrotoxicity of butylated hydroxytoluene in phenobarbital-pretreated male rats. *Arch Toxicol.*, 61: 359- 365.
- Niho N., Shibutani M., Tamura T., Toyoda K, Uneyama C., Takahashi N. and Hirose M. (2001)** : Subchronic toxicity study of gallic acid by oral administration in F344 rats. *Food and Chemical Toxicology*, 39: 1063- 1070.
- Ow Y. and Stupans L. (2003)** : Gallic acid and gallic acid derivatives: Effects on drug metabolizing enzymes. *Current Drug Metabolism*, 4(3): 241- 248.
- Prasad L., Khan T. Jahangir T. and sultana S. (2006)** : Effect of gallic acid on renal biochemical alterations in male Wistar rats induced by ferric nitriloacetic acid. *Human and Experimental Toxicology*, 25 (9): 523- 529.
- Raina K. Rajam anickam S., Deep G., Singh M., Agarwal R. and Agarwal C. (2008)** : Chemopreventive effects of oral gallic acid feeding on tumor growth and progression. *Mol Cancer Ther.*, 7 (5): 1228- 1267.
- Sanyal R., Darroudi F., Parzefall W., Nagao M. and Knasmuller S. (1997)** : Inhibition of the genotoxic effects of heterocyclic amines in human derived hepato-

ma cells by dietary bioantimutagens. *Mutagenesis*, 12 : 297-203.

**Serrano A., Palacios C., Roy G., Cespon C., Villar M., Nocito M. and Gonzalez-Prorque P. (1998)** : Derivatives of gallic acid induce apoptosis in tumoral cell lines and inhibit lymphocyte proliferation. *Archives of Biochemistry and Biophysics*, 350: 49- 54.

**Stapleton P., Gettert J. and Taylor P. (2006)** : Epicatechin gallate, a component of green tea, reduces halotolerance in staphylo-

coccus aureus. *Int J Food Microbiol.*, 11(3): 276- 279.

**Takahashi O. and Hiraga K. (1984)** : Effect of dietary butylated hydroxytoluene on functional and biochemical properties of platelets and plasma preceding the occurrence of hemorrhage in rats. *Food and Chemical Toxicology*, 22: 97-103.

**Ware A., Sterling R. and Stragnell R. (1964)** : Anticoagulant therapy : Appraisal of its laboratory control. *Angiology*, 15 : 11.

REPRINT

# **BENHA MEDICAL JOURNAL**

**SOME TOXIC EFFECTS OF  
BUTYLATED HYDROXYTOLUENE  
AND GALLIC ACID**

**Eman A. Al-Shehri Ph.D  
and Ammenah M. Al-Suhaibani Ph.D**

**Published by  
Benha Faculty of Medicine**

*Volume 26 Number 3  
Sept. 2009*