

ROLE OF X RAY& BARIUM STUDIES IN REFRACTORY VOMITING

by:

Islam Nasr

Assistant lecturer of hepatology,
gastroenterology and infectious diseases

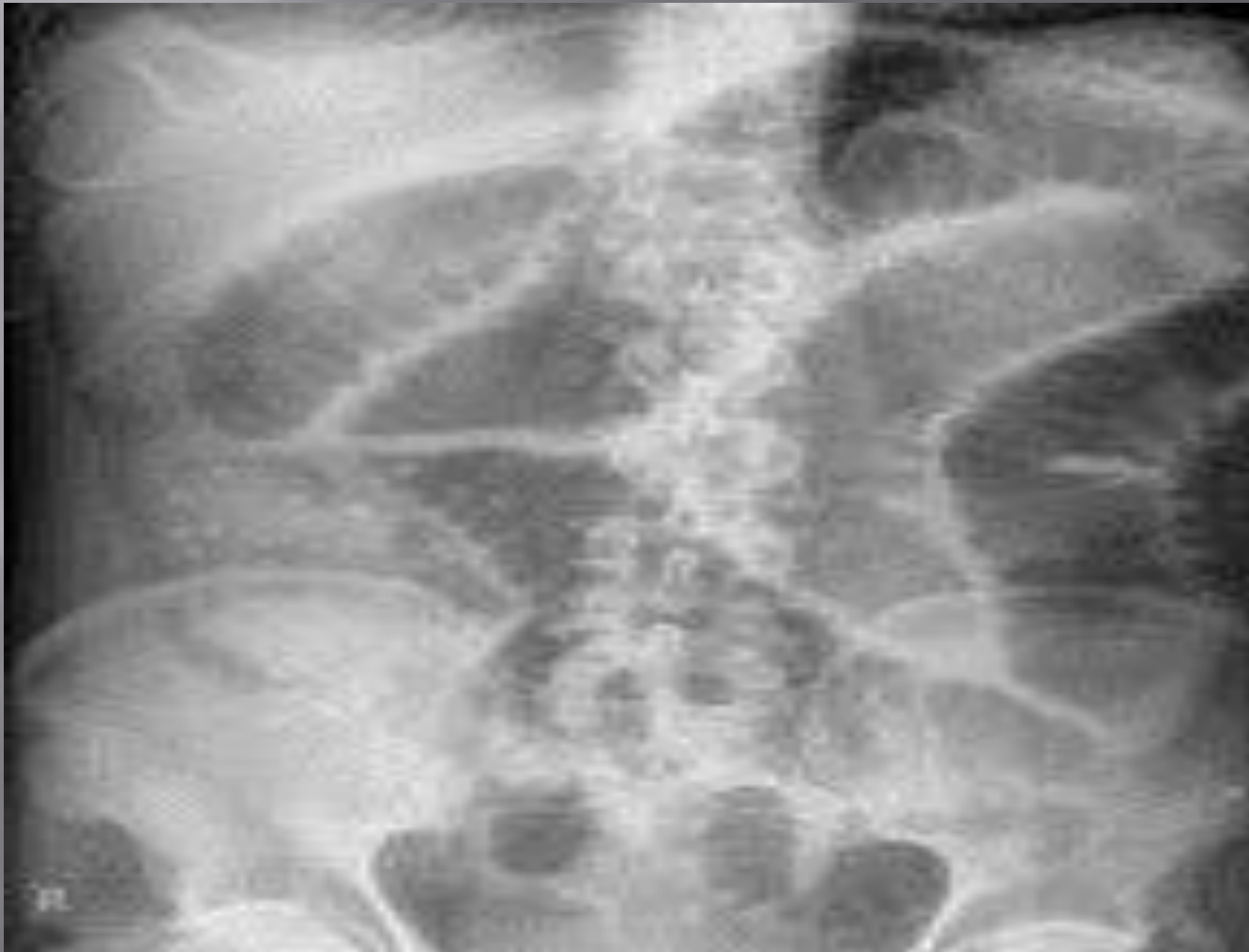1 xray

abdominal x-ray •

commonly used, but of limited value •

only helpful if the bowel is dilated and gas-filled •

cont



cont

In case of refractory vomiting: □

Supine and upright abdominal x ray should be performed if there is any concern about a intestinal obstruction,- although **false-negative** results occur in as many as **22%** of patients with a partial obstruction. □

So,, ▣

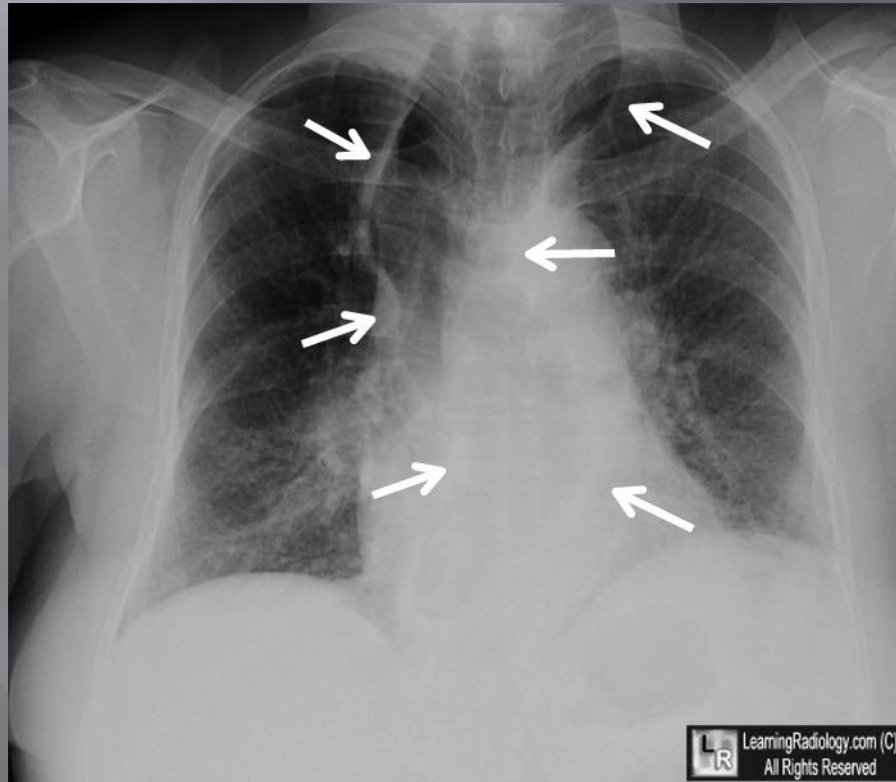
If results are negative but an obstruction is still suspected, further testing should be performed ▣

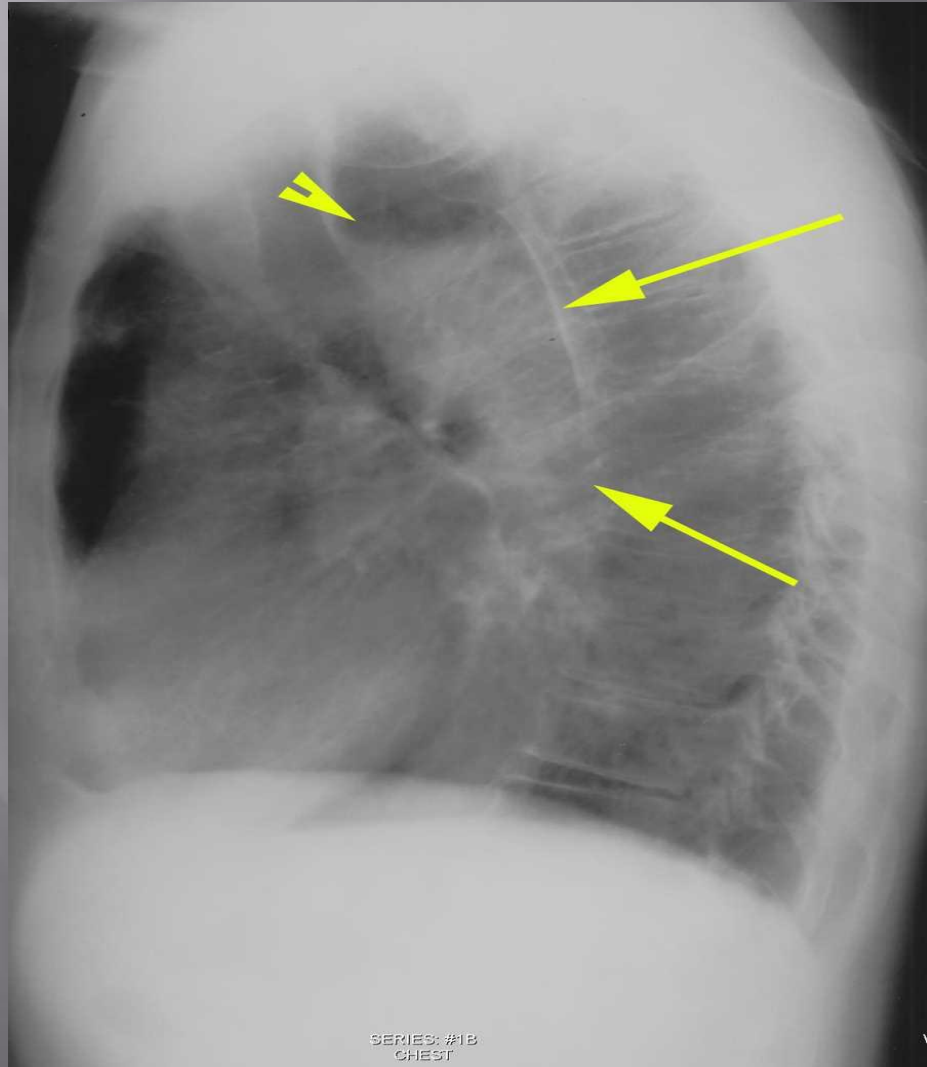
cont

so.,

What about chest x
ray???

What is DD??





SERIES: #1B
CHEST

v

Diagnosis is: □

achalsia □

Barium studies

What are barium X-rays? □

A barium X-ray is a radiographic (X-ray) □ examination of the gastrointestinal (GI) tract.

Barium X-rays (also called upper and lower GI series) are used to diagnose abnormalities of the GI tract, such as tumors, ulcers and other inflammatory conditions, polyps, hernias, and strictures.

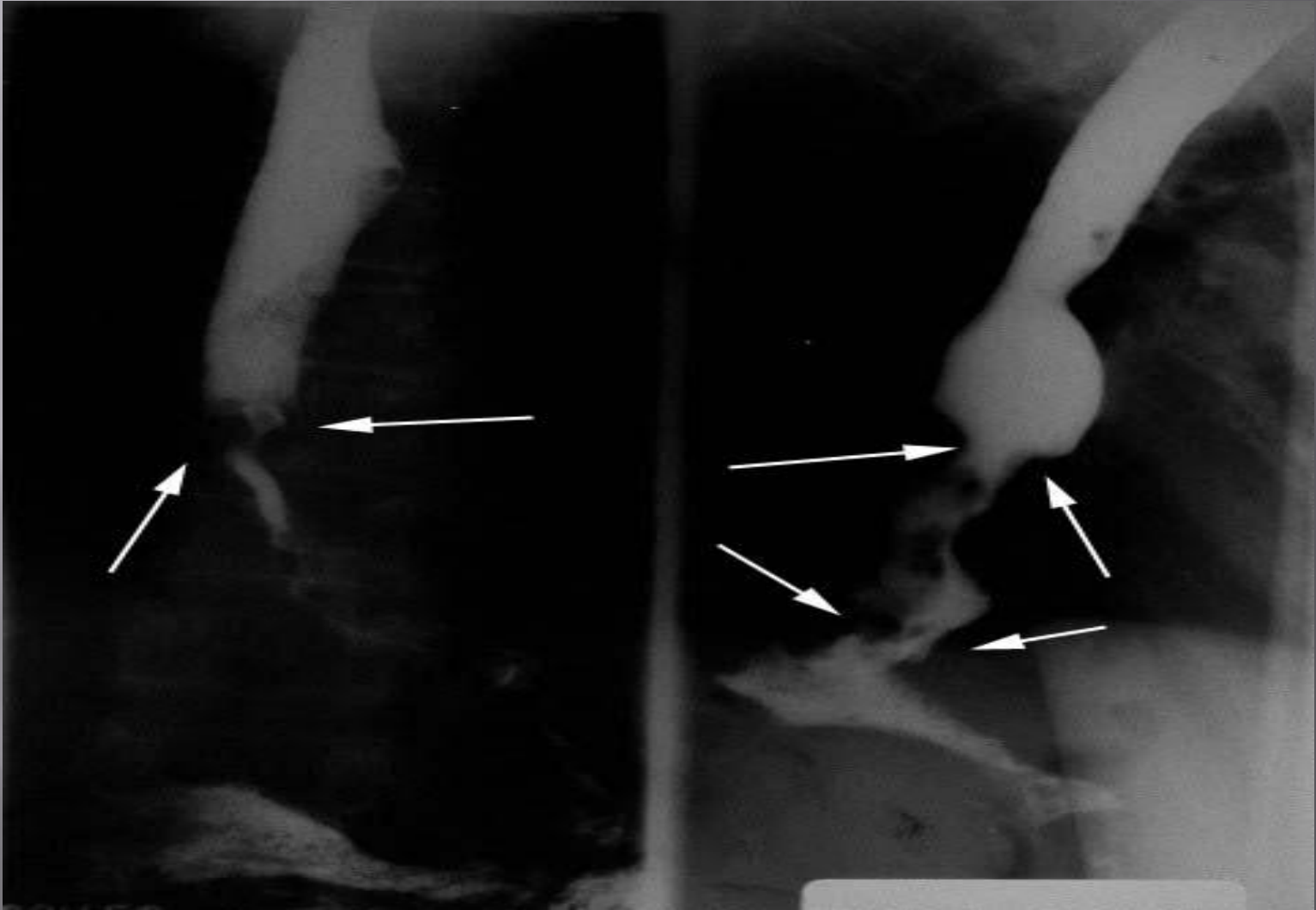
What are the findings could be detected by BARIUM study in such case???

1-achalasia

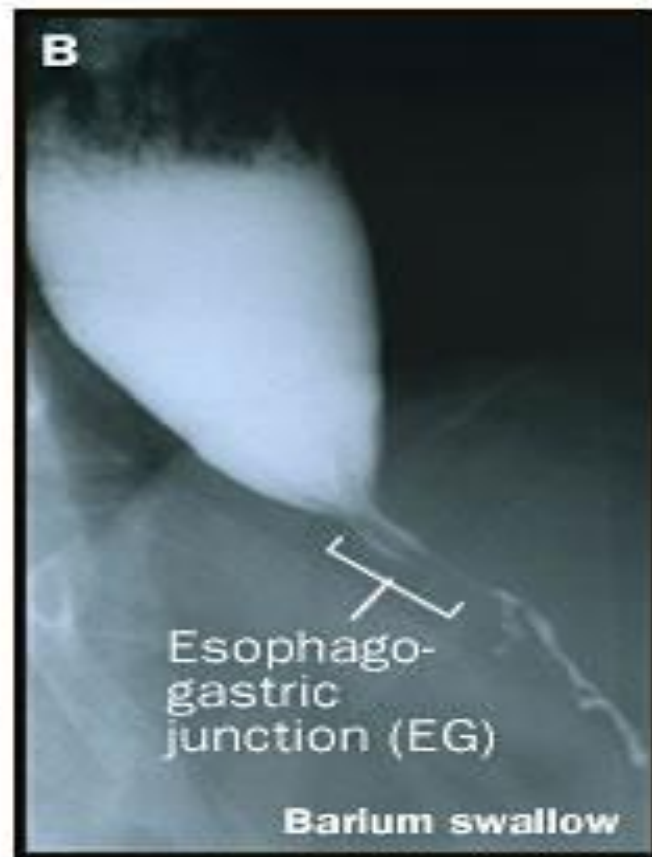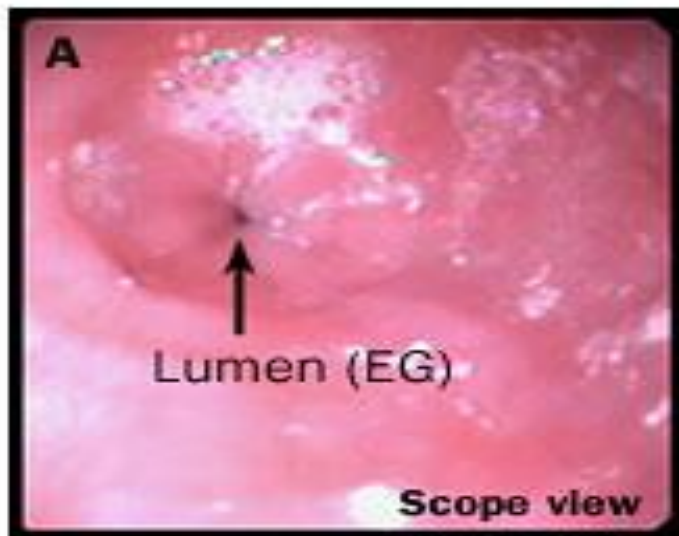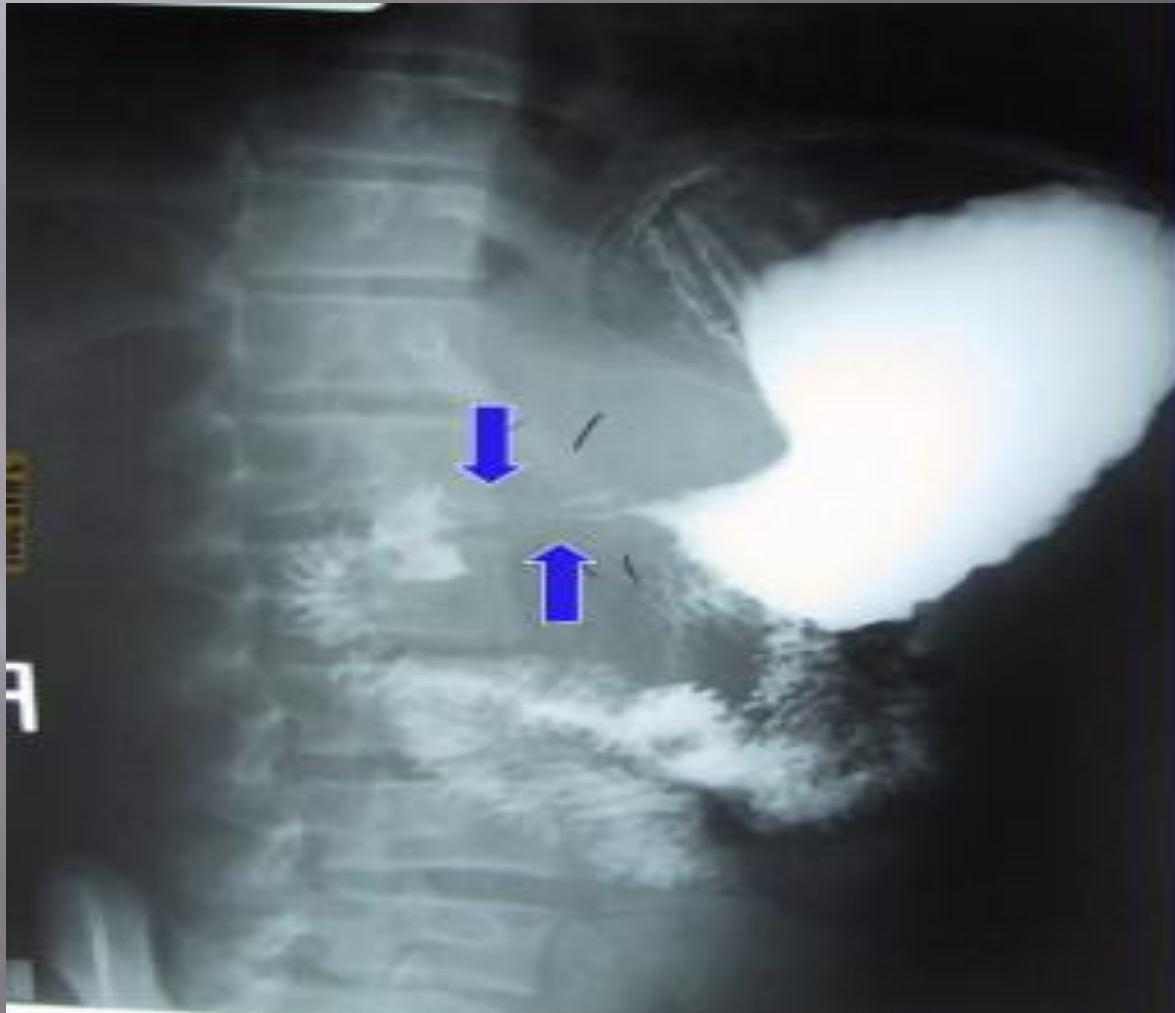


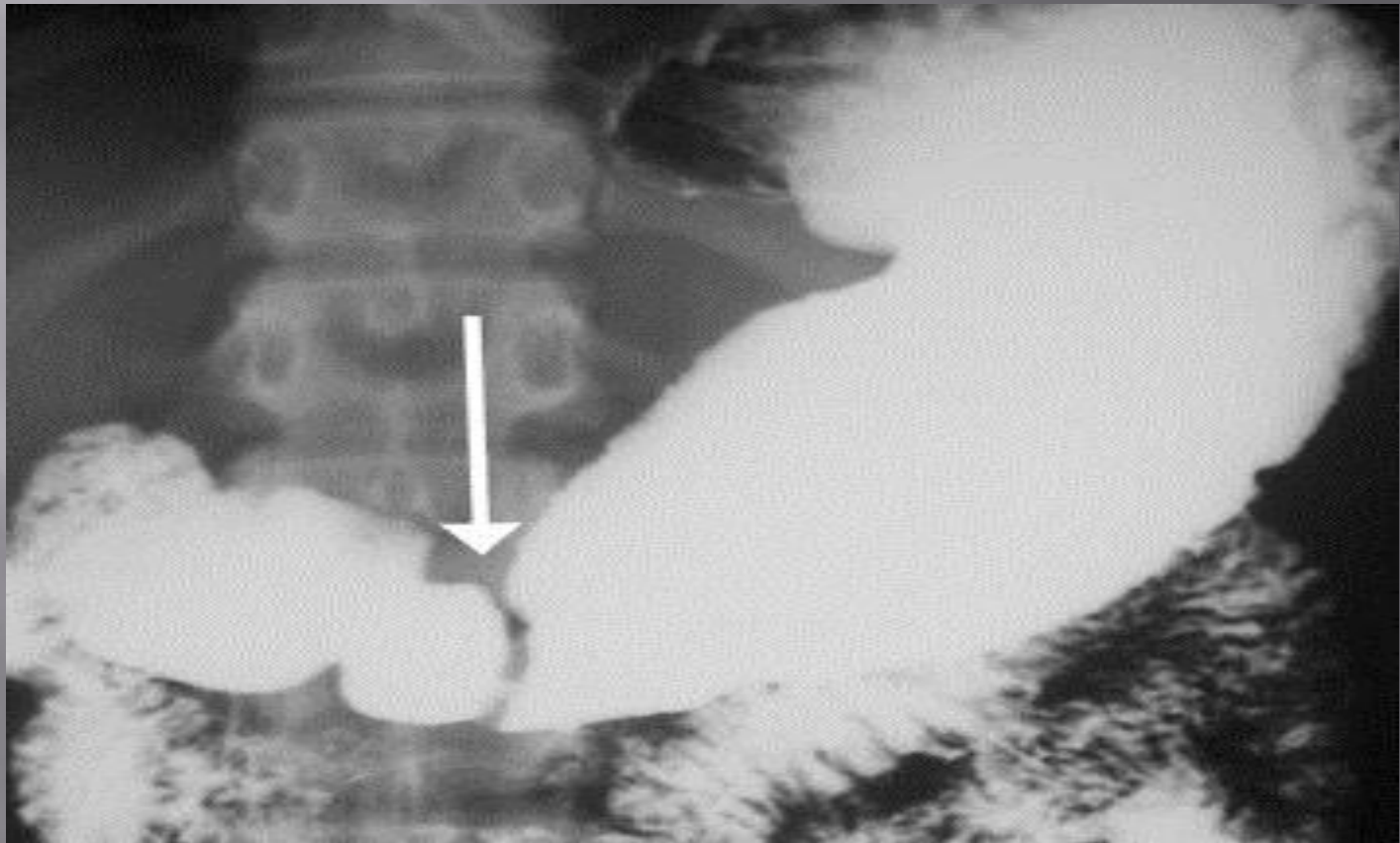
Figure 23. Endoscopic (A) and radiographic (B) findings in achalasia.

2-cancer



Gastric outlet obstruction





THANKS